

## A STUDY ON PLACENTAL MORPHOLOGY IN GESTATIONAL DIABETES

Katadi Venkata Sudha Madhuri<sup>1</sup>, Irrinki Vasundhara Jyothi<sup>2</sup>

<sup>1</sup>Assistant Professor, Department of Obstetrics and Gynaecology, Andhra Medical College, Visakhapatnam.

<sup>2</sup>Assistant Professor, Department of Obstetrics and Gynaecology, Andhra Medical College, Visakhapatnam.

### ABSTRACT

#### BACKGROUND

Gestational Diabetes Mellitus (GDM) refers to any degree of glucose intolerance with onset or first recognition during pregnancy. Maternal diabetes constitutes an unfavourable environment for embryonic and foetoplacental development. The histomorphological changes in the placenta are associated with increased perinatal morbidity, increased risk of diabetes in the offspring and the mother in the ensuing years of life. Present study aims to study the morphological changes in the placenta along with maternal and foetal outcomes in pregnancies complicated by GDM.

#### MATERIALS AND METHODS

A descriptive observational case-controlled study was conducted from January 2013 to November 2016 in King George Hospital, Visakhapatnam. Hundred and sixty four women diagnosed with GDM and hundred women with normal gestation were enrolled in the study. Foetal surveillance was done by Doppler ultrasound and kick count technique during the gestation. Foetal and maternal outcome was evaluated and compared to the outcome of normal gestation. Placental specimens from term gestations (38-42 weeks) diagnosed with GDM and normal full-term gestations were studied to assess the morphological parameters. Statistical analysis was done using descriptive statistical measures.

#### RESULTS

In the present study, 62.19% of the GDM cases terminated as normal gestations. Recurrent UTI was the most common complication (14.02%) during the antenatal period. 17.68% of the foetuses from GDM mothers presented with macrosomia, however, there were no cases of congenital anomalies or shoulder dystocia. Placental tissue from the GDM cases was larger, heavier and more cotyledonous as compared to placenta from normal subjects. The umbilical cord showed eccentric and central attachment in all the controls and most of the cases and 5.48% of the cases showed marginal attachment of the umbilical cord.

#### CONCLUSION

The study describes the various maternal, foetal and placental outcomes in pregnancies complicated by GDM. Recurrent UTI was the most common maternal complication during antenatal period while macrosomia was the most common foetal outcome. The morphological changes in the placenta were studied to understand the placental presentation in GDM patients. Thus, the study brings to light the possible pathophysiological areas of clinical research for disease modifying interventions.

#### KEYWORDS

Diabetes, Gestational, Placenta, Maternal-Foetal Exchange.

**HOW TO CITE THIS ARTICLE:** Madhuri KVS, Jyothi IV. A study on placental morphology in gestational diabetes. J. Evid. Based Med. Healthc. 2017; 4(2), 71-75. DOI: 10.18410/jebmh/2017/14

#### BACKGROUND

Diabetes mellitus is a chronic metabolic disorder, which occurs when the pancreas does not produce enough insulin or when the body cannot effectively utilise the insulin produced thereby leading to hyperglycaemia. According to the World Health Organization (WHO), diabetes has emerged as an epidemic affecting 246 million people across the world.<sup>1</sup> India has an estimated 62 million people with type 2 Diabetes Mellitus (DM); this number is expected to go up to 79.4 million by 2025.<sup>2</sup>

*Financial or Other, Competing Interest: None.  
Submission 27-11-2016, Peer Review 01-12-2016,  
Acceptance 12-12-2016, Published 05-01-2017.*

*Corresponding Author:*

*Dr. Katadi Venkata Sudha Madhuri,  
#104 Villa, Sardar Nest Kanithi Village,  
Gajuwaka, Visakhapatnam-530044.  
E-mail: kvsmadhuri1975.kk@gmail.com  
DOI: 10.18410/jebmh/2017/14*



DM in pregnant women maybe classified into clinical/pregestational diabetes (women previously diagnosed with type 1 or type 2 diabetes) and Gestational Diabetes (GDM) defined as any degree of glucose intolerance with commencement or first recognition during pregnancy.<sup>3</sup> GDM not only incites immediate maternal (preeclampsia, stillbirths, macrosomia and need for caesarean section) and neonatal consequences (hypoglycaemia, respiratory distress), but also intensifies the risk of impending type 2 diabetes in the baby as well as the mother by seven times.<sup>4</sup> A recent meta-analysis showed that women with GDM have a markedly heightened risk of developing type 2 diabetes (relative risk 7.43, 95% confidence interval 4.79-11.51).<sup>5</sup> GDM represents nearly 90% of all pregnancies complicated by DM<sup>3</sup> and it affects an estimated 5 million women in India.<sup>6</sup>

The placenta is a membranous vascular complex organ with a short lifespan that develops in female eutherian mammals during pregnancy. It facilitates nutrient uptake,

waste elimination and gaseous exchange between the maternal and foetal circulations.<sup>7</sup> The placenta must integrate signals from the foetus and the mother in an effort to match foetal demand with maternal nutrient supply. The metabolic and endocrine activities of placenta are not clearly understood till date.<sup>8,9</sup> DM during pregnancy produces variety of placental abnormalities such as significant thickening of basal membranes of trophoblast, separation of basal membranes in basal capillaries,<sup>10</sup> distension and proliferation of endothelial cells, disarrangements of perivascular space and decrease of vascular surface of terminal villi. The nature and extent of these changes depend on a number of factors particularly the quality of glycaemic control achieved during the critical periods in placental development.<sup>8</sup> These pathological changes in the placentae of diabetic mothers are in turn important risk factors contributing to foetal anoxia and foetal compromise in pregnancy.<sup>11</sup> Furthermore, abnormal maternal glycaemic levels may alter the placental morphometric characteristics related to maternal-foetal exchanges.<sup>12</sup> Alterations in placental function due to uncontrolled diabetes result in disturbances in growth and development, macrosomia, congenital malformations and intrauterine growth retardation.<sup>12,13</sup>

This study intends to understand the maternal, foetal outcomes and the possible gross macroscopic changes in the structure of placenta in pregnancies complicated by GDM. Additionally, the study compares the outcomes of GDM gestations with that of normal full-term gestations.

## MATERIALS AND METHODS

This descriptive, observational, case-controlled study was carried out in the Department of Obstetrics and Gynaecology (OBG), King George Hospital in Visakhapatnam from January 2013 to November 2016. Hundred and sixty-four pregnant women diagnosed with GDM (cases) and hundred normal pregnant women with no added complications (controls) were enrolled as study subjects. All pregnant women attending the OBG Outpatient Department with GDM diagnosed by glucose tolerance test were included in the study. Patients with preexisting type I/II diabetes, GDM with hypertension, associations with any toxemia of pregnancy, associations with any pre-existing chronic diseases or metabolic disorders were excluded from the study. A written informed consent was obtained from all the mothers included in our study. Personnel information such as age, parity, previous obstetric history, any family history of diabetes and hypertension, any chronic illness in the past, present complications, medications, diet, blood group of all the subjects was noted. All subjects included in the present study belonged to the same race and ethnicity.

Based upon blood glucose values, patients with GDM were either hospitalised or managed as outpatients with diet control. Blood glucose profile (6 levels) was done as follows-fasting, 2 hours post breakfast, pre-lunch, 2 hours post lunch, pre-dinner and 2 hours post dinner. The dose of insulin was adjusted until fasting and 2 hrs. postprandial. Blood glucose levels were 70-100 and less than 140 mg/dL

respectively according to American Diabetes Association criteria.<sup>14</sup>

After adjusting insulin dosage, patients were discharged with instructions to be followed regularly at antenatal clinic with glucose home monitoring (2 levels) and to report immediately in case any complication (PIH, preterm labour, premature rupture of membranes or decrease foetal movement) should occur. Ultrasonography was done early in gestation for foetal anomalies and was repeated if indicated. At each antenatal visit, glucose home monitoring (fasting and 2 hours postprandial) record was checked, maternal and foetal wellbeing were assessed and if there was any complication, the patient was readmitted and managed accordingly. Doppler ultrasound and kick-count technique was used for foetal surveillance.

Decision about time and mode of delivery was made at 36 weeks of gestation. Patients with controlled GDM and no added complications were allowed to go beyond 38 completed weeks. However, none of them were allowed to go beyond 40 weeks of pregnancy. Induction of labour was carried out for indications such as poor glycaemic control, pre-eclampsia and gestational age of 40 completed weeks. Elective caesarean section was reserved for those GDM cases presenting with foetal macrosomia or presence of more than one risk factor. During labour and prior to elective caesarean section, euglycaemia was achieved by administering intravenous insulin via an infusion pump together with intravenous dextrose at a rate of 10 g/h using 10% solution. Maternal plasma glucose levels were monitored hourly and insulin dose adjusted to maintain the blood glucose concentration between 70-110 mg/dL.<sup>15</sup> All newborns were assessed by the paediatrician immediately after delivery and the data was entered in a structured proforma.

The placenta from the subjects was obtained were either by vaginal delivery or by caesarean section. After delivery of the placental tissue, the shape was noted. The diameter of the placenta was measured in centimetres (cms) using a measuring tape. The length of the umbilical cord sent was measured in centimetres (cms) and observed for its position of insertion, number of vessels, knots or any other changes. The cord was cut 5 cms away from its site of insertion. Next, the placental membranes were examined for transparency, colour change, additional lobes and surface irregularity. The membrane was trimmed by rolling technique and the placental specimens were weighed on weighing machine graduated in grams (g) after rinsing with running tap water and drying with blotting paper. Gross examination of the maternal surface for the colour, number of cotyledons, infarct or any other changes was noted. The foetal surface was looked for vascular pattern and other changes.

## Statistical Analysis

Chi-square test was applied to categorical data such as maternal and foetal outcomes. Numerical data, i.e. foetal weight, diameter, vascular pattern of the placenta and site of attachment of the umbilical cord were presented as mean scores and Student's t-test was applied to compare the

mean between two groups (cases and control). Entire data was calculated on 95% CI. A p value <0.05 was considered significant.

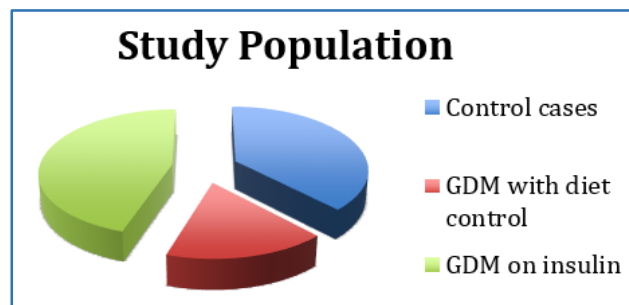
**RESULTS**

A total of 264 subjects were included in the study (Figure 1), 100 were nondiabetic mothers (controls) and 164 were GDM mothers (cases). Mean age of the study population was 29.3 years with the eldest subject being 36 years and the youngest being 24 years of age. Out of the 164 GDM cases included in the present study 119 (72.56%) of the cases were on treatment with insulin and 45 (27.43%) of them were on diet control.

Evaluation of the antenatal progress of the cases has been tabulated in Table 1. 62.19% of GDM cases had absolutely no complications and terminated as normal vaginal deliveries. However, 37.81% of the GDM cases showed one or the other complication as stated in Table 1. Recurrent UTI was the most common complication seen in 14.02% of the cases. 94% controls progressed to terminate as normal full-term vaginal deliveries. Foetal outcome of the cases has been tabulated in Table 2. 69.51% of the neonates born to GDM mothers were normal. The most common foetal complication was macrosomia (17.68%).

In this study, placental weight and diameter was significantly higher in GDM group when compared to the control group (Table 3). The mean weight of placenta in control group was 502 g and in GDM mothers it was 614 g, the difference between them was 112 g (p value <0.5).<sup>16</sup> Figure 2 depicts bar diagram showing frequency distribution of placental weight (g) among GDM and control subjects. Offsprings of GDM mothers were significantly heavier than babies from normal mothers (mean difference 457 mg). The diameter of the placenta of GDM mothers was comparatively greater than control cases (mean difference 9.15 cm).

Statistical analysis of macroscopic examination of number of cotyledons in placentae from control mothers had a mean of 17.12 and in diabetic mothers, it was 26.52 with the difference of 9.4, which was statistically significant (p-value<0.05).<sup>16</sup>



**Figure 1. Split Up of the Cases and Controls Included in the Study**

Maternal Outcome	Cases (n=164)	Percentage
Gestation with no complications	102	62.19%
Pre-term Labour	10	6.09%
Polyhydramnios	11	6.70%
Pregnancy-induced hypertension	9	5.48%
Recurrent UTI	23	14.02%
Premature rupture of membranes	6	3.65%
Miscarriage	3	1.82%

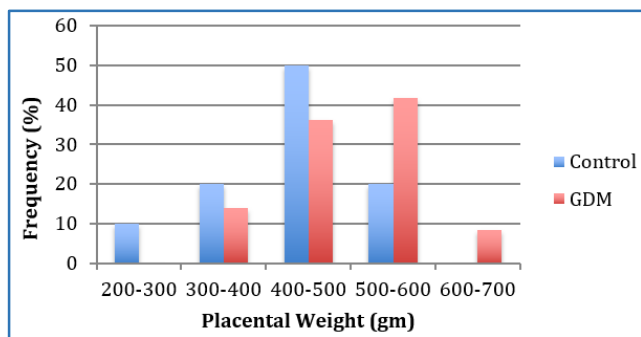
**Table 1. Maternal Outcome of GDM Cases**

Foetal outcome	Cases (n=164)	Percentage
Normal	114	69.51%
Macrosomia	29	17.68%
Jaundice	11	6.70%
Hypoglycaemia	7	4.26%
Foetal demise	3	1.82%
Congenital anomaly	Nil	Nil
Shoulder dystocia	Nil	Nil

**Table 2. Foetal Outcome of GDM Cases**

Gross Observations	Control (n=100)	GDM on Diet Control (n=45)	GDM on Insulin Therapy (n=119)
Placental shape	Round/Oval	Round/Oval/Irregular	Round/Oval/Irregular
Mean placental weight	502	618	610
Placental length (cm)	454.7	601	596.5
Mean foetal weight (kg)	2.595	3.04	3.065
<b>Vascular Pattern</b>			
(a) Dispersal	71	38	102
(b) Magistral	29	7	17
<b>Site of Umbilical Cord Attachment</b>			
Eccentric and central	100	45	110
Marginal	-	-	9

**Table 3. Gross Observations of Placenta from GDM Patients and Controls**



**Figure 2. Diagram Showing Frequency Distribution (%) of Placental Weight (g) in GDM/Controls**

## DISCUSSION

In the present study, the mean age of presentation was 29.3 with 63.46% of the cases being >30 years of age, thus in co-ordination with a number of studies, which show increasing age tends to increase the chances of GDM.<sup>17,18</sup> A study by Farooq et al<sup>19</sup> reported 64% of the GDM cases required insulin for glycaemic normalisation similar to the present study in which 61% cases required insulin therapy.

GDM is associated with neonatal hypoglycaemia, respiratory distress, macrosomia, large babies, caesarean sections, birth injuries and the consequent sequelae of metabolic syndrome in childhood/adolescence.<sup>9</sup> However, there is no documented evidence of increased perinatal mortality associated with GDM pregnancies. Present study recorded no instances of congenital anomalies or shoulder dystocia in the foetus. However, the study by Farooq et al<sup>19</sup> showed 2% occurrence of congenital anomalies in GDM cases. The cases of macrosomia (17.68%) maybe due to the reactionary hyperglycaemia triggered by the foetal hyperinsulinism and the consequent hypoglycaemic state in the foetus in the third trimester.<sup>9</sup> Good maternal glycaemic control during pregnancy and normal maternal glucose levels at the time of delivery decrease the risk of neonatal hypoglycaemia as in the present study (4.26%).

Human placenta is haemochorial; the placental membrane consists of the syncytium with its basement membrane, the reticular network and the foetal endothelium with its basement membrane.<sup>9</sup> The foetus, placenta and mother form a triangle of dynamic equilibrium and any disturbance in one will affect the others.<sup>20</sup> In women with GDM, the carbohydrate metabolism is scrunched and possibly protein and lipid metabolisms are also deranged.<sup>21</sup> These biochemical changes occurring during pregnancy will reflect on the foetus and placental structure.

Diabetes mellitus is a chronic metabolic disorder defined by hyperglycaemia. In the long run, it can cause severe catatonia of the cardiovascular, renal and central nervous system.<sup>22</sup> Diabetes mellitus during pregnancy produces changes in almost all layers of placenta like syncytial knot formation, increased thickness of vasculosyncytial membrane, villous immaturity, villous fibrinoid necrosis, trophoblastic hyperplasia<sup>23,24,25</sup> and predisposes to complications both in mother and the offspring.<sup>26,27</sup> Present study showed that the placenta of GDM mothers was heavier and larger in size irrespective of the age and parity of the

mothers. Studies by Khaskhelli LB et al,<sup>28</sup> Kucuk M et al<sup>29</sup> and Jauniaux et al<sup>30</sup> also showed significant increase in the weight and diameter of placental tissue of GDM mothers comparable with the present study. This increase in the placental weight and diameter is proportional to the lack of maturation of chorial villositities along with increase in diameters of villous lumen.<sup>31,32,33</sup> However, a study by Verma et al<sup>34</sup> revealed no gross difference in the weight of placenta from GDM mothers as compared to controls. This lack of uniformity of the results may be explained by differences in glycaemic control in individual patients, improvements in antenatal care and differing methodologies.

GDM is associated with neonatal hypoglycaemia, respiratory distress, macrosomia, large babies, caesarean sections, birth injuries and the consequent sequelae of metabolic syndrome in childhood/adolescence.<sup>9,35</sup> However, there is no documented evidence of increased perinatal mortality associated with GDM pregnancies. In the present study, almost all GDM mothers gave birth to large for date babies as compared to nondiabetic mothers of the control group. The pathophysiology behind weight gain of the foetus during the period of gestation in a GDM mother can be explained by reactionary hyperglycaemia triggered by the foetal hyperinsulinism and the consequent hypoglycaemic state in the foetus.<sup>9</sup>

## CONCLUSION

Present study documents the maternal and foetal outcomes along with various gross macroscopic changes seen in the placenta of mothers with GDM in comparison with normal gestation, thereby acknowledging the devoir to bring about social awareness and train manpower towards the diagnosis and management of GDM. The study also emphasises the need for further clinical research to improve maternal and foetal health by interrupting the placental pathology in mothers with GDM.

## REFERENCES

- [1] Divakar H, Manyonda I. Battling with rising prevalence of gestational diabetes mellitus: screening and diagnosis. *International Journal of Infertility and Fetal Medicine* 2011;2(3):96-100.
- [2] Anjana RM, Pradeepa R, Deepa M, et al. Prevalence of diabetes and prediabetes (impaired fasting glucose and/or impaired glucose tolerance) in urban and rural India: phase I results of the Indian Council of Medical Research-India DIABetes (ICMR-INDIAB) study. *Diabetologia* 2011;54(12):3022-3027.
- [3] American Diabetes Association. Diagnosis and classification of diabetes mellitus *Diabetes Care* 2009;34(Suppl 1):S62-67.
- [4] Kayal A, Anjana RM, Mohan V. Gestational diabetes-an update from India. *Diabetes Voice* 2013;58(2):30-34.
- [5] Bellamy L, Casas JP, Hingorani AD, et al. Type 2 diabetes mellitus after gestational diabetes: a

- systematic review and meta-analysis. *Lancet* 2009;373(9677):1773-1779.
- [6] International Diabetes Federation. Policy briefing. Diabetes in pregnancy: protecting maternal health. Brussels: IDF 2011. <http://www.idf.org/diabetes-pregnancy-protecting-maternal-health>.
- [7] Blackburn S. Prenatal period and placental physiology. *Maternal, fetal & neonatal physiology*. 4<sup>th</sup> edn. Maryland Heights: Saunders 2013;79-85.
- [8] Desoye G, Shafir E. The human placenta in diabetic pregnancy. *Diabetes Rev* 1996;4:70-89.
- [9] Calderon IM, Damasceno DC, Amorin RL, et al. Morphometric study of placental villi and vessels in women with mild hyperglycemia or gestational or overt diabetes. *Diabetes Res Clin Pract* 2007;78(1):65-71.
- [10] Adler AI, Stratton IM, Neil HA. Association of systolic blood pressure with macrovascular and microvascular complications of type 2 diabetes (UKPDS 36): prospective observational study. *BMJ* 2000;321(7258):412-419.
- [11] Hanson U, Persson B. Outcomes of pregnancies complicated by type 1 insulin-dependent diabetes in Sweden: acute pregnancy complications, neonatal mortality and morbidity. *Am J Perinatol* 1993;10(4):330-333.
- [12] Evers IM, Nikkels PG, Sikkema JM, et al. Placental pathology in women with type 1 diabetes and in a control group with normal and large-for-gestational-age infants. *Placenta* 2003;24(8-9):819-825.
- [13] Langer O, Yogev Y, Most O, et al. Gestational diabetes: the consequences of not treating. *Am J Obstet Gynecol* 2005;192(4):989-997.
- [14] American Diabetes Association. Preconception care of women with diabetes. *Diabetes Care* 2003;26(Suppl 1):S91-93.
- [15] Gillmer MDG, Hurley PA. Diabetes and endocrine disorders in pregnancy. In: Edmonds DK, ed. *Dewhurst's textbook of obstetrics and gynaecology for postgraduates*. 6<sup>th</sup> edn. Oxford: Blackwell Science 1999:197-209.
- [16] Stangroom J. *Social Science Statistics*, 2015. <http://www.socscistatistics.com/pvalues>.
- [17] Khan A, Jaffarey SN. Screening for gestational diabetes. *Medical Channel* 1997;3:8-12.
- [18] Randhawa MS, Moin S, Shoaib F. Diabetes mellitus during pregnancy: a study of fifty cases. *Pakistan J Med Sci* 2003;19:277-282.
- [19] Farooq MU, Ayaz A, Ali Bahoo L, et al. Maternal and neonatal outcomes in gestational diabetes mellitus. *Int J Endocrinol Metab* 2007;3:109-115.
- [20] Saddler TW. Placenta and fetal membranes. In: *Langman's medical embryology*. Lippincott Williams & Wilkins 2004;91-111.
- [21] Patric MC, Mark BL, Steven G. Diabetes mellitus. In: *Reproductive endocrinology, surgery and technology*. Philadelphia: Lippincott 1996:1710-1720.
- [22] Saydah SH, Miret M, Sung J, et al. Postchallenge hyperglycemia and mortality in a national sample of US adults. *Diabetes Care* 2001;24(8):1397-1402.
- [23] Burstein R, Soule SD, Blumenthal HT. Histogenesis of pathological processes in placentas of metabolic disease in pregnancy. II. The diabetic state. *Am J Obstet Gynecol* 1957;74(1):96-104.
- [24] Clavero-Nunez JA. The placenta in diabetes. *Rev Iber Endocrinol* 1963;10:73-80.
- [25] Dashkevich OV, Sechonov IM. The morphology of placenta in diabetes mellitus. *Arkh Pat* 1964;26:7.
- [26] Aerts L, Holemans K, Van Assche FA. Maternal diabetes during pregnancy: consequences for the offspring. *Diabetes Metab Rev* 1990;6(3):147-167.
- [27] Kjos SL, Buchanan TA. Gestational diabetes mellitus. *New England Journal of Medicine* 1999;341:1749-1756.
- [28] Khaskhelli LB, Memon S, Goswami P, et al. Change in normal morphology of placenta and its possible effects on fetal outcome in diabetic mothers as compared to non-diabetic mothers. *Jamshoro Liaquat University of Medical and Health Science* 2013;12(01):49-54.
- [29] Kucuk M, Doymaz F. Placental weight and placental weight-to-birth weight ratio are increased in diet- and exercise-treated gestational diabetes mellitus subjects but not in subjects with one abnormal value on 100-g oral glucose tolerance test. *J Diabetes Complications* 2009;23(1):25-31.
- [30] Jauniaux E, Burton GJ. Villous Histomorphometry and placental bed biopsy investigation in type I diabetic pregnancies. *Placenta* 2006;27(4-5):468-471.
- [31] Dashe JS, McIntire DD, Twickler DM. Effect of maternal obesity on the ultrasound detection of anomalous fetuses. *Obstet Gynecol* 2009;113(5):1001-1007.
- [32] Daskalakis G, Marinopoulos S, Krielesi V, et al. Placental pathology in women with gestational diabetes. *Acta Obstet Gynecol Scand* 2008;87(4):403-407.
- [33] Rudge MV, Lima CP, Damasceno DC, et al. Histopathological placental lesions in mild gestational hyperglycemic and diabetic women. *Diabetol Metab Syndr* 2011;3(1):19.
- [34] Verma R, Mishra S, Kaul JM. Cellular changes in the placenta in pregnancies complicated with diabetes. *International Journal of Morphology* 2010;28(1):259-264.
- [35] Luoto R, Kinnunen TI, Aittasalo M, et al. Primary prevention of gestational diabetes mellitus and large-for-gestational-age newborns by lifestyle counseling: a cluster-randomized controlled trial. *PLoS Medicine* 2011;8(5):e 1001036.