

POSTERIOR LUMBAR INTERBODY FUSION AND INSTRUMENTED POSTEROLATERAL FUSION IN ADULT SPONDYLOLISTHESIS: ASSESSMENT AND CLINICAL OUTCOME

N. S. Rajarajan¹, Vijayan Balakrishnan²

¹Associate Professor, Department of Orthopaedics, ESIC Medical College & PGIMSIR.

²Assistant Professor, Department of Orthopaedics, ESIC Medical College & PGIMSIR.

ABSTRACT: OBJECTIVE: Aim of this study is to assess and compare the outcomes of posterior lumbar interbody fusion (PLIF) and posterolateral fusion (PLF) in adult isthmic spondylosis.

BACKGROUND: Posterolateral fusion has been considered the best method and widely been used for surgical treatment of adult spondylosis. Superior results have subsequently been reported with interbody fusion with cages and posterior instrumentation

MATERIALS AND METHODS: Thirty six patients with isthmic spondylosis were operated. One group (20 patients) had decompression and posterolateral fusion (PLF) with a pedicle screw system; other group (16 patients) was treated by decompression, posterior lumbar interbody fusion (PLIF) and a Pedicle screw system. In both groups adequate decompression was done

RESULTS: Seventy seven percent of the patients had a good result with (PLIF) and 68 percent with posterolateral fusion (PLF). However there was no statistical difference in cases with low grade slipping, whereas the difference was significant for cases with high grade slipping. Fusion rate was 93% with (PLIF) and 68% with (PLF), but without any significant incidence in the functional outcome. 78% has relief of sciatica and neurogenic claudication.

CONCLUSION: Based on these findings we found that for high grade spondylosis which requires reduction or if the disc space is still high posterior lumbar inter body fusion is preferable. For low grade spondylosis or if the disc space is narrow posterolateral fusion is preferable. A successful result of fusion operation depends on adequate decompression which relieves radicular symptoms.

KEYWORDS: Spinal fusion, Spondylosis, Posterior lumbar interbody fusion, Posterolateral fusion.

HOW TO CITE THIS ARTICLE: N. S. Rajarajan, Vijayan Balakrishnan. "Posterior Lumbar Interbody Fusion and Instrumented Posterolateral Fusion in Adult Spondylosis: Assessment and Clinical Outcome". Journal of Evidence based Medicine and Healthcare; Volume 2, Issue 46, November 09, 2015; Page: 8236-8240, DOI: 10.18410/jebmh/2015/1111

INTRODUCTION: The term spondylosis was coined by Kilian¹ in 1854 from the Greek spondylo meaning vertebra and listhesis meaning slip. In 1855 Lambi correctly identified the nature of the defect.

There is different type of spondylosis. Wiltse performed the first systematic classification according to etiology, differentiating between congenital, isthmic, degenerative, and pathological and iatrogenic.²

In adults the most frequent are those due to lesions of the interarticular isthmus and of degenerative origin. The incidence of isthmic spondylosis is between 6% and 7% and of degenerative spondylosis is around 8.7%. Both types are common in women.

The clinical presentation and natural history of spondylosis is variable. Chronic pain of long duration is normally the earliest. It is sometimes found by accident while in others the process can evolve until it severely compromises the spinal content at the affected level.

Despite much publication related to the distinct method of fixation and fusion that can be used in the treatment of different types of spondylosis, the handling of this condition is still very controversial.

Cloward's technique³ and its modification by Lerat are efficient for lumbar fusion in spondylosis. In 1990, Brantigan⁴ proposed a new technique using intersomatic carbon cages, which has given safe and reproducible results. However this technique must be compared with the classical posterolateral fusion. The goal of our study is to analyze two series of fusion with regard to functional results.

MATERIALS AND METHODS: We made a prospective non-randomized study of 36 patients with spondylosis. The indication for fusion was cases of spondylosis complaining of low back pain with or without sciatica and neurogenic claudication. The patients were allocated to two groups according to the mode of bony fusion into PLIF and PLF groups. The two groups were statistically similar with respect to demographic and clinical data.

In instrumented PLF group of 20 patients adequate root and Dural decompression was done by the Gill technique followed by a posterolateral fusion using pedicle screw instrumentation and autologous bone graft from the resected laminae. There were 12 male and 8 female

Submission 27-10-2015, Peer Review 28-10-2015,

Acceptance 02-11-2015, Published 07-11-2015.

Corresponding Author:

N. S. Rajarajan,

22, Kalimmon Koil Street,

Sai Nagar, Virugambakkam, Chennai-92.

E-mail: drnsrajarajan@yahoo.com

DOI: 10.18410/jebmh/2015/1111

patients, with a mean age of 50.3 years (range 45 to 63 years). The slipping was grading 1 in 8 cases, grade 2 in 7 cases and grade 3 in 5 cases.

In the PLIF group of 16 patients, root and Dural decompression was done by Gill technique followed by fusion using pedicle screw instrumentation and intersomatic arthrodesis titanium cages filled with autologous bone graft from the laminectomy with posterolateral bone grafting (360° fusion). The sex ratio was 9males and 7 females the mean age was 48.7 years (46 to 60years). The slipping grade was grade 1 in 7 cases, grade 2 in 5 cases and grade 3 in 3 cases.

A minimum 18-month follow-up was available in all patients. For clinical evaluation, the patients visual analogue scale (VAS) scores for leg and back pain were administered at 6-monthly intervals, where the sixth postoperative month was considered the short-term VAS and those obtained at 18 months or later were considered the long-term VAS.

The Oswestry disability index (ODI)⁵ questionnaire with its 10-item ordinal scale (pain intensity; personal care; ability to lift, walk, sit, stand, and sleep; sex life; social; and traveling; each item had six responses, where 0 was normal functionality and 5 the worst, and the sum of these is multiplied by two, thus providing a worst sum of 100 and a best of 0) was administered in a similar manner as the VAS.⁶

Anteroposterior, lateral, and dynamic radiographs views were performed at 3, 6, 12, and 18 month postoperatively for all patients, and, if possible, in subsequent visits, where the last was considered the final follow-up. Solid bony fusion was considered when bridging bony trabecular continuity were documented radiographically.⁷

This was very easy in cases with a radiolucent cage. In cases with a posterolateral graft, we considered that fusion was complete if it was visible on the frontal view or if a spontaneous anterior bridge had occurred.

The intersomatic fusion (PLIF) was established according to the criteria described by Brantigan et al.⁸ Those authors employed a scale of 5 levels, Level 5, radiological fusion; Level 4, probable radiological fusion; Level 3, uncertain radiological stage; Level 2, probable radiographic pseudarthrosis; Level 1, obvious radiographic pseudarthrosis. Levels 5 and 4 usually have excellent radiological outcome:

The degree of posterolateral fusion (IPFL) was determined employing the method used by Lenke et al.⁹ It is specified in the following manner: Grade A, definitive fusion with bilateral thick bony masses; Grade B, probable fusion with thick bony mass in one side and thin bony mass on the other; Grade C, no probable fusion with thin bony mass on one side and probable pseudarthrosis on the contralateral side; Grade D, no fusion, with thin bony mass on both sides With obvious bony pseudarthrosis or reabsorption of graft bilaterally. Grades A and B usually have excellent radiological outcome

STATISTICAL ANALYSIS: The statistical study used the chi squared test. Statistical significance was set at 5%.

Functional Results: The study included 21 male and 15 female patients, with mean ages of 48.7 years in the PLIF group and 50.3 years in the PLF group. The two groups were statistically similar with respect to demographic and clinical data, which are summarized in [Table 1].

The minimum follow-up period in each group was 18 months. The mean follow-up period was 26 months (range, 18-46 month) for the PLIF group and 29 months (range, 20-52 month) for the PLF group; the difference between the two groups was not significant.

The average short-term visual analogue score for leg and back pain, measured at the sixth postoperative month, showed improved leg pain from 65 preoperatively to 29, whereas back pain improved from 70 preoperatively to 34 in the PLF group and the PLIF leg pain from 68 to 24 and back pain 72 to 29, but the difference between the two groups was not significant The final follow-up visual analogue score for leg and back pain showed improved leg pain in PLIF groups to 22 and remains the same in 30 in PLF group, whereas back pain improved in PLIF to 18 and increased to 39 in the PLF group; the difference between the two groups was significant in terms of long-term VAS for back pain.

There was a marked reduction in the preoperative ODI from that recorded in the final examination. The PLF group had a mean preoperative ODI of 36.5 (range, 22-82) that was reduced to a mean of 23.1 (Range, 2-55) at the final postoperative follow-up. However, in the PLIF group, it was reduced from 34.2 (Range, 24-68) preoperatively to 14.2 (Range, 0-36). The difference between the two groups was significant.

The result is different if we take into account the grade of slipping. In grade II or III, we observed good or very good results in 83% of cases with PLIF, versus 49% in cases with PLF. Return to work at the same level was achieved earlier and in a higher proportion of cases in the PLIF group (60% at 8 months) than in the PLF group (55% at 10 months).

Complications: There were no intra-operative complications such as bleeding or nerve root injury.

In one case, introduction of the cage was impossible because the canal was too narrow. Complications were noted during the postoperative period: In the posterolateral fusion group (PLF), four patients had transient radiculopathy related to radicular manipulation and actual root injuries and they resolved spontaneously.

5 patients (13%) underwent a second surgery, all of whom had radiological nonfusion a patient (6%) from the PLIF group because of the occurrence of pseudarthrosis and persistence of severe back pain because of mechanical failure in a grade 3 spondylolisthesis with a short single level instrumentation, and four patients (20%) from the PLF group for persistent severe back pain radiating pain, loosening of the screws in two cases and screw breakage

in one. In their second surgery, PLIF was performed. The difference between PLIF and PLF was significant.

One patient had breakage of both S₁ screws under repeated stress because of failure of fusion which required implant removal.

In the PLIF group two patients had postoperative aggravation of the radicular pain which subsided spontaneously.

One patient had superficial surgical infection which resolved after two weeks with appropriate antibiotic therapy.

Radiological Results: Radiological fusion was confirmed in 14 patients (93%) of the PLIF group [Figure 1] and 13 patients (68%) in the PLF group [Figure 2] by the end of the first year. The difference in the prevalence of fusion between the two groups was significant. In 5 patients (25%) of PLF group spontaneous anterior interbody fusion has developed at follow-up in cases with narrow disc space.

DISCUSSION: Even though majority of patients respond well to conservative treatment, it is estimated that the percentage of patients need surgical treatment has increased considerably recently because of the active demanding life style to resolve symptoms which affects their daily activities.

The surgery has two aims: to improve the back pain and neurological symptoms, and thus the quality of life, and to detain the progressive vertebral slipping.

The back pain is due to local mechanical instability which requires rigid fixation and solid fusion. The neurological symptoms to nerve root compression and Dural compression which requires adequate decompression. The vertebral slipping can be arrested by rigid solid fusion This is in accordance with Vibert stated that laminectomy without fusion should be carried out only on patients with practically rigid segment by reactive sclerosis.¹⁰

In the last two decades, the improvement of the surgical techniques has increased the number of patients treated with surgery, with good clinical results. However, there still exists a very important discussion about which is the best surgical technique to treat symptomatic spondylolisthesis.

The posterolateral fusion (PLF) diminishes the possibilities of instability, but the proportion of stable fusions is low as it does not allow us to control the biomechanics of the anterior spine.^{11,12} In this series 4 patients with high grade spondylolisthesis with high disc space treated by instrumented PLF and lateral mass bone grafting had hardware failure and persistent back pain at follow up. In the PLF group grade 1 spondylolisthesis and cases with narrow disc space gives good clinical outcome and solid fusion. In a few patients in this group spontaneous anterior fusion was noted at follow-up.

The posterior lumbar intersomatic fusion (PLIF) allows us to restore the disc height, facilitate the correction of alignment and balance, immobilize the pathological space,

improving in this way the stability, and decompressing the dural sac and the roots.

In our series in PLIF group reduction is achieved in high grade spondylolisthesis. Reduction creates an anterior disc distraction and PLIF more efficiently stabilizes and maintains this instability. This improves the lumbar lordosis and the segmental angle. This explains the better results achieved with PLIF with respect to back pain. PLIF also provide a significant increase in the disc height and foramina height, supplemented with adequate decompression gives marked improvement in the leg pain.

In our findings majority of the patients with symptomatic spondylolisthesis in addition to low back ache had radicular pain in the legs. Clinical examination and MRI showed L⁵ and S¹ nerve root involvement. Surgical exploration revealed nerve root compression by a mass of fibro cartilage tissue at the pars interarticularis defect of the fifth lumbar vertebra. Movement of the loose lamina, rattler segment also cause dural irritation and nerve root compression. Surgical decompression of the rattler lamina and the fibro cartilage mass at the defect in the pars interarticularis has given relief of both radicular pain and the low back pain. In our study we did adequate surgical decompression in all our cases.

A comparative study between PLIF and PLF by Madan and Boeree¹³ showed that the clinical result was better with PLF for low grade spondylolisthesis (81% versus 69% for PLIF). Fusion and persistence of the correction was better with the PLIF technique.

Brantigan¹⁴ reported a 98- 9/ fusion rate 86/ clinical success in their PLIF group when augmented by posterior instrumentation.

Dantas et al.¹⁵ reported that PLIF augmented by transpedicular screws led to better clinical outcomes, Prolog economic, and functional scales, and fewer complications when compared with PLF. This is in agreement with the results obtained in this study.

La Rosa et al.¹⁶ support the view that PLIF confers a superior mechanical strength to the spinal construct, whereas in PLF, there is a progressive reduction in the correction achieved, but not to the extent to affect the clinical outcome.

Deuhoux et al.¹⁷ reported that fusion rates are directly proportional to the degree of slippage and disk height, while not affecting the functional outcome. Hence, they prefer to use PLIF for high-grade spondylolisthesis requiring reduction or if the disk space is still high, whereas in low-grade slippage, or narrow disk spaces, PLF is preferable.

Mada n et al.¹⁸ reported better clinical outcome in low grades of isthmus spondylolisthesis with PLF than PLIF, although they report that PLIF fusion is more predictable in maintaining correction and achieving union.

Wu et al.¹⁹ reported a significant reduction in both pain and Oswestry disability indices for both PLIF and PLF groups, where 88% of the patients in the PLF group and 91% of the patients in the PLIF group had radiological fusion, which was statistically insignificant. Although both

techniques were comparable in terms of the outcome, PLF had greater tendency for hardware failure than the PLIF group.

In our PLIF group we made anterior grafting and lateral mass fusion because we believe that after decompression anterior cage added with lateral mass fusion give a strong stable fusion.

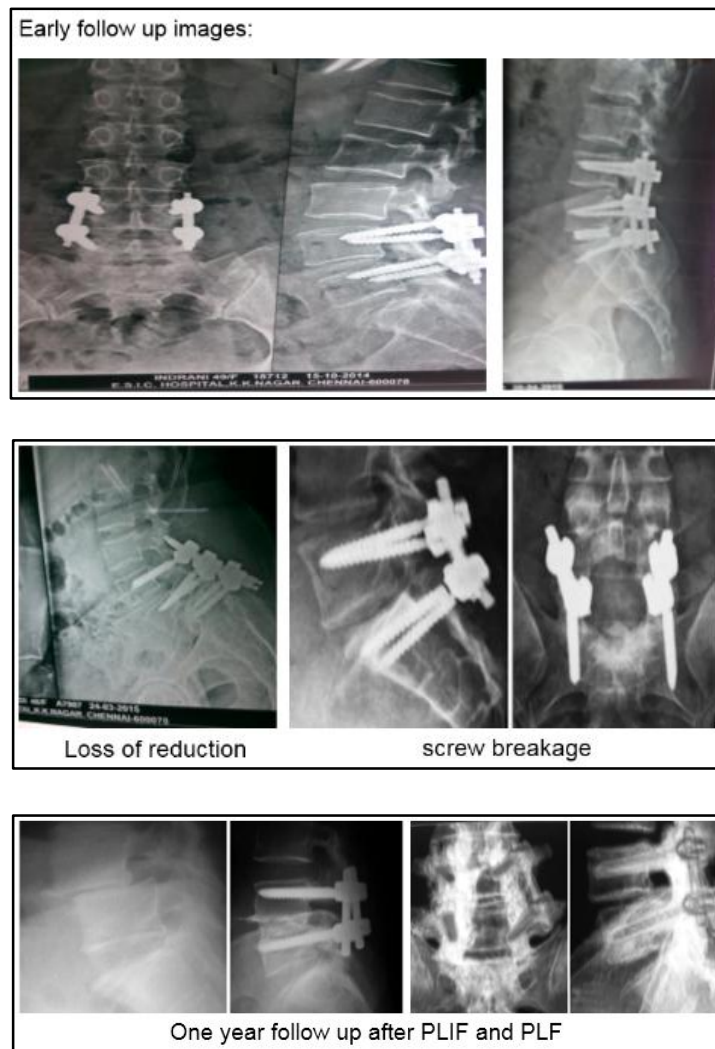
Analyzing our study and correlating with the literatures that PLF gives better clinical outcome and satisfactory fusion rates in low grade spondylolisthesis or in narrow disc spaces where the segment is rigid anteriorly. In high grade spondylolisthesis and in cases with high disc space where the segment is unstable both anteriorly and posteriorly PLIF fusion is more predictable in maintaining correction and achieving union.

CONCLUSION: In accordance with the literature, PLIF gave in our experience better clinical outcomes, better fusion rates, better maintenance of reduction, and fewer construct failure than PLF. This difference was significant in high grade spondylolisthesis. Based on the findings in this study, for grade I spondylolisthesis, or in cases with a narrow disc, PLF with adequate decompression is adequate for better clinical results and good fusion.

In high grade spondylolisthesis, grade 3 or 4, which requires reduction or when the disc space is still high, adequate decompression, PLIF with instrumented PLF and lateral mass fusion seems to be better option on the basis of better clinical outcome and high fusion rate and gives more secure stabilization of the segment.

REFERENCES:

1. Kilian H. Mannheim: Verlag Von Bosserman; 1854. Schilder ungenueher becken for men und ihresverhaltens in lebeded.
2. Wiltse LL, Newman PH, Macnab I. Classification of spondylolysis and spondylolisthesis. *Clin Orthop Relat Res.* 1976; 117: 23–29. [PubMed].
3. Cloward RB. Spondylolisthesis. Treatment by laminectomy and posterior interbody fusion. Review of 100 cases. *Clin Orthop* 1981; 154-174.
4. Brantigan JW, Steffee AD, Lewis M, Quinn L, Persenaire M. Lumbar interbody fusion using Brantigan I/F cage for PLIF and VSP pedicle screw system: Two year clinical results of the FDA clinical trial. Sauramps, Montpellier, 1996, pp 239-269.
5. Fairbank JC, Pynsent PB. The Oswestry disability index. *Spine* 2000; 25: 2940-2952.
6. Fairbank JC, Couper J, O' Brien JP. The Oswestry Low Back Pain Disability Questionnaire. *Physiotherapy* 1980; 66: 271-273.
7. Suk S, Lee C-K, Kim W-J, et al. Adding posterior lumbar interbody fusion to pedicle screw fixation and posterolateral fusion after decompression in spondylolytic spondylolisthesis. *Spine* 1997; 22: 210-220.
8. Brantigan JW, Steffee AD. A carbon fiber implant to aid the interbody lumbar fusion: two – year clinical results in the first 26 patients. *Spine.* 1993; 18: 2106–2117. [PubMed]
9. Lenke LG, Bridwell KH, Bullis D, Betz RR, Baldus C, Schoenecker PL. Results of in-situ fusion for isthmic spondylolisthesis. *J Spinal Disord.* 1992; 5: 433–442. [PubMed]
10. Vibert BT, Sliva ChD, Herkowitz HN. Treatment of instability and spondylolisthesis. Surgical versus nonsurgical treatment. *Clin Orthop Relat Res.* 2006; 443: 222–227. [PubMed]
11. Loubresse CG, Bon T, Deburge A, Lassale B, Benoit M. Posterolateral fusion for radicular pain in isthmic spondylolisthesis. *Clin Orthop Relat Res.* 1996; 323: 194–201. [PubMed]
12. Vaccaro AR, Ring D, Scuderi G, Cohen DS, Garfin SR. Predictors of outcome in patients with chronic back pain and low-grade spondylolisthesis. *Spine.* 1997; 22: 2030–2034. [PubMed]
13. Madan S, Boeree NR. Outcome of posterior lumbar interbody fusion versus posterolateral fusion for spondylolytic spondylolisthesis. *Spine* 2002; 27: 1536-1542.
14. Brantigan JW, Steffee AD, Lewis ML, Quinn LM, Persenaire JM. Lumbar interbody fusion using the Brantigan I/F cage for posterior lumbar interbody fusion and the variable pedicle screw placement system. Two-year results from a Food and Drug Administration investigational device exemption clinical trial. *Spine* 2000; 25: 1437-1446.
15. Dantas FL, Prandini MN, Ferreira MA. Comparison between posterior lumbar fusion with pedicle screws and posterior lumbar interbody fusion with pedicle screws in adult spondylolisthesis. *Arq Neuropsiquiatr* 2007; 65: 764-770.
16. La Rosa G, Conti A, Cacciola F, et al. Pedicle screw fixation for isthmic spondylolisthesis: does posterior lumbar interbody fusion improve outcome over posterolateral fusion? *J Neurosurg* 2003; 9: S143-S150.
17. Dehoux E, Fourati E, Madi K, Reddy B, Segal P. Posterolateral versus interbody fusion in isthmic spondylolisthesis: functional results in 52 cases with a minimum follow-up of 6 years. *Acta Orthop Belg* 2004; 70: 578-582.
18. Madan S, Boeree NR. Outcome of posterior lumbar interbody fusion versus posterolateral fusion for Spondylolyticspondylolisthesis. *Spine* 2002; 27: 1536-1542.
19. Wu Y, Tang H, Li Z, Zhang Q, Shi Z. Outcome of posterior lumbar interbody fusion versus posterolateral fusion in lumbar degenerative disease. *J Clin Neurosci* 2011; 18: 780-783.



CHARACTERISTICS	PLIF	PLF
Male/ Female	9/7	12/8
Age		
Range	46-60	45-63
Mean	48.7	50.3
Duration of symptoms		
<2 years	7	11
>2 years	9	9
Surgery level		
One level	14	17
Two levels	2	3
Follow up		
Range	18-28	18-30

Table 1

PRE OPERATIVE	PLIF	PLF
Leg pain	68	65
Back pain	72	70
Short term(VAS)		
Leg pain	24	29
Back pain	29	34
Long term(VAS)		
Leg Pain	22	30
Back pain	18	39

Table 2: VISUAL ANALOG SCALE

ODI	PLIF	PLF
Pre-operative	34.2	36.5
Final follow up	14.2	23.1

Table 3