

## ROLE OF MULTIDETECTOR ROW COMPUTED TOMOGRAPHY IN EVALUATION OF BILIARY TRACT OBSTRUCTIVE JAUNDICE

Akshaya Reddy Erasu<sup>1</sup>, Indira N<sup>2</sup>, Ram Prakash H. V<sup>3</sup>

### HOW TO CITE THIS ARTICLE:

Akshaya Reddy Erasu, Indira N, Ram Prakash H. V. "Role of Multidetector Row Computed Tomography in Evaluation of Biliary Tract Obstructive Jaundice". Journal of Evidence based Medicine and Healthcare; Volume 2, Issue 13, March 30, 2015; Page: 1939-1949.

**ABSTRACT: INTRODUCTION:** Obstructive jaundice is a type of jaundice in which there is blockage of flow of bile from the liver to the intestine resulting in redirection of excess bile and its by-products like bilirubin into the blood. It can lead to complications like ascending cholangitis, hepatorenal syndrome and malabsorption, hence requiring urgent surgical intervention. The role of a radiologist therefore is important in early diagnosis and in accurately delineating the level and the cause of obstruction, thus helping in staging as well as preoperative assessment of tumor resectability. The search for noninvasive diagnostic tools is an emerging medical need, in order to avoid invasive, costly and physician-intensive procedures such as endoscopic retrograde cholangiopancreatography (ERCP).<sup>(1)</sup> Ultrasound is a non-invasive and cost effective imaging technique available for evaluating biliary tract obstruction. Ultrasound demonstrates the presence of biliary tract obstruction by identifying dilated bile ducts but has a sensitivity of 55%-95% and specificity of 71%-96 %.<sup>(2)</sup> The role of magnetic resonance cholangiography (MRCP) is well established in this field as the most reliable noninvasive technique.<sup>(3)</sup> However, some drawbacks, such as contraindication in patients with pacemakers and ferromagnetic implants, for claustrophobic patients, long examination times exceeding 30 minutes and limited availability of scanners still limit its use. MRCP is expensive and has limitations such as interference from intraluminal gas, pneumobilia and flow artifacts.<sup>(4)</sup> In the past, axial conventional CT could not provide adequate information of biliary abnormalities since the total depiction of these ducts was not suitable for evaluation in axial planes.<sup>(5)</sup> MDCT's ability to obtain volume dataset with sub-millimeter spatial resolution allows the optimal display of bile duct by using multiplanar reconstruction (MPR) and minimal intensity projection (MinIP) without compromising on image quality. The combined use of MPR and MinIP techniques significantly improves the visualization of the biliary ducts and their site of confluence compared with those obtained by axial CT.<sup>(5)</sup> The purpose of the present study is to evaluate the utility of MDCT in suspected patients with biliary tract obstruction by establishing the cause of obstruction, location of obstruction and to differentiate between benign and malignant causes by comparing with ERCP, surgical or histopathological findings.

**KEYWORDS:** Biliary tract obstruction, Multidetector computed tomography cholangiography, benign, malignant.

**MATERIALS AND METHODS:** A prospective study conducted in Department of Radio-diagnosis, Vydehi Institute of Medical Sciences and Research Centre, Bangalore on 50 patients with clinical suspicion of jaundice or ultrasound detected biliary tract dilatation between Dec 2012 to Nov

# ORIGINAL ARTICLE

2014. Patients who are less than 10 years, pregnant ladies, patients allergic to contrast and patients with renal insufficiency were excluded.

Informed consent was taken from all the patients and the study was approval by Ethics committee.

## TECHNICAL CONSIDERATION:

**Examination Technique:** All MDCT examinations was performed on empty stomach after giving 800ml of oral mannitol, with a 16-channel MDCT scanner (GE Light Speed RT). CT was performed in unenhanced, arterial, portal and venous phases. Unenhanced CT with 1mm collimation of the upper abdomen was performed after which, contrast enhanced CT images was obtained using a 18sec delay during hepatic arterial dominant phase and a 45 to 50 seconds delay during portal dominant phase and 90 seconds delay during venous dominant phase after the initiation of IV injection of 80ml non-ionic contrast material (IOHEXOL) at the rate of 3.5ml/s using a power injector.

**Image interpretation:** Interpretation of the CT images will be performed on a workstation equipped with a software tool, which allows generation of maximum intensity projections (MIPs), Volume Renderings (VRs), and Multiplanar Reconstructions (MPRs). The reconstructed images were evaluated for the level and cause of obstruction.

All the cases were comprehensively evaluated and correlated with relevant history, clinical, ERCP, intraoperative and histopathological findings.

**STATISTICAL METHODS:** Data obtained was tabulated using version 22 of the Statistical Package for Social Sciences (SPSS, published SPSS Inc.) and subjected to appropriate statistical analysis. Open EPI software was used to calculate sensitivity, specificity, positive predictive value, negative predictive value and diagnostic accuracy of MDCT for detection of the level of biliary tract obstruction and the cause of biliary tract obstruction were evaluated.

**RESULTS:** In the age group belonging to 30 to 60 years of age with a mean age of 48 years. The youngest patient was a 15 years old female with distal CBD stricture and the oldest was 75 years old male with choledocholithiasis.

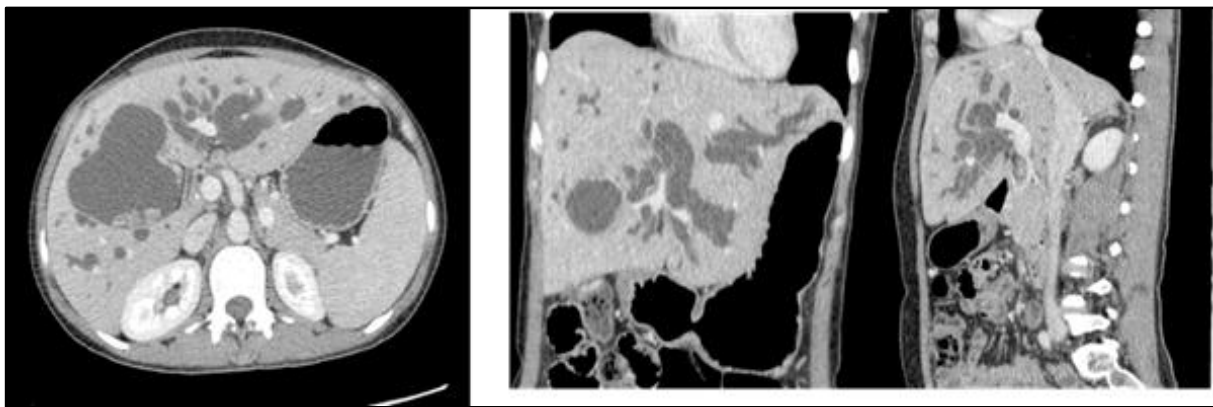
Out of 50 patients, 26 (52%) are male with a mean age of 50.1 years and 24 (48%) are female with a mean age of 45.5 years. There is male predominance male: female ratio being 1.08:1.

	On MDCT	Final/ Primary
<b>Cholangiocarcinoma</b>	<b>16</b>	<b>15</b>
Carcinoma Head of Pancreas	6	6
<b>Periampullary Carcinoma</b>	<b>4</b>	<b>5</b>
Carcinoma Gall Bladder	3	3
Choledocholithiasis	2	2
<b>Common Bile Duct Stricture</b>	<b>7</b>	<b>6</b>

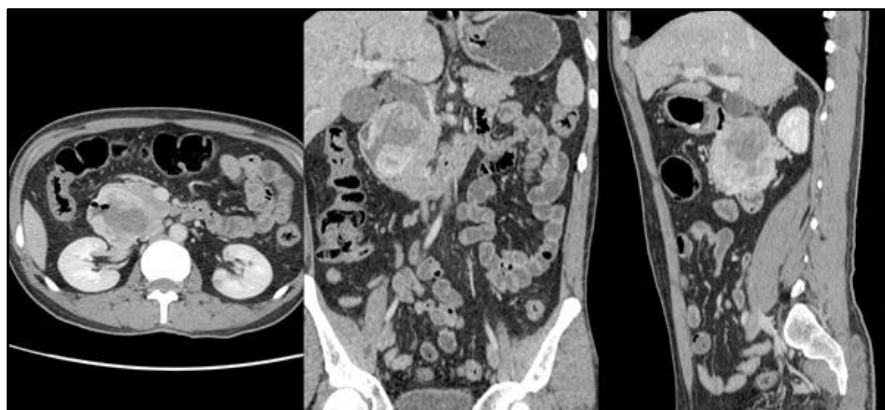
# ORIGINAL ARTICLE

Choledochal Cyst	5	5
Mirizzi Syndrome	1	1
Pancreatic Head Inflammatory Mass Lesion Compressing Distal CBD	1	1
Hepatocellular Carcinoma	2	2
<b>Spincter of Oddi Dysfunction</b>	<b>0</b>	<b>1</b>
Duodenal Malignancy	2	2
Portal Vein Compressing Common Hepatic Duct	1	1
<b>Total</b>	<b>50</b>	<b>50</b>

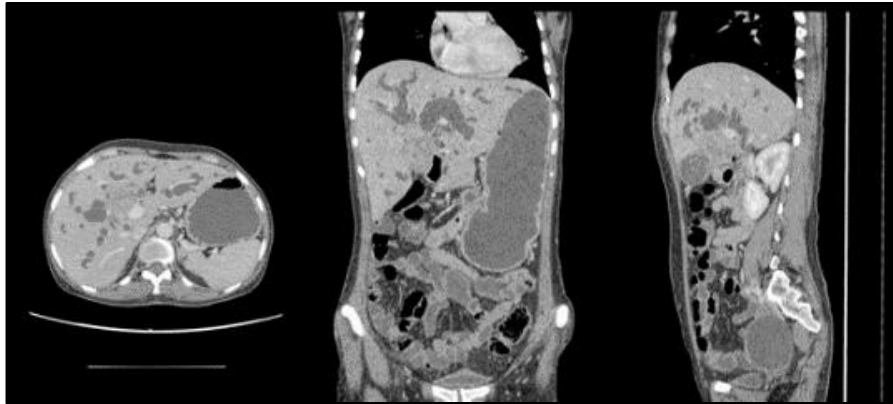
Table 1: Diagnosis



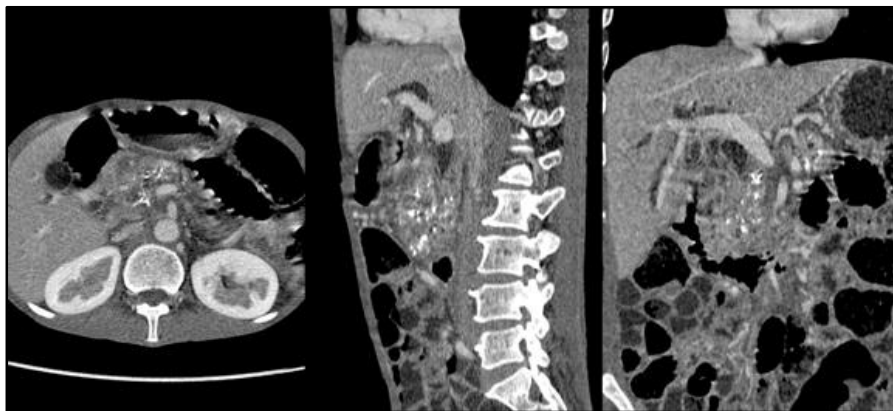
**Fig. 1: Multiplanar images of Caroli's disease with associated hepatolithiasis in left hepatic duct**



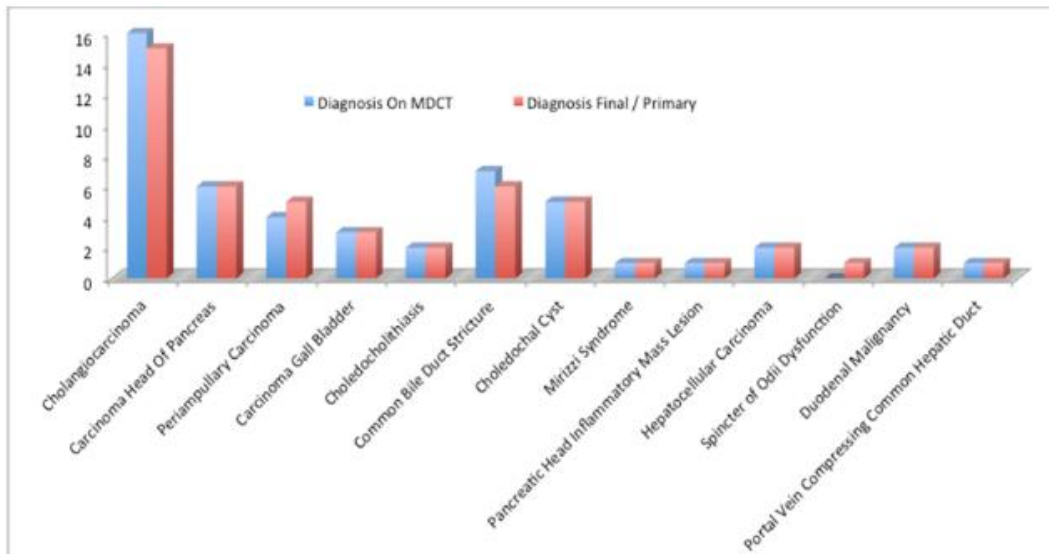
**Fig. 2: Multiplanar images of periampullary carcinoma**



**Fig. 3: Multiplanar images of klatskin's tumour**



**Fig. 4: Multiplanar images of benign stricture due to chronic pancreatitis**



**Graph 1: Diagnosis**

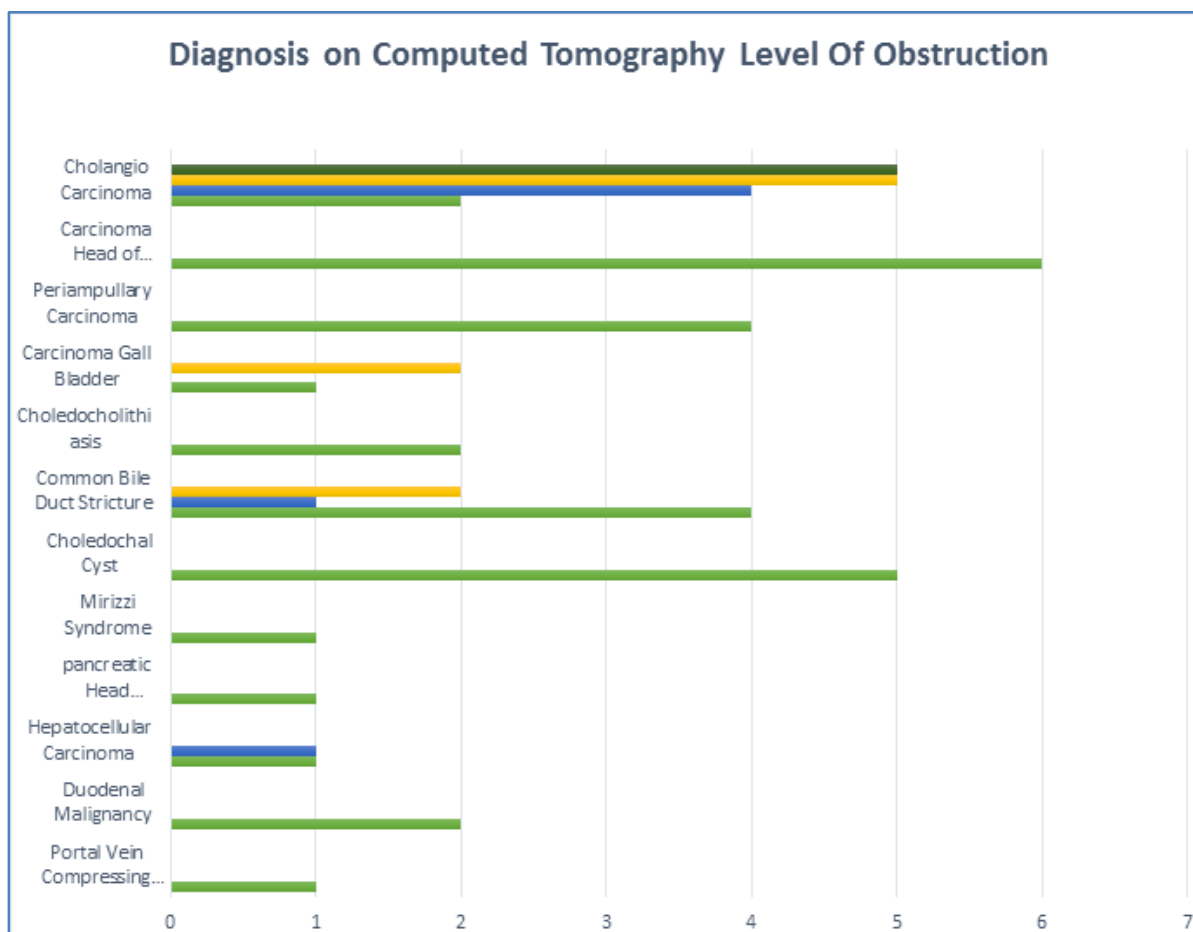
## ORIGINAL ARTICLE

All the pathologies were detected by MDCT, which characterized 17(34%) patients as having benign causes of biliary tract obstruction, out of which, 1 case (2%) diagnosed on MDCT as distal CBD stricture was proven to be Sphincter of Oddi Dysfunction on final diagnosis by ERCP.

Out of 33(66%) cases characterized as malignant cause of biliary tract obstruction, 1 case (2%) diagnosed on MDCT as extrahepatic cholangiocarcinoma was proven to be carcinoma head of pancreas on final diagnosis by intraoperative and histopathological examination.

Diagnosis on Computed Tomography	Level Of Obstruction						Total
	No Obstruction	Intra Hepatic	Porto Hepatic	Supra Pancreatic	Intra Pancreatic	Duodenal	
Cholangiocarcinoma	0	5	5	4	2	0	16 (32%)
Carcinoma Head Of Pancreas	0	0	0	0	6	0	6 (12%)
Periampullary Carcinoma	0	0	0	0	4	0	4 (8%)
Carcinoma Gall Bladder	0	0	2	0	1	0	3 (6%)
Choledocholithiasis	0	0	0	2	0	0	2 (4%)
Common Bile Duct Stricture	0	0	2	1	4	0	7 (14%)
Choledochal Cyst	5	0	0	0	0	0	5 (10%)
Mirizzi Syndrome	0	0	1	0	0	0	1 (2%)
Pancreatic Head Inflammatory Mass	0	0	0	1	0	0	1 (2%)
Hepatocellular Carcinoma	0	1	1	0	0	0	2 (4%)
Duodenal Malignancy	0	0	0	0	0	2	2 (4%)
Portal Vein Compressing Common Hepatic Duct	0	0	1	0	0	0	1 (2%)
Total	5 (10%)	6 (12%)	12 (24%)	8 (16%)	17 (34%)	2 (4%)	50 (100%)

**Table 2: Cross tabulation of Diagnosis on Computed Tomography for cause and Level of Biliary Tract Obstruction**



**Graph 2: Diagnosis on Computed Tomography for cause and Level of Obstruction**

	Frequency	Percent
Benign	17	34
Malignant	33	66
Total	50	100

**Table 3: Nature Of Obstruction**

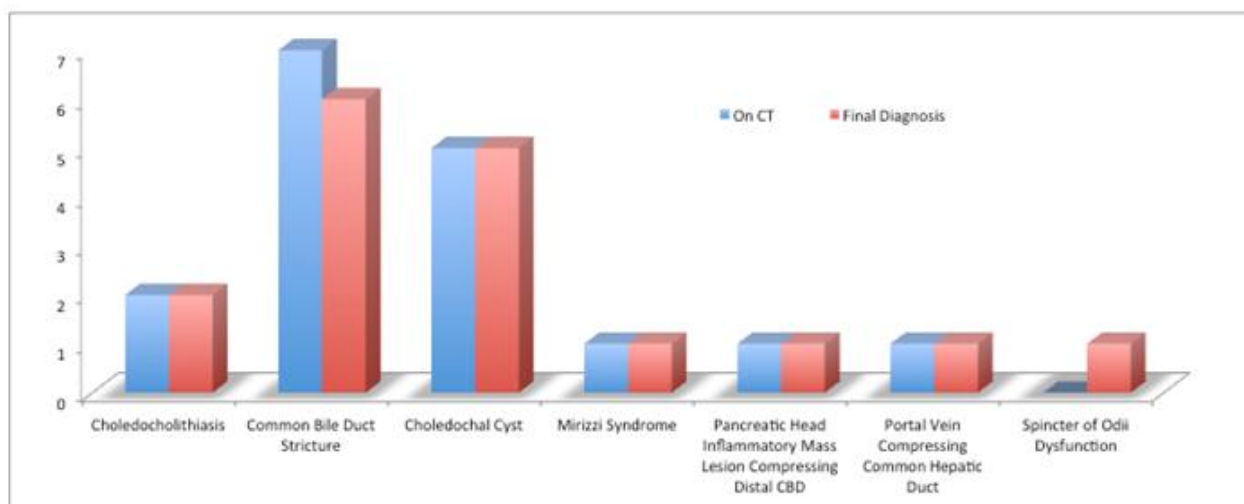
The incidence of malignant cause of biliary tract obstruction was 66% as compared to 34% of benign casue of biliary tract obstruction. The ratio of malignant cause to benign cause is 1.94:1 the mean age of patients with benign cause was 42.7 years and that with malignant cause was 50.6 years.

	On CT	Final Diagnosis
Choledocholithiasis	2	2
Common Bile Duct Stricture	7	6

## ORIGINAL ARTICLE

Choledochal Cyst	5	5
Mirizzi Syndrome	1	1
Pancreatic Head Inflammatory Mass Lesion Compressing Distal CBD	1	1
Portal Vein Compressing Common Hepatic Duct	1	1
Spincter of Odii Dysfunction	0	1
Total	17	17

**Table 4: Benign Causes of Obstruction Cross tabulation**



**Graph 3: Benign Causes of Obstruction**

All causes of biliary tract obstruction were detected by CT, which characterized 17 (34%) patients as having benign cause of biliary tract obstruction, Among benign causes, CBD stricture presented in 41% (7 patients), choledochal cysts presented in 29% (5 patients), choledocholithiasis presented in 11% (2 patients), mirizzi syndrome presented in 5.8% (1 patient), pancreatic head inflammatory mass lesion compressing distal CBD presented in 5.8% (1 patient) and portal vein compressing common hepatic duct presented in 5.8% (1 patient). 1 case diagnosed on MDCT as Distal CBD Stricture turned out to be Sphincter of Oddi Dysfunction on final diagnosis.

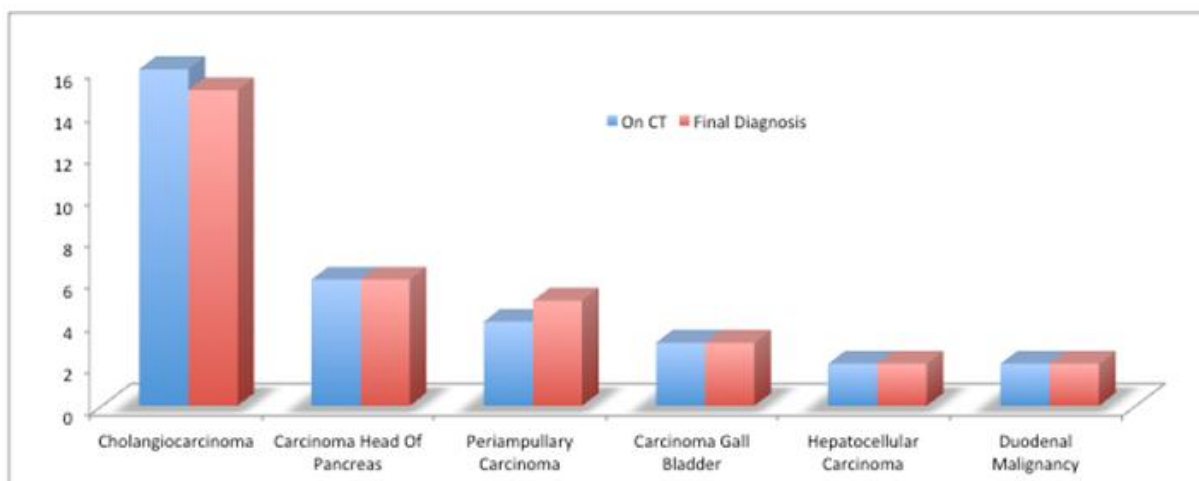
	On CT	Final Diagnosis
Cholangiocarcinoma	16	15
Carcinoma Head Of Pancreas	6	6
Periampullary Carcinoma	4	5
Carcinoma Gall Bladder	3	3
Hepatocellular Carcinoma	2	2
Duodenal Malignancy	2	2



# ORIGINAL ARTICLE

Total	33	33
-------	----	----

**Table 5: Malignant Cause of Obstruction Cross tabulation**



**Graph 4: Malignant Cause of Obstruction Cross tabulation**

Among malignant causes, cholangiocarcinoma presented in 48% (16 patients), carcinoma head of pancreas presented in 18% (6 patients), periampullary carcinoma presented in 12% (4 patients), carcinoma gall bladder presented in 9% (3 patients), hepatocellular carcinoma presented in 6% (2 patients) and duodenal malignancy presented in 6% (2 patients). 1 case diagnosed on MDCT as extrahepatic cholangiocarcinoma turned out to be carcinoma head of pancreas on final diagnosis.

	True Positive	False Positive	False Negative	True Negative	Total
Level	44	1	0	5	50
Cause	43	1	1	5	50
Benign	11	1	0	5	17
Malignant	32	1	1	0	33

**Table 6: Statistical Analysis of Computed Tomography For Biliary Tract Obstruction**

	Sensitivity	Specificity	Positive Predictive Value	Negative Predictive Value	Accuracy	p value
<b>Level of Obstruction</b>	100.00%	83.33%	97.77% (95% CI = 88.43 to 99.60%)	100.00% (95% CI = 56.55 to 100%)	98%	<0.001



## ORIGINAL ARTICLE

<b>Cause of Obstruction</b>	97.73%	83.33%	97.72% (95% CI = 88.19 to 99.59%)	83.33% (95% CI = 43.64 to 96.99%)	96%	<0.001
<b>Benign Cause of Obstruction</b>	100.00%	83.33%	91.66% (95% CI = 64.61 to 100%)	100.00% (95% CI = 56.55 to 100%)	94%	<0.001
<b>Malignant Cause of Obstruction</b>	96.97%	0%	100.00% (95% CI = 89.28 to 100%)	(95% CI = 0 to 79.34%)	97%	<0.001

**Table 7: Statistical Analysis of Computed Tomography for the Evaluation of Biliary Tract Obstruction**

**DISCUSSION:** Invasive methods such as endoscopic retrograde cholangiopancreatography (ERCP) and percutaneous transhepatic cholangiography (PTC) were used earlier for the evaluation of the biliary tract. However with the advent of MDCT and its rapid advancement in technology, it has enabled us to map the entire biliary tract and also to identify the level and cause of biliary tract obstruction.

In the present study, MDCT demonstrated evidence of biliary tract dilatation in 50 patients with peak incidence of biliary tract obstruction in the age group belonging to 30 to 60 years of age with a mean age of 48 years. The youngest patient of our study was 15 years old and the oldest was 75 years. 26 cases (52%) are males with a mean age of 50.1 years and 24 cases (48%) are females with a mean age of 45.5 years.

This study revealed higher incidence at 66% (33/50) of malignant causes, as opposed to 34% (17/50) incidence of benign cause of obstructive jaundice, possibly related to higher regional dietary and social factors. The mean age of patients with benign cause was 42.7 years and that with malignant cause was 50.6 years. A study by Ferrari FS et al (2005)<sup>(6)</sup> quotes Helical CT has an accuracy of 93% for differentiating benign from malignant biliary obstruction.

All the lesions were detected by CT, which characterized 17(34%) patients as having benign cause of biliary tract obstruction, among benign causes, CBD stricture presented in 41% (7 patients), choledochal cysts presented in 29% (5 patients), choledocholithiasis presented in 11% (2 patients), Mirizzi syndrome presented in 5.8% (1 patient), pancreatic head inflammatory mass lesion compressing distal CBD presented in 5.8% (1 patient) and portal vein compressing common hepatic duct presented in 5.8% (1 patient). 1 case diagnosed on MDCT as Distal CBD Stricture turned out to be Sphincter of Oddi Dysfunction on final diagnosis.

MDCT accurately characterized 33 patients (66%) as having malignant cause of biliary tract obstruction, among which cholangiocarcinoma presented in 48% (16 patients), carcinoma head of pancreas presented in 18% (6 patients), periampullary carcinoma presented in 12% (4 patients), carcinoma gall bladder presented in 9% (3 patients), hepatocellular carcinoma presented in 6% (2 patients) and duodenal malignancy presented in 6% (2 patients). 1 case

# ORIGINAL ARTICLE

---

diagnosed on MDCT as extrahepatic cholangiocarcinoma turned out to be carcinoma head of pancreas on final diagnosis.

MDCT detected no obstruction of the dilated biliary ducts in 5 patients for whom a diagnosis of choledochal cysts was made on MDCT, which is proven in favor by ERCP and histopathological examination.

The accuracy of conventional CT in determining the presence and level of obstruction was 81-94% and 88-92%, respectively which is greatly improved upon by MDCT findings in a study by O'Connor KW et al (1983)<sup>(7)</sup> and Lerttumnongtum P et al (2002),<sup>(8)</sup> the corresponding sensitivity of CT was 66.7% - 90.9%, specificity 77.8% - 100.0%, PPV 89.3% - 100.0%, NPV 87.5% - 94.4%, and p value was <0.001.

It should be mentioned that one case with biliary dilatation and obstruction, sphincter of Oddi Dysfunction was diagnosed as distal CBD stricture on MDCT. In another patient with biliary dilatation and obstruction at the intra-pancreatic level, carcinoma head of pancreas was diagnosed as extrahepatic cholangiocarcinoma on MDCT. Findings of focal, asymmetrical ductal wall thickening of 6mm led to an erroneous presumptive diagnosis of cholangiocarcinoma.<sup>(9)</sup>

Obstructing lesions of biliary tract such as neoplasms, calculi, pancreatic inflammatory masses, strictures were apparent on MDCT in 45 cases, with final/primary diagnoses correctly suggesting the CT findings in 43 cases (95.5%). Our study correlates with the findings of studies by Huang JQ et al (1993),<sup>(10)</sup> Sharma MP et al (1999),<sup>(11)</sup> Martin DF et al (2001)<sup>(12)</sup> and Siddique K et al (2008)<sup>(13)</sup> seeking to evaluate the etiological spectrum of obstructive jaundice.

A study by Ferrari FS et al (2005)<sup>(6)</sup> quotes, while conventional CT usually detects peripancreatic fluid collections such as pseudocysts and abscesses, in our experience, MDCT improves direct detection of the vascular complications of pancreatitis. While not seen in these this patient, such complications include pseudo-aneurysms of the gastro-duodenal and splenic artery, and thrombosis of the splenic, superior mesenteric, and portal veins.

The specificity and confidence with which a diagnosis can be suggested on MDCT are further increased by the high rate of detection of such associated findings as hepatic metastases, adenopathy in the porta hepatis or peripancreatic nodal groups or evidence of active pancreatic inflammation in most patients with biliary tract obstruction as quoted by Midwinter MJ et al (1999).<sup>(14)</sup>

**CONCLUSION:** MDCT has a vital role in the evaluation of the biliary tract obstruction. Spiral technique augments the diagnostic capability of CT, primarily due to the volume dataset with lack of spatial misregistration, thereby leading to optimal display of biliary ducts, their site of confluence and clearly demonstrating the level and extent of the disease.

## REFERENCES:

1. Tasneem Lalani, Corey AC, Max PR, Mark EB, et al: ACR appropriateness criteria on jaundice. American College of Radiology 2012.
2. Guibaud L, Bret PM, Reinhold C, Mostafa A, Barkun ANG Diagnosis of choledocholithiasis. Value of MR cholangiography. Am J Roentgenol (1994) 163: 847-850.
3. David V, Reinhold C, Hochman M, Chuttani R, McKee J, Waxman I, et al. Pitfalls in the interpretation of MR cholangiopancreatography. AJR Am J Roentgenol. 1998; 170:1055-9.

# ORIGINAL ARTICLE

- Moore KL and TVN Persaud: The Developing Human - Clinically Oriented Embryology, 7th ed. Elsevier Science (WB Saunders), Philadelphia (2003), p. 78.
- Ferrari FS, Fantozzi F, Tasciotti L, Vigni F, Scotto F, Frasci P. US, MRCP, CCT and ERCP: a comparative study in 131 patients with suspected biliary obstruction. Med Sci Monit. 2005; 11: MT8-18.
- Siddique K, Ali Q, Mirza S, Jamil A, Ehsan A, Latif S, et al. Evaluation of the aetiological spectrum of obstructive jaundice. J Ayub Med Coll Abbottabad 2008; 20:62-6.
- Lerttumnongtum P, Muttarak M, Wasanavijit K. Clinics in Diagnostic Imaging. Singapore Medical Journal 2002; 43: 592-3.
- Megibow AJ. Pancreatic adenocarcinoma: designing the examination to evaluate the clinical questions. Radiology 1992; 183: 297-303.
- Schulte SJ, Baron RL, Teefey SA, et al. CT of the extrahepatic bile ducts: wall thickness and contrast enhancement in normal and abnormal ducts. AJR 1990; 154: 79-85.
- Sharma MP, Ahuja V. Aetiological spectrum of obstructive jaundice and diagnostic ability of ultrasonography: a clinician's perspective. Trop Gastroenterol 1999; 20: 167-9.
- Huang JQ, Bao XJ, Lu XH. The common causes and differential diagnosis of malignant jaundice. Zhonghua Nei Ke Za Zhi 1993; 32: 400-4.
- Martin DF, Laasch HU. The biliary tract. In: Grainger RG, Allison D eds. Grainger & Allison's Diagnostic Radiology-A textbook of medical imaging, 4th ed. Churchill Livingstone, Harcourt publishers limited, London: 2001.
- O'Connor KW. A blinded prospective study comparing four current noninvasive approaches in the differential diagnosis of medical versus surgical jaundice. Gastroenterology 1983; 84: 1498-504.
- Midwinter MJ, Beveridge CJ, Wilsdon JB, Bennett MK, Baudouin CJ, Charnley RM: Correlation between spiral computed tomography, endoscopic ultrasonography and findings at operation in pancreatic and ampullary tumors. Br J Surg 1999, 86: 189-193.

## **AUTHORS:**

- Akshaya Reddy Erasu
- Indira N.
- Ram Prakash H. V.

## **PARTICULARS OF CONTRIBUTORS:**

- Tutor, Department of Radio-diagnosis, Vydehi Institute of Medical Sciences & Research Centre, Bangalore.
- Professor, Department of Radio-diagnosis, Vydehi Institute of Medical Sciences & Research Centre, Bangalore.

- Professor & HOD, Department of Radio-diagnosis, Vydehi Institute of Medical Sciences & Research Centre, Bangalore.

## **NAME ADDRESS EMAIL ID OF THE CORRESPONDING AUTHOR:**

Dr. Indira N,  
# 1/2, 2066, 16<sup>th</sup> D Main,  
HAL, 2<sup>nd</sup> Stage, Bangalore-560008.  
E-mail: drakshayreddy@gmail.com  
drindiraniranjan@gmail.com

Date of Submission: 11/03/2015.  
Date of Peer Review: 12/03/2015.  
Date of Acceptance: 16/03/2015.  
Date of Publishing: 25/03/2015.