

VISUAL PROGNOSIS WITH THE VARIOUS MODALITIES OF TREATMENT AVAILABLE FOR NEOVASCULAR GLAUCOMA AT A TERTIARY LEVEL HOSPITAL

Nazima Bai A¹, K. Kanchana²

¹Associate Professor, Department of Ophthalmology, Government T. D. Medical College, Alappuzha.

²Former Professor, Department of Ophthalmology, Regional Institute of Ophthalmology, Government Medical College, Trivandrum.

ABSTRACT

BACKGROUND

Neovascular glaucoma (NVG) is a refractory type of glaucoma. In neovascular glaucoma elevation of IOP is caused by synechial angle closure through contraction of fibrovascular tissue. The symptoms of NVG are distressing, the visual loss severe and glaucoma intractable. Timely treatment with photocoagulation and Modified trabeculectomy and Artificial filtering shunts offers the patient a symptom-free life if not better vision. Intravitreal anti-VEGF cause rapid regression of iris and angle neovascularisation helping in the therapy of NVG.

MATERIALS AND METHODS

This is a descriptive study of the 66 cases of neovascular glaucoma attending a tertiary level hospital during the study period of 8 months. Treatments given included medical therapy, panretinal photocoagulation (PRP), injection Avastin, modified trabeculectomy, anterior retinal cryopexy (ARC) and cyclocryotherapy (CCT). The follow-up studies were done for a period of two to seven months in different cases.

RESULTS

Out of 66 cases two cases (2.9%) showed visual acuity improvement in the study. Both cases had undergone modified trabeculectomy with mitomycin C. One patient received preoperatively panretinal photocoagulation. Another patient received preoperatively panretinal photocoagulation and inj. bevacizumab. Both these cases have presented in the early stage of disease. Even though vision cannot be improved in majority of patients, the present modalities of treatment provide a painless eye without much of function.

CONCLUSION

The treatment should be based on the vision of the affected eye at the time of presentation and whether the angle is open or closed gonioscopically. Medical treatment was given for all patients for symptomatic relief. Majority had to undergo other modalities of treatment like panretinal photocoagulation (PRP), injection Avastin, modified trabeculectomy, and cyclocryotherapy (CCT).

KEYWORDS

Panretinal photocoagulation, Modified trabeculectomy, Intravitreal anti-VEGF, Artificial filtering shunts.

HOW TO CITE THIS ARTICLE: Bai NA, Kanchana K. Visual prognosis with the various modalities of treatment available for neovascular glaucoma at a tertiary level hospital. J. Evid. Based Med. Healthc. 2018; 5(25), 1908-1913. DOI: 10.18410/jebmh/2018/398

BACKGROUND

Neovascular glaucoma is an intractable condition of raised tension associated with new vessels on the iris, never occurs as a primary condition. The most widely accepted theory explaining the development of neovascularisation is that the hypoxic retina produces a diffusible angiogenic factor that stimulates new vessel proliferation. Other terminologies of neovascular glaucoma are haemorrhagic glaucoma,

congestive glaucoma, thrombotic glaucoma, hundred days glaucoma and rubeotic glaucoma.

Fundus fluorescein angiography (FFA) is an important investigation primarily to diagnose the posterior segment vascular aetiology which is the most common cause of NVG. A baseline FFA is important to document as well as follow-up of these cases to review the effects of various treatments either in the form of anti-VEGF agents or laser photocoagulation. Fluorescein gonioangiography has been used to identify NVI and NVA in diabetic retinopathy.¹ Other investigations include optical coherence tomography, ultrasound B scan, electrophysiological tests, infra-red pupillometry. General principles for treating patients with NVG include the identification of the underlying aetiology and the management of NVG is approached through the following 4 stages that reflect the progression of the disease: prophylactic treatment, early-stage treatment, advanced-

Financial or Other, Competing Interest: None.
Submission 02-03-2018, Peer Review 06-03-2018,
Acceptance 20-03-2018, Published 15-06-2018.
Corresponding Author:
 Dr. Nazima Bai A,
 Pooparambil House, Near Kochukada Bridge,
 Civil Station Ward, Alappuzha, Kerala – 688012.
 E-mail: drnazimabai@gmail.com
 DOI: 10.18410/jebmh/2018/398



stage treatment, and end-stage treatment. Advanced-stage treatment is characterized by synechial closure of the angle and secondary angle-closure glaucoma.

Anti-VEGF therapy (Anti-vascular endothelial growth factor) is frequently used for various conditions in which VEGF release is induced in response to retinal ischemia. It is still under study as an adjunct² or alternative treatment for NVG. Anti-VEGFs such as bevacizumab (Avastin), pegaptanib sodium (Macugen), and ranibizumab (Lucentis) block angiogenic factors that promote the formation of new vessels, reversing the neovascularisation process. The quantity of growth factors in the aqueous decrease after intraocular injection of anti-VEGFs, decreasing further progression of angular damage secondary to IOP increments.³ Several studies propose the use of anti-VEGF agents with traditional treatments such as PRP, with or without additional surgery and vary in the timing, combination, and place of injection (intracameral or intravitreal, or both simultaneously). The most frequent recommendation by various authors for treatment is the adjunct combination of intravitreal bevacizumab/panretinal photocoagulation for the treatment of NVG instead of PRP alone or as alternative treatment when visibility of the posterior segment is difficult due to opacities of the media (e.g. haemorrhage).⁴

With surgical care, ensure that adequate PRP is completed to reduce vasoproliferative stimulus. Surgical modalities include trabeculectomy with or without an anti-fibrotic agent and valve implant surgery. A retrospective cohort study from January 1994 to March 2007 of 101 eyes found that the prognostic factors for failure of trabeculectomy with MMC for NVG were younger age and previous vitrectomy in patients with NVG, having a fellow eye with NVG in patients with disease caused by diabetic retinopathy, and persistent proliferative membrane and/or retinal detachment after vitrectomy.⁵ Valve implant surgery is indicated when trabeculectomy fails or extensive conjunctival scarring exists, thereby preventing a standard filtering procedure. Molteno, Krupin, and Ahmed valve implants commonly are used. If combined with the need for vitrectomy, consideration of pars plana tube-shunt insertion may reduce anterior segment complications. Enucleation may be performed for intractable pain if other treatment modalities have failed to control the pain in a blind eye. The ultimate treatment of NVG would be to prevent the initiating event such as diabetic retinopathy or CRVO, or at least to prevent that event from progressing to Neovascular glaucoma, PRP and intravitreal anti-VEGF therapy can reduce this progression in part, but may not produce consistent results.

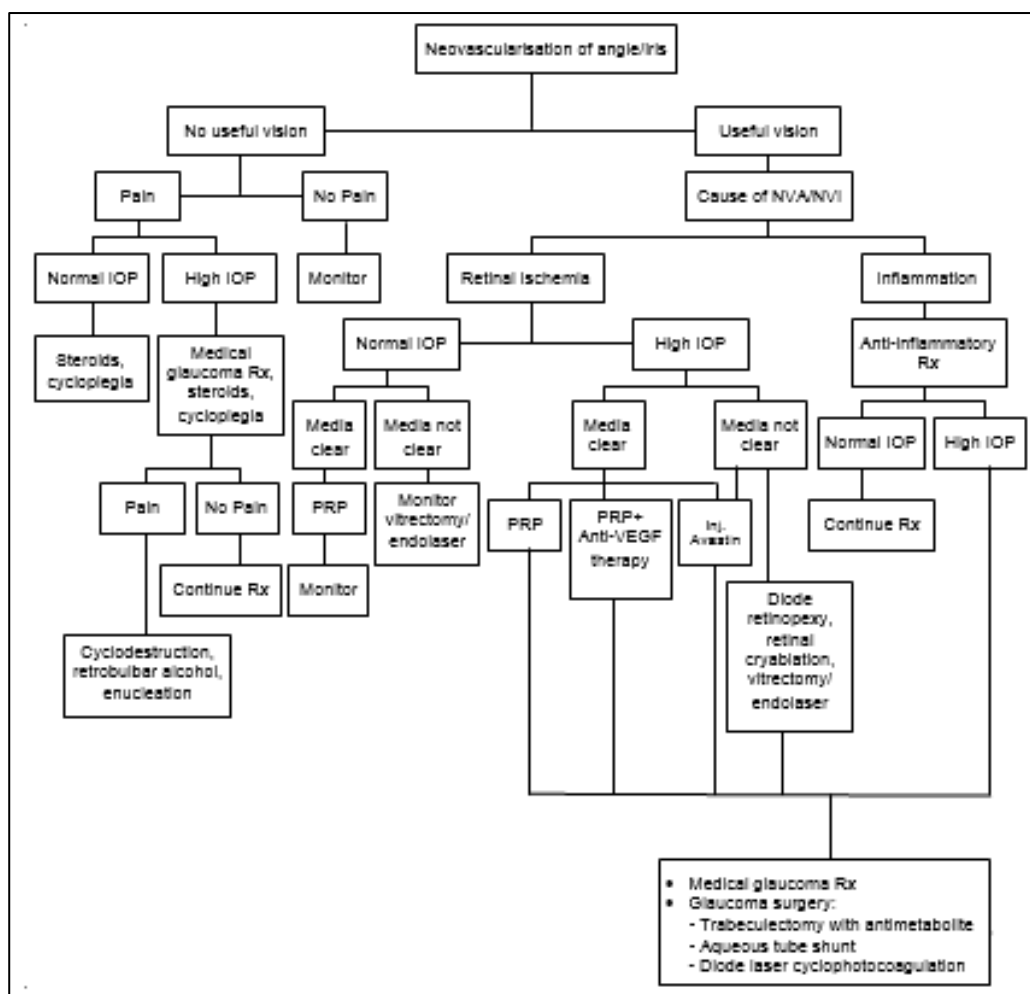


Figure 1. Treatment Algorithm for NVG

Aim of the Study

To evaluate the visual prognosis with the various modalities of treatment available for neovascular glaucoma in a tertiary level hospital.

MATERIALS AND METHODS

This is a descriptive study of 66 patients diagnosed to have neovascular glaucoma attending a tertiary level hospital in southern part of Kerala during the study period of 8 months, and those who had given the consent for participating in the study were analysed. Four patients had bilateral NVG, both eyes of those cases were included in the study. So, total of 70 eyes were studied.

Inclusion Criteria

All cases of neovascular glaucoma attended during the study period and those who had given the consent for participating in the study.

A detailed clinical examination of each case was carried out. A detailed general examination of the patient was conducted. Blood routine examination, urine routine examination, blood sugar and serum cholesterol were done. Both eyes were examined in detail with particular reference to vision, refraction, slit lamp, biomicroscopy, fundus examination, IOP and gonioscopy. B scan and field charting was done in relevant cases. A proforma has been prepared for this study and each case entered in it.

Different treatments given included medical therapy, panretinal photocoagulation (PRP), injection Avastin, modified trabeculectomy, anterior retinal cryopexy (ARC) and cyclocryotherapy (CCT). The prognosis regarding visual acuity improvement, subsidence of NVI, control of symptoms and IOP on follow-up was examined of each case. The prognosis of different modalities of treatment given for NVG was analysed. The follow-up studies were done for a period of two to seven months. Continued follow-up is required for the long-term success rate of PRP, injection Avastin and modified trabeculectomy.

RESULTS

Distribution based on Treatment Given

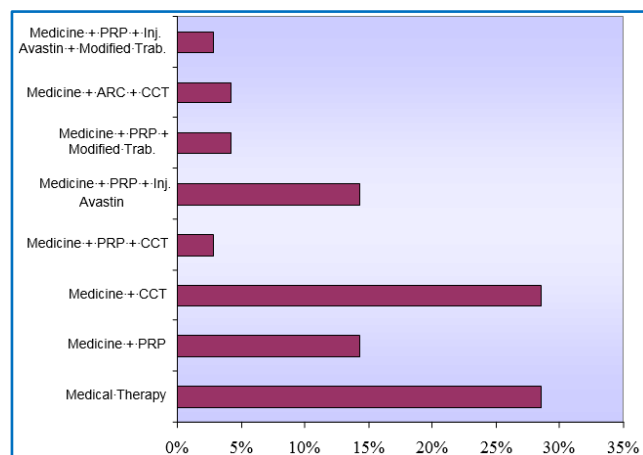


Figure 2. Distribution based on Treatment Given

Various treatment modalities given are shown in the above chart. Medical therapy alone was given to 28.6% of cases. Medical therapy with cyclocryotherapy was given for 28.6%. Other treatment modalities given along with medical therapy were PRP (14.3%); PRP + Inj. Avastin (14.3%); PRP + Modified trabeculectomy (4.3%); ARC + CCT (4.3%); PRP + Inj. Avastin + Modified trabeculectomy (2.9%) and PRP + CCT (2.9%).

Distribution based on Visual Acuity Improvement

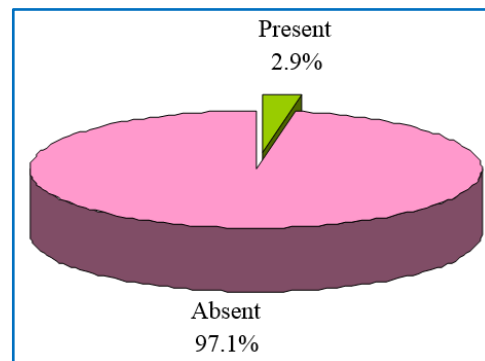


Figure 3. Distribution Based on Visual Acuity Improvement

In the present study, only 2.9% cases showed visual acuity improvement. Medicine + PRP + Inj. Avastin + Trabeculectomy resulted in maximum vision improvement. All other treatment modalities did not result in significant VA improvement.

Vision of Affected Eye vs. Treatment Given

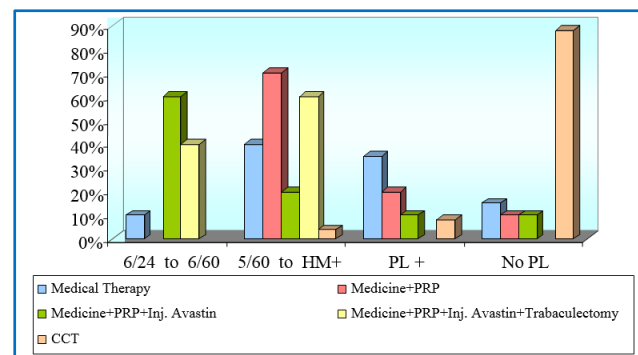
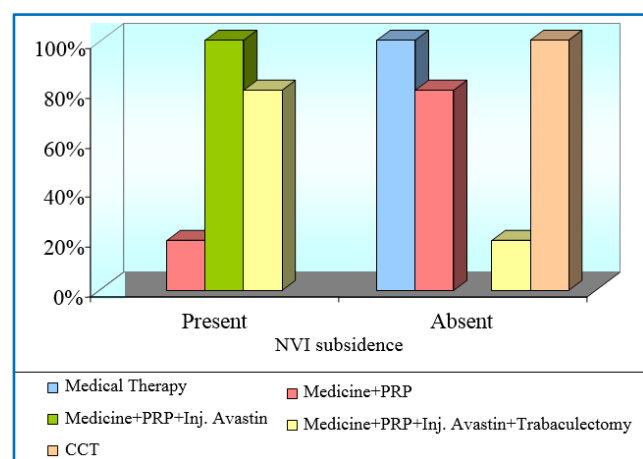


Figure 4. Vision of Affected Eye vs. Treatment Given

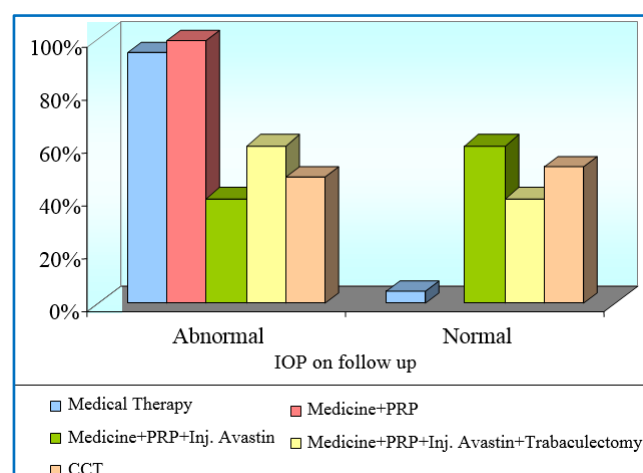
Chi-square: 66.686; $p < 0.001$

Treatment of the NVG forms an important aspect for retrieval of vision. On analysis of the present study, it was revealed that the vision of the affected eye was significantly ($p < 0.01$) associated with treatment given. Or the treatment should be based on the vision of the affected eye, which may result in better correction after treatment. Medical therapy has been given to almost all patients. Medicine + PRP was given to patients with 5/60 to HM vision. Similarly, Medicine + PRP + inj. Avastin + Trabeculectomy were administered to patients having better vision.

NVI Subsidence vs Treatment given**Figure 5. NVI Subsidence vs. Treatment Given**

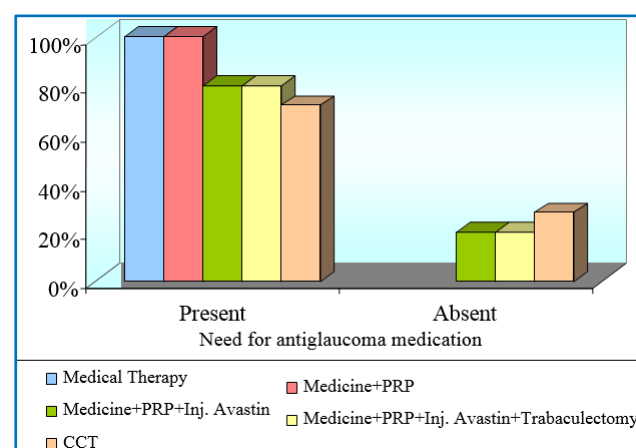
Chi-square: 56.389; $p < 0.001$.

Figure 5 shows the association between treatment and NVI subsidence. A significant ($p < 0.001$) association was found between treatment given and NVI subsidence. Medicine + PRP + Inj. Avastin resulted in 100% NVI subsidence. Similarly, 80% subsidence occurred in trabeculectomy group. Only 20% patients showed NVI subsidence who received only medicine and PRP.

IOP on follow-up vs. Treatment Given**Figure 6. IOP on Follow-up vs. Treatment Given**

Chi-square: 19.933; $p < 0.01$.

In the present study, treatment given was found associated significantly ($p < 0.01$) with IOP on follow-up. 95% of medical therapy received patients and 100% of the medicine and PRP received patients showed abnormal IOP on follow-up. But majority of patients that received other treatment modalities showed normal IOP on follow-up.

Need for Antiglaucoma Medication vs. Treatment Given**Figure 7. Need for Anti-glaucoma Medication vs. Treatment Given**

Chi-square: 9.240; $p > 0.05$.

Need for anti-glaucoma medications were present for majority of the patients under consideration who received different methods of treatment. But Inj. Avastin group, trabeculectomy group and CCT group registered few patients who did not need anti-glaucoma medications. The association between need for antiglaucoma medications and treatment given were not found to be significant.

DISCUSSION

Diabetic retinopathy is a leading cause of blindness in persons aged 20-74 years. 33-64% eyes with untreated PDR develop ocular neovascularisation. With improved treatment available for diabetes, life expectancy has been greatly increased resulting in many more individuals with diabetic retinopathy. Effective metabolic control of diabetes in the population, efficient screening for early detection and treatment of diabetic retinopathy and retinal photocoagulation of eyes with PDR are vital in prevention and management of neovascular glaucoma. Education of both patients and primary care providers can help to address the important challenge. Increased awareness of diabetic eye disease and the benefits of timely treatment coupled with convenient access to appropriate care can decrease the incidence of the devastating form of glaucoma.

These cases were treated with oral acetazolamide and in cases where IOP was very high IV mannitol was given to decrease intraocular pressure, topical beta blockers timolol 0.5% steroid and cycloplegic mydriatics like atropine 1% homatropine 2% or cyclopentolate 1%. It was possible to control tension and pain to a great extent with this treatment. Other anti-glaucoma medications used were topical beta blockers (eg. levobunolol (Betagan), topical brimonidine (Alphagan), topical carbonic anhydrase inhibitor (eg. dorzolamide (trusopt), Brinzolamide (Azopt)), and oral carbonic anhydrase inhibitor (eg. acetazolamide (Diamox)).

Medical treatment alone was given in 20 patients (28.6%) in the present study. And with medical treatment, control of symptom was achieved with continuing medical treatment. PRP was given in cases where media was clear and NVG was due to retinal ischemia. Medical therapy with PRP was given for 10 cases (14.3%) in the present study. 20% showed NVI subsidence. Visual acuity improvement was not seen. Control of symptom got in all cases. Further anti-glaucoma medication needed for all cases. Medical therapy with PRP and inj. Avastin were given for 10 cases (14.3%). Visual acuity improvement was not seen in the study. NVI subsidence was seen in all cases (100%). Control of symptoms was seen in all cases. In follow-up, IOP became normal in 6 cases (60%). Continued need for anti-glaucoma medication was required for all cases except two cases (20%) in which IOP was normal and did not require anti-glaucoma medication in two months follow-up period.

Continued follow-up is required for the long-term success rate as it is seen in the study by Gheith et al.⁶ that recurrence of new vessels occur after initial injection of avastin and in such cases repeated injection was required. Ehlers et al.⁴ study showed that combination therapy, i.e. combining intravitreal bevacizumab with panretinal photocoagulation resulted in more rapid decrease in IOP. In addition, the combination group had increased frequency and rapidity of regression of neovascularisation. Ghanem et al.⁷ reported intravitreal bevacizumab as an adjuvant treatment in cases of NVG. Ouhadj et al.⁸ observed that intravitreal injection of bevacizumab enabled the total regression of iris and angle neovascularisation but had only a partial action on intraocular hypertension. The present study also showed that intravitreal bevacizumab injection caused regression of iris neovascularisation in all cases but did not show parallel reduction in IOP in all cases.

Study by Ileiv et al.⁹ showed that complete regression of new vessels in the end of follow-up period (4 to 16 weeks) in 100% of eyes. Study of Oshima et al.¹⁰ also showed iris vessel regression following injection avastin. Study by Sonia et al.¹¹ showed rapid regression of iris and angle neovascularisation after a single intravitreal injection of bevacizumab which signifies its role as an adjunct in NVG management. Symptomatic relief in 100% of the study population and IOP control in 86.6% of subjects was maintained at 6 months follow-up. Assessment and follow-up of iris neovascularisation in the present study was depended on clinical examination only and not fluorescein angiography. Bevacizumab as a pharmacological treatment has the advantage of being rapid in effect but has the disadvantage of limited duration of action. Combining intravitreal bevacizumab injection with panretinal photocoagulation can offer both rapid and long-lasting effect. Another advantage of bevacizumab is the ability to use this modality of treatment in eyes with opaque media which preclude treatment with laser photocoagulation. Medical therapy with PRP and modified trabeculectomy with mitomycin C was done for 3 patients. In one case visual acuity improved by 1 line, i.e. 6/60 became 6/36. There was subsidence of neovascularisation. Control of symptom was

there. Follow-up IOP was 22 at the end of three months. Patient was continuing anti-glaucoma medication. Continued follow-up is required for long term assessment. Another two cases did not show visual acuity improvement or subsidence of neovascularisation. Control of symptoms was there. IOP was not brought back to normal and was continuing anti-glaucoma medication. According to Mandal et al.,¹² when useful vision exists filtering surgery has been an increasingly common means of achieving IOP control in NVG. A success rate of 67 to 100% has been reported using standard filtration technique with preoperative PRP. Early failure of filtering surgery is attributed to gradual scarring of the conjunctiva in the early post operation period. Studies have shown that intraoperative MMC may be superior alternative to post-operative 5FU. In the present study, intraoperative MMC was used. Medical therapy with PRP, injection avastin and modified trabeculectomy was done for two cases. One case showed improvement in visual acuity from 6/36 to 6/24. NVI subsidence was noted and control of symptoms was there on follow-up. IOP at the end of 3 months was 12. There was no need for anti-glaucoma medication at 3-month follow-up. Continued follow-up was required for long-term success rate. In the next case, there was no improvement of vision but there was subsidence of NVI and control of symptoms. IOP at two months follow-up was 18. Patient was kept on anti-glaucoma medication.

The present study is comparable with the study by Gheith et al.⁶ which showed that intravitreal bevacizumab may be a valuable addition in the treatment of NVG by hastening the resolution of anterior segment neovascularisation, improving the results of glaucoma surgeries and appear to give long term control when used in combination with PRP. 20 patients (28.6%) received medical therapy with cyclocryotherapy. None of the patients receiving cyclocryotherapy were able to maintain stable vision but cyclocryotherapy is an effective method to reduce IOP in advanced refractory glaucoma. The present study agrees with the studies conducted by Heuring et al.¹³ and Tung-Mei Kuang et al.¹⁴ Two cases were given medical therapy with PRP and CCT. Both patients had control of symptoms. There was no visual acuity improvement. One patient required anti-glaucoma medication, another did not require anti-glaucoma medication.

Three cases (4.3%) were given medical therapy along with ARC and CCT. Both patients had control of symptoms. One patient did not require anti-glaucoma medication. IOP became normal, other two had reduction in IOP but required anti-glaucoma medication on follow-up. In a study by Ma et al.,¹⁵ it was shown that ARC is suitable for treatment of NVG at early stage and ARC combined with trabeculectomy at later stage. Because our cases were hospitalized in tertiary care centre which reflected more refractory disease status, PRP with medical therapy alone rarely caused normalization of IOP. Reduction of IOP could be attained by increasing outflow through filtering surgery or by decreasing inflow via cyclocryotherapy.

Patients who are at high risk of developing NVG like patients with CRVO and PDR are to be followed up regularly so that treatment can be instituted at the earliest sign of development of iris neovascularisation. Even though vision cannot be improved in majority of patients, the present modalities of treatment provide a painless eye without much of function.

CONCLUSION

Oral acetazolamide along with topical medication was found to be useful in giving symptomatic relief and in controlling intraocular pressure for short period in most of the patients. Majority had to undergo other modalities of treatment to control the intraocular pressure. Cases which received inj. bevacizumab (Inj. Avastin) showed subsidence of neovascularisation of iris (100%) in all cases but parallel reduction in intraocular pressure was not seen in all cases in a short period of follow-up. Two cases (2.9%) showed visual acuity improvement in the study. Both cases had undergone modified trabeculectomy with mitomycin C. One patient received preoperatively panretinal photocoagulation. Another patient received preoperatively panretinal photocoagulation and inj. bevacizumab. Both these cases have presented in the early stage of disease. All other cases in the study did not show visual acuity improvement with treatment. Cyclocryotherapy was the treatment given in patients who had no vision at the time of presentation. It gave good control of intraocular pressure and pain in advanced neovascular glaucoma cases. Majority of patients required anti-glaucoma medication on follow-up. This study shows that once patient develop neovascular glaucoma, the chance of regaining useful vision is poor.

REFERENCES

- [1] Ohnishi Y, Ishibashi T, Sagawa T. Fluorescein gonioangiography in diabetic neovascularisation. *Graefes Arch Clin Exp Ophthalmol* 1994;232(4):199-204.
- [2] Hasanreisoglu M, Weinberger D, Mimouni K, et al. Intravitreal bevacizumab as an adjunct treatment for neovascular glaucoma. *Eur J Ophthalmol* 2009;19(4):607-612.
- [3] Simha A, Braganza A, Abraham L, et al. Anti-vascular endothelial growth factor for neovascular glaucoma. *Cochrane Database Syst Rev* 2009;(10):CD007920.
- [4] Ehlers JP, Spirn MJ, Lam A, et al. Combination intravitreal bevacizumab/panretinal photocoagulation versus panretinal photocoagulation alone in the treatment of neovascular glaucoma. *Retina* 2008;28(5):696-702.
- [5] Takihara Y, Inatani M, Fukushima M, et al. Trabeculectomy with mitomycin C for neovascular glaucoma: prognostic factors for surgical failure. *Am J Ophthalmol* 2009;147(5):912-918.
- [6] Gheith ME, Siam GA, De Barros DSM, et al. Role of intravitreal bevacizumab in neovascular glaucoma. *Journal of Ocular Pharmacology and Therapeutics* 2007;23(5):487-491.
- [7] Ghanem AA, El-Kannishy AM, El-Wehidy AS, et al. Intravitreal bevacizumab (avastin) as an adjuvant treatment in cases of neovascular glaucoma. *Middle East Afr J Ophthalmol* 2009;16(2):75-79.
- [8] Ouhadj O, Chergui I, Mendil L, et al. Intravitreal bevacizumab in the treatment of neovascular glaucoma. *J Fr Ophtalmol* 2009;32(2):112-116.
- [9] Iliev ME, Domig D, Wolf-Schnurrbusch U, et al. Intravitreal bevacizumab (avastin) in the treatment of neovascular glaucoma. *Am J Ophthalmol* 2006;142(6):1054-1056.
- [10] Oshima Y, Sakaguchi H, Gomi F, et al. Regression of iris neovascularization after intravitreal injection of bevacizumab in patients with proliferative diabetic retinopathy. *Am J Ophthalmol* 2006;142(1):155-158.
- [11] Sonia RJ, Chakrabarti M, Chakrabarti A, et al. Intravitreal bevacizumab (IVB) in the management of recalcitrant neovascular glaucoma (NVG). *Kerala J Ophthalmol* 2008;20(1):33-38.
- [12] Mandal AK, Majji AB, Mandal SP, et al. Mitomycin-C-augmented trabeculectomy for neovascular glaucoma. A preliminary report. *Indian J Ophthalmol* 2002;50(4):287-293.
- [13] Heuring AH, Hutz WW, Hoffmann PC, et al. Cyclocryotherapy in neovascular glaucoma and non-neovascular glaucoma. *Klin Monbl Augenheilkd* 1998;213(4):213-219.
- [14] Kuang TM, Liu CJ, Chou CK, et al. Clinical experience in the management of neovascular glaucoma. *J Chin Med Assoc* 2004;67(3):131-135.
- [15] Ma L, Zhao B, Di Y. Treatment of neovascular glaucoma by anterior retinal cryotherapy and trabeculectomy. *Zhonghua Yan Ke Za Zhi* 1996;32(2):118-122.