

## VISUAL OUTCOME POST RETINAL LASER PHOTOCOAGULATION IN PATIENTS WITH DIABETIC RETINOPATHY

Vrunda Gangadhar Morepatil<sup>1</sup>, Omkar Jagdish Telang<sup>2</sup>

<sup>1</sup>Lecturer, Department of Ophthalmology, K.J. Somaiya Medical College, Sion, Mumbai.

<sup>2</sup>Associate Professor, Department of Ophthalmology, K.J. Somaiya Medical College, Sion, Mumbai.

### ABSTRACT

#### BACKGROUND

Diabetes Mellitus (DM) is a global epidemic with significant morbidity. Diabetic Retinopathy (DR) is the specific microvascular complication of DM and affects 1 in 3 persons with DM. DR remain a leading cause of vision loss in working adult populations. Patients with severe levels of DR are reported to have poorer quality of life and reduced levels of physical, emotional and social wellbeing and they utilise more healthcare resources.

The aim of the study is to determine the visual outcome of laser treatment in diabetic retinopathy patients.

#### MATERIALS AND METHODS

A total of 100 eyes of 60 patients with diabetic retinopathy in different stages were subjected to retinal laser photocoagulation using double frequency Nd:YAG laser. Focal laser was used in 9 eyes, panretinal photocoagulation was done in 55 eyes, grid and panretinal photocoagulation was done in 32 eyes and grid and focal laser was done in 2 eyes. The best corrected visual acuity was noted and fundus examination was carried out prior to photocoagulation and at follow up visits. At last follow up, results were assessed.

Design- Prospective, non-comparative study.

#### RESULTS

Nonproliferative diabetic retinopathy was present in 82 eyes. Following laser treatment, best corrected visual acuity improved in 17%, remained static in 81% and deteriorated in 2%. Maculopathy improved in 11%, remained static in 89%. After laser BCVA in PDR improved in 6% and remained unchanged in 94%. In male patients following laser BCVA improved in 11%, remained static in 87% and in females BCVA improved in 23% and remained static in 74%.

#### CONCLUSION

Our study concludes that retinal laser photocoagulation plays an important role in stabilisation of vision in patients with diabetic retinopathy. There was no gender or age-related bias in the results of study. HbA1c value has no predictive role in visual outcome post retinal laser photocoagulation.

#### KEYWORDS

Retinal Photocoagulation, Visual Outcome, Diabetic Retinopathy, Maculopathy.

**HOW TO CITE THIS ARTICLE:** Morepatil VG, Telang OJ. Visual outcome post retinal laser photocoagulation in patients with diabetic retinopathy. J. Evid. Based Med. Healthc. 2017; 4(78), 4627-4632. DOI: 10.18410/jebmh/2017/924

#### BACKGROUND

Approximately, 150 million people are estimated to have diabetes throughout the world.<sup>1</sup> Diabetes is an 'iceberg' disease. Although, increase in both prevalence and incidence of type 2 diabetes have occurred globally, they have been especially dramatic in societies in economic transition, in newly industrialised countries and in developing countries. Estimated 20% of current global diabetic population resides in south-east Asia region.<sup>2</sup>

Diabetic retinopathy is the third most important cause for visual impairment.<sup>3</sup> There are approximately 93 million people with DR, 17 million with proliferative DR, 21 million with diabetic macular oedema and 28 million with VTDR worldwide. Longer diabetes duration and poorer glycaemic and blood pressure control are strongly associated with DR. These data highlight the substantial worldwide public health burden of DR and the importance of modifiable risk factors in its occurrence.<sup>4</sup>

The severity of retinopathy in diabetics generally parallels the duration of disease and the adequacy of its control, but not the severity of the disease. The incidence of diabetic retinopathy is more with Insulin-Dependent Diabetes Mellitus (IDDM) than with Non-Insulin-Dependent Diabetes Mellitus (NIDDM), but the severity of maculopathy is known to be more with NIDDM. The course and severity of diabetic retinopathy are affected by factors such as presence of nephropathy, systemic hypertension, pregnancy and positive family history of diabetic retinopathy.

*Financial or Other, Competing Interest: None.*

*Submission 01-09-2017, Peer Review 06-09-2017,*

*Acceptance 21-09-2017, Published 28-09-2017.*

*Corresponding Author:*

*Dr. Omkar Jagdish Telang,*

*Associate Professor, Department of Ophthalmology,*

*K.J. Somaiya Medical College,*

*Sion, Mumbai.*

*E-mail: omkartelang@hotmail.com*

*DOI: 10.18410/jebmh/2017/924*



Diabetic retinopathy is one of the few ophthalmic diseases that have a defined preventive measure to delay progression of the disease and consequent visual loss. The estimated high prevalence of diabetes by 2025 in India<sup>5</sup> is a matter of concern considering the potential for vision loss associated with diabetic retinopathy.<sup>6</sup>

Currently, retinal photocoagulation remains an effective means of controlling the progression of diabetic retinopathy, maculopathy and macular oedema. Today, laser photocoagulation systems offer a diverse flexible platform to treat diabetic retinopathy and other diabetic disorders. Several photocoagulation systems incorporate multiple lasers and multiple wavelengths allowing ophthalmologists to switch easily back and forth to tailor treatment for each patient.

In this hospital-based randomised prospective study, 100 eyes of 60 patients of diabetic retinopathy were subjected to laser retinal photocoagulation and its effect in terms of visual outcome was assessed. Some factors such as age, sex, duration of diabetes mellitus, stage of retinopathy and HbA1c value were studied as predictors of visual outcome in these patients post laser photocoagulation.

**Aim-** Visual outcome in patients with diabetic retinopathy post retinal laser photocoagulation.

#### **Objectives-**

1. To assess the visual outcome post retinal photocoagulation in patients with diabetic retinopathy in 100 eyes of western Indian population.
2. To assess the role of levels of glycosylated haemoglobin as predictor of visual outcome post retinal laser photocoagulation.
3. To assess improvement or deterioration over 6 weeks period (1 week, 3 weeks and 6 weeks follow up).
4. To study visual outcome in patients under subgroups such as baseline vision (<6/60-6/60, 6/36-6/18 and 6/12-6/6), type of diabetic retinopathy (ETDRS classification), type of retinal photocoagulation (focal, grid, panretinal and combination).

To assess if gender and age-related bias exists in visual outcome post retinal photocoagulation.

#### **MATERIALS AND METHODS**

Subject pool of 60 patients (100 eyes), known cases of diabetes mellitus willing to undergo laser therapy over a period of 2 years at our institute.

Prospective study evaluating visual improvement involving 3 visits post laser at 1 week, 3 weeks and 6 weeks recorded with help of Snellen's chart (best corrected visual acuity) post laser therapy.

**Laser Details-** Quantel medical-Vitra, laser class 4, Nd-YAG laser-532 nm, 1.2 Wmax, Diode laser-650 nm, <1m Wmax.

**Fundus Picture-** Topcon TRC. 50 retinal camera teleconverter TC 201.

#### **Inclusion Criteria**

- Known cases of diabetes mellitus type 2.
- Age group 30-70 years.
- Controlled blood sugar levels.
- Patients selected irrespective of sex.

#### **Exclusion Criteria**

- Patient with hazy media or any other factors affecting the visual improvement, e.g. glaucoma, high refractive errors, mature cataract and uveitis.
- Patients with corneal pathologies.
- Patients (females) who are pregnant.
- Patients who have undergone same or similar procedures (retinal laser) in past.
- Patients whose current blood glucose levels are uncontrolled.
- Patients undergone vitrectomy/intravitreal injections.
- Juvenile diabetes.

#### **Method of Collection of Data-**

A prospective study was undertaken over a period of two years. All patients diagnosed as diabetic on the basis of blood sugar levels were included.

Patients' age, gender, duration of diabetes mellitus, age at onset of diabetes mellitus, presence or absence of hypertension, use of insulin or oral hypoglycaemic agents, presence of other systemic diabetic complications and other general illnesses were noted.

A detailed clinical examination of both the eyes was done by various methods for diagnosis of diabetic retinopathy.

#### **Ocular Parameters at Baseline were Noted-**

1. Visual Acuity (VA) by Snellen's chart.
2. Best-Corrected Visual Acuity (BCVA) noted by refraction using skiascopy and streak retinoscope.
3. Slit-lamp biomicroscopic examination was done. Density of cataract was graded from 0-6, nuclear sclerosis was graded from +1 (mild) to +4 (very dense) cortical and posterior subcapsular cataract were each given an additional score of +1.
4. IOP by applanation tonometer.
5. Fundus examination using direct ophthalmoscopy, indirect ophthalmoscopy, slit-lamp biomicroscopy with plus 78D or plus 90D lens.
6. Stereo colour fundus photographs performed with Topcon TRC 50 retinal camera teleconverter TC 201. The photograph included pictures of the macula, disc and superotemporal and inferior temporal quadrants. Photographs were coded and assessed. The photographs are graded using modified version of ETDRS grading system.
7. Fundus Fluorescein Angiography (FFA).

#### **Clinical and Biochemical Parameters-**

1. Fasting and two-hour plasma glucose level.
2. Complete blood count.
3. Lipid profile.
4. Serum creatinine.

5. Glycosylated haemoglobin.
6. Urine analysis.
7. Blood pressure measurement using sphygmomanometer.

**Procedure-** After informed consent, adequate pupillary dilatation was achieved and the patient was seated in front of laser machine. Eye was anaesthetised with 2% lidocaine hydrochloride.

Photocoagulation was performed using Quantel Medical-Vitra, laser class 4, Nd-YAG laser-532 nm, 1.2 Wmax, slit-lamp or indirect ophthalmoscope laser delivery was used.

**Parameters for Focal Treatment include-<sup>7</sup>**

- 50 to 100 µm spot size.
- 0.1 seconds or less duration.
- Attempt to whiten or darken microaneurysms.

**Parameters for Local Treatment in a Grid Pattern Include-<sup>7</sup>**

- 50 to 100 µm spot size.
- 0.1 seconds or less duration.
- Spots spaced at least 1 burn width apart.

**Parameter for PRP**

- 200-500 µm spot size.
- 0.1 seconds or less duration.
- Spots spaced at least 1 burn width apart.

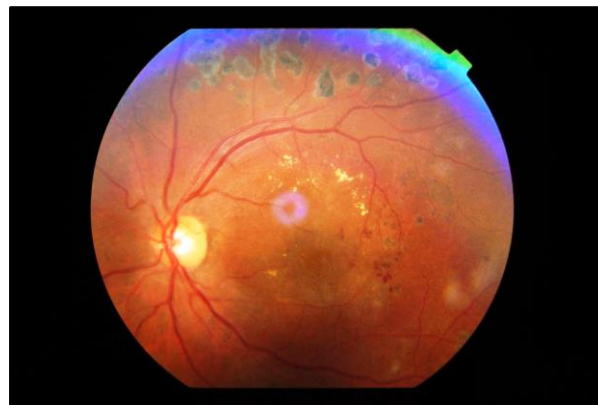The laser was used on the area 500-3000 µm from the macular center at the thickened retina showing capillary blood vessel occlusion and considered to be the origin of the leakage in the focal, diffuse leakage areas as shown by fundus fluorescein angiography. In other words, the area showing initial hyperfluorescence was photocoagulated with laser. Baseline and follow-up examination was performed at 1 week, 3 weeks and 6 weeks after treatment using the Snellen’s chart.

**Ocular Parameters Noted at Followup Visits-**

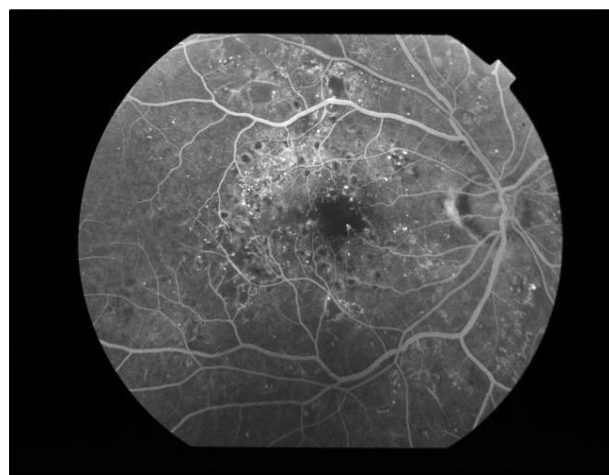
1. Visual Acuity (VA) by Snellen’s chart.
2. Best Corrected Visual Acuity (BCVA) noted by refraction using skiascopy, streak retinoscope.
3. Slit-lamp biomicroscopic examination was done. Density of cataract was graded from 0-6, nuclear sclerosis was graded from +1 (mild) to +4 (very dense) cortical and posterior subcapsular cataract were each given an additional score of +1.
4. IOP by applanation tonometer.
5. Fundus examination using direct ophthalmoscopy, indirect ophthalmoscopy, slit-lamp biomicroscopy with plus 78D or plus 90D lens.

**Frequency Doubled Nd:YAG Laser**

The frequency doubled Nd:YAG laser emit 532 nm radiation. This is achieved by passing 1064 nm radiation from YAG crystal through a Potassium-Titanyl-Phosphate (KTP) crystal, thereby converting some energy to 532 nm radiation. The YAG crystal maybe pumped by arc light or by a diode laser. Photocoagulation effect is similar to that of continuous wave argon green laser.



**Figure 1. Retina Post Laser Photocoagulation**



**Figure 2. FFA - Post Retinal Laser Photocoagulation**

**Observations and Results**

In our study, 100 eyes of 60 patients at different stages of diabetic retinopathy were subjected to retinal photocoagulation.

Sex	Duration ≤5	6 to 10 Yrs.	11 to 15 Yrs.	>15 Yrs.
Male	11.8%	44.1%	44.1%	0.0%
Female	3.8%	69.2%	23.1%	3.8%
<b>Total</b>	<b>8.3%</b>	<b>55.0%</b>	<b>35.0%</b>	<b>1.7%</b>

**Table 1. Distribution of Study Group as per Duration of Diabetes and Sex**

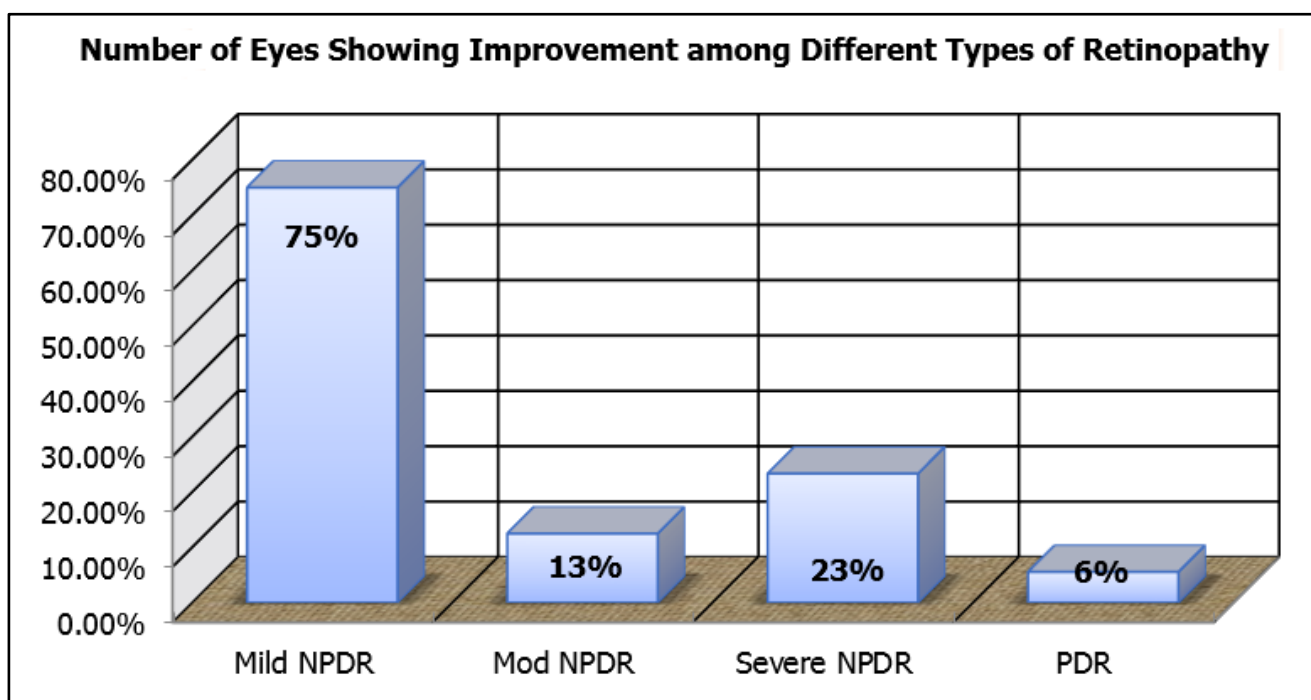
Duration (yrs.)	Total Eyes Treated with Laser	Outcome at 6 Wks.		
		Improvement (at 6 wks.)	Static	Worsened
≤5	7	2	5	0
6 to 15	91	13	76	2
≥16	2	2	0	0
<b>Total</b>	<b>100</b>	<b>17</b>	<b>81</b>	<b>2</b>

*Table 2. Comparison of Visual Outcome as per Duration of Diabetes*

Type of Retinopathy	Total Eyes Treated with Laser	Outcome at 6 Wks.		
		Improvement (at 6 wks.)	Static	Worsened
Mild NPDR	4	3	1	0
Mod NPDR	48	6	40	2
Severe NPDR	30	7	23	0
PDR	18	1	17	0
<b>Total</b>	<b>100</b>	<b>17</b>	<b>81</b>	<b>2</b>

*Table 3. Comparison of Visual Outcome Among Different Types of Retinopathy*

Chi-Square Test	Value	df	P value	Association
Pearson Chi-square	14.800	6	0.0219	Significant



*Figure 3. Number of Eyes Showing Improvement among Different Types of Retinopathy*

75% of patients in the mild NPDR group showed improvement in best corrected visual acuity. In all the other groups, viz. moderate NPDR, severe NPDR and PDR, more than 75% of patients showed no change in visual acuity.

Correlation of baseline visual acuity and visual outcome post retinal laser photocoagulation is as follows.

Baseline Visual Acuity	Total Eyes Treated with Laser	Outcome at 6 Wks.		
		Improvement	Static	Worsened
Gr. 1 (≤6/60)	57	5	52	0
Gr. 2 (6/36, 6/24, 6/18)	39	12	26	1
Gr. 3 (6/12, 6/9, 6/6)	4	0	3	1
<b>Total</b>	<b>100</b>	<b>17</b>	<b>81</b>	<b>2</b>

*Table 4. Comparison of Visual Outcome as per Basline Visual Acuity*

Type	Total Eyes Treated with Laser	Outcome at 6 Wks.		
		Improvement	Static	Worsened
Maculopathy	37	4	33	0
No maculopathy	63	13	48	2
<b>Total</b>	<b>100</b>	<b>17</b>	<b>81</b>	<b>2</b>

*Table 5. Comparison of Visual Outcome in Patients with and with Maculopathy*

HbA1c	Total Eyes Treated with Laser	Outcome at 6 Wks.		
		Improvement	Static	Worsened
≤7.0	33	5	27	1
>7.0	67	12	54	1
<b>Total</b>	<b>100</b>	<b>17</b>	<b>81</b>	<b>2</b>

**Table 6. Comparison of Visual Outcome as per HbA1c Value**

**DISCUSSION**

With changing lifestyle and more urbanisation, diseases like diabetes and hypertension have become more common leading to a greater prevalence of diabetes and hypertensive retinopathy.

The purpose of our study was to examine 60 patients - 100 eyes of diabetic retinopathy and to find out visual outcome after laser photocoagulation in them. In present study, 60 diabetic patients were analysed in which all 60 patients belonged to type 2 diabetes mellitus.

The study population consisted of 56.7% males and 43.3% females. The age range was from 39 to 78 years with mean age of 61.47 years and SD of ±6.378 years (males) and mean age of 58.81 years and SD of ±6.824 years (females).

The maximum incidence of diabetic retinopathy requiring laser therapy was found in the age group of 55 to 68 years. Duration of diabetes was between age range of 5 to 25 years with mean 9.85 years and SD of ±3.421 years (males) and mean 9.73 years and SD ±3.955 years (females).

Laser was performed on 100 eyes of 60 patients with visual acuity range between 6/6 and PL +, PR acc. Follow up examination was performed after 1 week, 3 weeks and 6 weeks period following laser retinal photocoagulation. Following laser treatment, BCVA improved in 17% of total eyes undergoing laser retinal photocoagulation, remained unchanged in 81% and deteriorated in 2% of eyes (≥2 Snellen’s line improvement/deterioration).

Improvement in visual outcome (17%) is statistically not significant and does not agree with the studies done by others, which includes a study done by Shrestha S, Karki DB, Byanju et al (2007),<sup>8</sup> which found that following laser treatment, BCVA improved in 52.50%, remained static in 35% and deteriorated in 12.5% of patients after one year follow up. The post treatment visual acuity was significant (p=0.038) in their study.

Following laser therapy in patients with maculopathy, BCVA improved in 10.81%, unchanged in 89.19% and deteriorated in 0% of patients (≥2 Snellen’s line improvement/deterioration). In a study done by Keshav B.R. et al., more than 50% had stabilisation of visual acuity and more than 25% had improvement in visual acuity after laser for CSME.<sup>9</sup> However, a study done by Toke Bek, Flemming Moller and Boilel Khalusen<sup>10</sup> in 2000 concluded that an average visual acuity was unchanged 3 months after laser photocoagulation for diabetic maculopathy with change in BCVA range between -0.44 to 0.33 (mean -0.04).

Following laser retinal photocoagulation therapy in severe NPDR, 23.33% of the eyes showed improvement, 76.67% remain unchanged and 0% deteriorated (≥2 Snellen’s line improvement/deterioration), while in PDR, 5.56% of eyes showed improvement, 94.44% remain

unchanged and 0% deteriorated (≥2 Snellen’s line improvement/deterioration). This is not in accordance with the study done by Dr Y.K. Dastur (1994).<sup>11</sup>

In our study, 28.57% of eyes improved in patients with <5 years duration, 12.73% eyes improved in 6 to 10 years duration, 19.44% eyes improved in 11 to 15 years duration, whereas 100% of eyes improved in >16 years duration. 2% of eyes deteriorated in patients with duration of diabetes within 6-15 years.

The comparison between duration of diabetes and BCVA after laser therapy was found statistically significant (p 0.02636). It shows the inverse relationship between the duration of diabetes and the visual outcome after laser. This is in accordance with the study done by Mohan Rema et al and some others.<sup>12</sup>

In our study, the eyes with baseline visual acuity from 6/36 to 6/18, which lies in the mid-range of visual acuity showed the most improvement post laser therapy. In this group, 30.77% showed improvement, while 66.67% eyes showed no change. On either side of this, on the visual acuity scale, viz. those in the group of baseline visual acuity <6/60 and in the group of baseline visual acuity from 6/12 to 6/6, most eyes showed stabilisation of vision rather than improvement. In the group of <6/60, 91.23% eyes did not show any change as compared to improvement seen in 1.75% patients and in the group from 6/12 to 6/6, 75% patients showed no change, whereas 1 eye showed deterioration.

The level of control of blood sugar as measured by HbA1c value (≤7.0 or >7.0) may have an effect on haemodynamic and thus retinal capillary permeability, so we tried to find a correlation between the two groups. In our study, the two groups did not show any difference as far as outcomes of laser therapy were concerned.

On comparison of visual outcome as per gender, among this study group, in males, 11.32% improved, while 86.79% remained static and females showed slightly better results, i.e. 23.4% improved, while 74.46% maintained their pre-laser vision.

Visual outcome was also assessed according to the age groups of the participants and maximum improvement was noted in individuals less than 55 yrs. of age (30.43%), while 65.21% showed no change in visual acuity. In other groups such as 55-65 yrs., 90% of patients showed stabilisation of vision as compared to 70% in the group of 66 yrs. and above.

**Summary**

The results of presented collection of 60 patients 100 eyes shows a favourable influence of photocoagulation on the preservation rather than improvement from baseline visual acuity.

Timely focal and grid laser photocoagulation helps in stabilising the visual acuity in patients with diabetic retinopathy with or without macular oedema.

Contrary to popular belief that PRP is associated with worsening of macular oedema, we found that PRP + grid laser done for co-existent PDR and severe NPDR did not lead to worsening of treatment outcome. PRP done in NPDR/PDR patients associated with diabetic maculopathy has beneficial effects in stabilising the visual acuity and reducing diabetic macular oedema.

Laser photocoagulation done in severe NPDR patients approaching high-risk characteristics PDR helps in stabilising the visual acuity and prevents vision-threatening complications.

Duration of diabetes and HbA1C values have shown no correlation with the visual outcome following retinal laser photocoagulation in any stage of diabetic retinopathy, thereby showing no significant effect on prognosis.

There was no obvious gender and age bias seen in the visual outcomes of patients in our study group. More than two thirds of patients in both groups (males and females) showed stabilisation of vision. Patients less than 55 years of age showed slightly better results as per improvement in visual outcome when compared with the results of more than 55 years age group.

Worsening of visual acuity post laser in few patients could be attributed to natural progression of the disease course or complication of laser.

## CONCLUSION

Recent studies have demonstrated a possible beneficial effect in terms of visual outcome if retinal photocoagulation is coupled with intravitreal steroids and/or anti-VEGFS injections, however, this was beyond the scope of our study. Further research in this field may offer better prospects of visual improvement for patients with diabetic retinopathy.

## REFERENCES

- [1] WHO: Technical Report Series, No. 916. Diet, nutrition and the prevention of chronic diseases. Geneva: WHO 2003.
- [2] WHO: Health Situation in South-East Asia Region 1994-1997, Regional Office for SEAR, New Delhi 1999.
- [3] Munoz B, West SK, Rubin GS, et al. Causes of blindness and visual impairment in a population of older Americans: The Salisbury Eye Evaluation Study. *Arch Ophthalmol* 2000;118(6):819-825.
- [4] Yau JW, Rogers SL, Kawasaki R, et al. Global prevalence and major risk factors of diabetic retinopathy. *Diabetes Care* 2012;35(3):556-564.
- [5] Meyer-Schwickerath G. Development of photocoagulation. In: March WF, ed. *Ophthalmic lasers: a second generation*. Thorofare: Slack 1990:13-19.
- [6] King H, Aubert RE, Herman WH. Global burden of diabetes, 1995-2025: prevalence, numerical estimates, and projections. *Diabetes Care* 1998;21(9):1414-1431.
- [7] Folk JC, Pulido JS. *Laser photocoagulation of the retina and choroid*. San Francisco, California: American Academy of Ophthalmology 1997.
- [8] Shrestha S, Karki DB, Byanju R, et al. Visual outcome of laser treatment in diabetic retinopathy. *Kathmandu Univ Med J* 2007;5(1):72-80.
- [9] Keshav BR, Zacharia G, Bhat VK, et al. Laser therapy in diabetic macular edema. *Oman Med J* 2008;23(1):28-31.
- [10] Bek T, Moller F, Klausen B. Short term visual prognosis after retinal laser photocoagulation for diabetic maculopathy. *Acta Ophthalmol Scand* 2000;78(5):539-542.
- [11] Dastur YK. The rationale of argon green laser photocoagulation for diabetic maculopathy. *J Postgrad Med* 1994;40(1):13-17.
- [12] Rema M, Sujatha P, Pradeepa R. Visual outcomes of pan-retinal photocoagulation in diabetic retinopathy at one-year follow-up and associated risk factors. *Indian J Ophthalmol* 2005;53(2):93-99.