

Variations in the Branching Pattern of External Carotid Artery in South Kerala Population – A Cadaveric Study

Manju Sudhakaran¹, Mini Alikunju², Vandana Latha Raveendran³, Umesan Kannanvilakom Govindapillai⁴

^{1, 2, 3, 4} Department of Anatomy, Government medical college, Thiruvananthapuram, Kerala, India.

ABSTRACT

BACKGROUND

External carotid arteries account for a major share of arterial supply of head and neck regions. As variations are frequently observed in the branching pattern of external carotid artery, surgeons, radiologists and anaesthetists often encounter difficulties in various procedures of head and neck. The purpose of this study is to describe the variations in the branching pattern of external carotid artery as observed in South Indian population which definitely reduces its iatrogenic injuries associated with surgical and radiological procedures of head and neck.

METHODS

This is cross-sectional descriptive study. Bilateral neck dissection was done on twenty-two formalin fixed cadavers to study the branching pattern of external carotid artery during a period of two years in the Department of Anatomy in Government Medical College, Alappuzha. Common carotid, external carotid and internal carotid arteries were dissected. All the branches of external carotid artery were traced and the variations were noted. The distance between carotid bifurcation and point of origin of individual branches of external carotid were measured and statistically analyzed.

RESULTS

In the present study along with normal branching pattern of external carotid artery, variations like origin of superior thyroid artery from common carotid artery and also from carotid bifurcation were seen. A common linguofacial trunk and direct origin of superior laryngeal artery from external carotid artery were also observed.

CONCLUSIONS

Prior knowledge of the variations will be helpful to surgeons and anaesthetists while dealing with these vessels during procedures of head and neck regions.

KEYWORDS

External Carotid Artery, Carotid Bifurcation, Superior Thyroid Artery, Linguofacial Trunk

Corresponding Author:

*Dr. Vandana Latha Raveendran,
Assistant Professor,
Department of Anatomy,
Government Medical College,
Thiruvananthapuram, Kerala, India.
E-mail: drvandanalr@gmail.com*

DOI: 10.18410/jebmh/2021/336

How to Cite This Article:

Sudhakaran M, Alikunju M, Raveendran VL, et al. Variations in the branching pattern of external carotid artery in south Kerala population – a cadaveric study. J Evid Based Med Healthc 2021;8(22):1780-1785. DOI: 10.18410/jebmh/2021/336

*Submission 11-02-2021,
Peer Review 21-02-2021,
Acceptance 14-04-2021,
Published 31-05-2021.*

Copyright © 2021 Manju Sudhakaran et al. This is an open access article distributed under Creative Commons Attribution License [Attribution 4.0 International (CC BY 4.0)]

BACKGROUND

Neck is surgically more vulnerable for iatrogenic injuries as muscles, vessels, glands and nerves are crowded together compared to many other parts of the body where these structures are arranged in a less crowded manner. Two common carotid arteries (CCA) which are present on either side of neck in the anterior triangle, through their branches supply all the structures in the head, neck and brain region. CCA along with internal jugular vein (IJV) and vagus nerve are seen enclosed by a sheath known as carotid sheath which is derived from deep cervical fascia. Right CCA arises from brachiocephalic trunk while left CCA originates as a direct branch of arch of aorta. It ascends to the back of sternoclavicular joint and enters the neck. Then it runs upwards from sternoclavicular joint to the level of upper border of intervertebral disc between C3 and C4 vertebra or lateral to the upper border of thyroid cartilage where it bifurcates into external carotid artery (ECA) and internal carotid artery (ICA). This level is surgically very significant as carotid bifurcation (CB) is the most common site of atherosclerotic plaque formation in neck region. ECA extends upwards from the level of upper border of thyroid cartilage to a point behind the neck of mandible where it terminates in the substance of parotid gland. It has a slightly curved course so that it is anteromedial to ICA in the lower part and anterolateral to it in the upper part of neck.¹

There are 8 named branches from ECA. Ascending pharyngeal artery (APA) arise as the medial branch, superior thyroid artery (STA), lingual artery (LA) and facial artery (FA) as anterior branches, occipital artery (OA) and posterior auricular artery (PAA) as posterior branches and superficial temporal artery and maxillary artery as the terminal branches of ECA.²

APA is the first branch of ECA, which is a slender artery that runs vertically upwards to the side wall of pharynx. STA originates just below the greater horn of the hyoid bone. It runs downwards and forwards parallel and superficial to the external laryngeal nerve to reach upper pole of thyroid gland to supply it. LA arises behind the tip of greater horn of the hyoid bone. It is the main artery to supply the tongue. It may arise in common with facial artery as linguofacial trunk. By the hyoglossus muscle, lingual artery is divided to three parts. The first part of it lies in the carotid triangle which forms a characteristic loop with convexity upwards above the greater horn of hyoid bone. The loop is crossed superficially by hypoglossal nerve.

Facial artery (FA) arises just above the tip of greater horn of hyoid bone and ascends deep to the digastric and stylohyoid muscles. OA arises from the posterior aspect at the same level as that of facial artery. It runs backwards and upwards under cover of lower border of posterior belly of digastric muscle and crosses the apex of posterior triangle. PAA arises a little above the occipital artery and crosses superficial to stylohyoid muscle. It runs upwards and backwards parallel to the occipital artery along upper border of posterior belly of digastric muscle. Superficial temporal artery and maxillary artery are the terminal branches of ECA which arises behind the neck of mandible deep to parotid

gland. Of these, maxillary artery is larger and superficial temporal artery is the direct continuation of ECA.

Variations in the origin of different branches of ECA are frequently seen. The common variations usually come across are as follows;

1. High or low bifurcation of CCA
2. Number of branches may vary
3. Superior thyroid artery arising from the carotid bifurcation or from the common carotid artery
4. Lingual artery arising from a common trunk as linguofacial trunk or thyro-linguofacial trunk.
5. CCA trifurcating into ICA, ECA & occipital artery
6. Superior laryngeal artery and other glandular branches arising directly from ECA.

Prior knowledge of the varying branching pattern of ECA is essential to surgeons, radiologists and anaesthetists for preventing inadvertent injuries to these vessels during procedures.

We wanted to describe the variations in the branching pattern of ECA in south Kerala population.

METHODS

This cross-sectional descriptive study was conducted for 2 years (2017 to 2019) after getting clearance from the Institutional Ethics Committee, Government medical college, Alappuzha. 22 adult human cadavers of both sexes which were well fixed and preserved in formalin for undergraduate teaching in the Department of Anatomy, Government medical college, Alappuzha were taken and bilateral neck dissection was done so that the total sample size was 44. The dissection of anterior triangle of neck was carried out according to the instructions by Cunningham's Manual of Practical Anatomy.³ Neck of cadaver was properly extended with the support of a wooden block underneath. A vertical skin incision was made from the chin to sternum in the midline. Then another incision along the lower border of mandible was made till angle of mandible and skin flap was reflected laterally. Platysma was reflected upwards and investing layer of deep cervical fascia was cleared. Sternocleidomastoid, anterior belly of omohyoid and infrahyoid muscles were identified and reflected. Carotid sheath was identified, cleared and the contents were exposed. CCA, ECA and ICA were identified on both sides. ECA and its branches were traced according to their landmarks to know whether the branching pattern was normal or variant. Terminal branches were identified after removing the parotid gland in piecemeal. Variations in the branching pattern of ECA were identified and photographed.

The distance between suprasternal notch and mastoid process of temporal bone was measured obliquely using calliper of digital fractions. This distance was halved to determine the midpoint and from the midpoint the distance to carotid bifurcation (CB) is measured.⁴ Origin of various branches from CB was measured in centimetres using digital fractional callipers. The data collected was analyzed

statistically using statistical package for social sciences (SPSS) software.

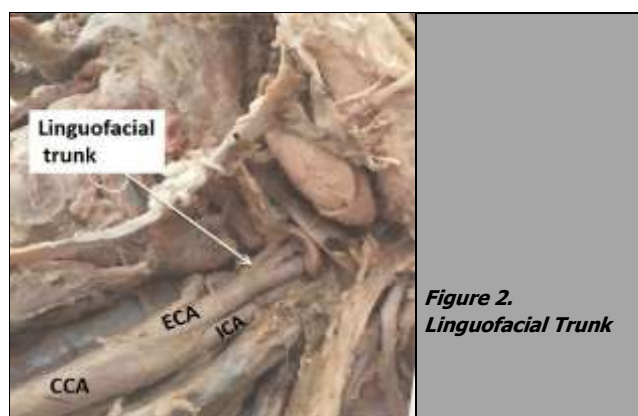
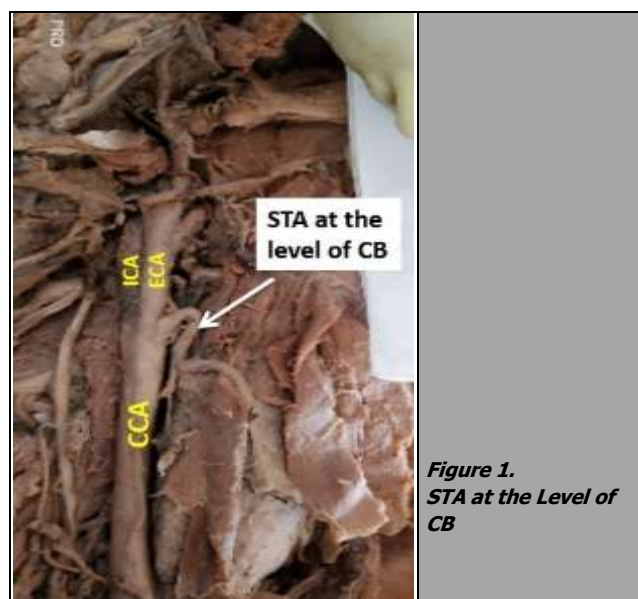
RESULTS

The variations in the branching pattern noted, after fine dissection of 44 ECA are shown in table 1.

Sl. No.	Variations	% of Specimens
1	APA absent	4.5
2	STA from carotid bifurcation	59
3	STA from CCA	7
4	Linguofacial trunk	13.6
5	LA from carotid bifurcation	2.3
6	PAA from OA	2.3
7	STA from OA	2.3
8	Superior laryngeal artery from ECA	2.3

Table 1. Variations Observed and Their % of Occurrence

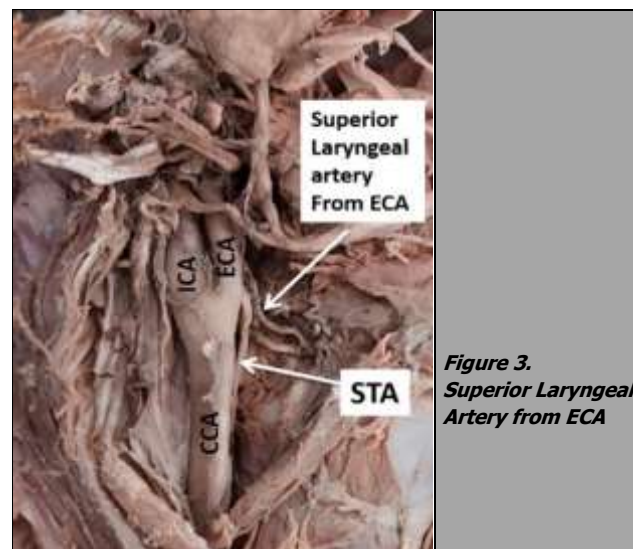
APA was absent in 4.5 % cases. STA took origin from carotid bifurcation in 59 % cases [Fig 1], from common carotid artery in 7 % cases and from ECA in 34 % cases.



In 13.6 % cases lingual artery had a common origin with facial artery as linguofacial trunk from ECA [Fig 2]. In 2.3 %, it had a direct origin from carotid bifurcation. From OA arises PAA in 2.3 % cases and STA in 2.3 % cases.

Accessory branches - In the present study in 2.3 % cases, superior laryngeal artery was seen originating directly from ECA [Fig. 3].

The midpoint of oblique line connecting suprasternal notch and mastoid process was obtained as 7.4 +/- 1 cm and the CB was measured 1.1 +/- 0.5 cm from the midpoint. The distance between the origin of each branch of ECA and carotid bifurcation (CB) was measured in centimetre and tabulated as shown in Table 2.



	Total number	Minimum (cm)	Maximum (cm)	Mean (cm)	sd
MP to Suprasternal notch	44	12	17	14.9	1.9
Midpoint	44	6	8.5	7.4	1.0
Midpoint to CB	44	0.5	2	1.1	0.5
CB to origin of APA	43	0	0.2	0.1	0.1
CB to origin of STA	44	-0.3	1	0.18	0.36
CB to origin of LA	44	0.0	3	1.26	0.73
CB to origin of FA	44	0.5	3	1.7	0.7
CB to origin of OA	44	0.5	3	1.8	0.7
CB to origin of PAA	44	0.5	3.5	2.2	0.8
CB to terminal branches	44	2	6	5.2	0.7

Table 2. Distance between the Origin of Each Branch of ECA and Carotid Bifurcation (CB)

DISCUSSION

Detailed anatomical knowledge on the course and branching pattern of the ECA has gained importance secondary to the novel procedures such as radical neck dissection, cricothyroidectomy, reconstruction and plastic surgeries in the neck and diagnostic and therapeutic catheterization done through these vessels. High spatial resolution magnetic resonance imaging (MRI) technique is used to visualise the vessels.⁵ ECA embolization has proven efficacious in the management of meningioma, paraganglioma and juvenile nasopharyngeal angio fibroma.⁶ Endo vascular treatment for epistaxis is another expanding arena.⁷ In the procedure of carotid endarterectomy also information on the abnormal origin of vessels and branching plays a key role. Another innovative treatment modality is intra-arterial infusion chemotherapy using microcatheters in head and neck tumors.⁸

Yet another area where the arterial tree anatomy comes into an important consideration is the multitude of

reconstructive attempts in head and neck following trauma or malignancy or cosmetic reconstruction. The ECA itself or any of its branches will be useful in the flap bases reconstructive procedures done in this area.⁹ Sometimes it becomes a very challenging task to do the selection of proper recipient vessels for osteocutaneous free flaps, soft tissue free flaps, previously operated and irradiated areas, secondary reconstructions or in reconstruction of extensive head and neck defects. For example, superficial temporal artery-based flaps are very valuable in neck depleted of vessels owing to irradiation, previous surgery or chemotherapy.^{9,10,11}

Variations in the origin and branching pattern of ECA were documented in the literature previously. Hypostapedial artery development which linked the neural crest arterial system to ventral pharyngeal system plays an important role in the development of external carotid artery. ECA develops from the root of third aortic arch. Its branches form as annexations of arteries which develop by angiogenesis from the aortic arches. Development of branching is affected through a complex process of selective regression and persistence of various segments. The signals involved in the development of ECA during angiogenesis and remodelling are not synchronized always, which results in various anatomical variations.¹² Caudal descent of heart causes migration of origin of ECA for a variable distance along the third pharyngeal arch. This embryologic migration of the origin of ECA determines the site of CB. If the migration of ECA fails to reach the normal level, the CB will be at a higher level and viceversa.

One of the reference lines to study the origin of ECA is the line connecting mastoid process and suprasternal notch. The length of this line is 17.1 +/- 1.6 cm in western studies and 14.9 +/- 1.9 cm in our study. The difference in mean may be due to the racial difference in the length of neck. The midpoint of this line is taken as a reference point to measure carotid bifurcation or to find the origin of ECA.⁴ Heltzel et al. in his studies done in western population mentioned the average distance of CB from the midpoint of the line connecting mastoid process and suprasternal notch as 2.5 +/- 0.8 cm.⁴ In our population, we obtained that distance as 1.1 +/- 0.5 cm. The bifurcation of CCA to ECA and ICA was mentioned at the level of thyroid cartilage by many authors. When the bifurcation was noted at the level of hyoid bone it was described as high level of bifurcation of CCA.¹³ In the present study, high level of CB was noted in 27.3 % cases. It was reported earlier by Lucev et al. (12.5 %), Zumro et al. (55%), Ito et al. (31.2 %) and Mompeo et al. (36.9 %).^{14,15,16,17}

Ascending pharyngeal artery (APA) was described as the first branch from ECA. This thin slender vessel was seen arising 0.1 +/- 0.1 cm from CB in our study. Sanjeev et al. reported higher level of origin of APA from ECA (8.4 %) and also from CB (1 %).¹³ Al-Rafiah et al. observed the origin of APA from CB (1.7 %) and from ICA (1.7 %).¹⁸ In the present study APA was absent in 4.5% cases and originated from CB in 2.3 % cases.

STA was seen arising as the first ventral branch from ECA. Direct origin of STA from CCA was mentioned by Natsis.K. et al. (61 %), A.AL-Rafiah et al. (18.3 %) Dessie

M.A. et al. (26.7 %) and Ovhal A.G. et al. (11.66 %).^{18,19,20,21} In the present study, STA directly originated from ECA in 34 % cases and CCA in 7% cases. Dessie M.A. et al. reported origin of STA from CB in 27.9 %. Similar findings were reported by Mata et al. (45.3 %), Gupta .P. et al. and Anitha et al.^{22,23,24} In a cadaveric study published by Anu VR et al. the superior thyroid artery was arising just below the bifurcation of the CCA and also showed a long curved course.²⁵ In the present study STA originated from CB in 59 % cases.

Linguo facial trunk (LFT), thyro lingual trunk (TLT), and thyrolinguo facial trunk (TLFT) were the common trunk formations reported earlier. Devadas D et al. reported LFT formation in 20 % cases and mentioned that as the commonest variation.²⁶ Similar findings were documented by Ovhal A.G. et al. (58.33 %), Zumro O et al. (20 %) and Ozgur Z. et al. (7.5 %).^{21,15,27} Zumre O had also come across in his foetal dissections, thyrolingual trunk in 2.5 %, thyrolinguofacial trunk in 2.5 %, and occipitoauricular trunk in 12.5 % . In a cadaveric dissection study by Theodore G Troupis, the incidence of a combined linguo facial trunk was 6 %.²⁸

In a pre-operative 16 slice computerised tomography (CT) angiographic study of 45 patients, Gui-Hua Jiang observed that the left facial artery arose from the external carotid artery within 4.5 - 47.90 mm (mean 18.77 +/- 8.98 mm) from the carotid artery bifurcation, and in 1 case (2.2 %), the artery arose from the common carotid artery. The right facial artery arose from the external carotid artery in all the 45 cases (100 %), within 6.8 - 39.70 mm (mean 19.23 +/- 8.25 mm) from the carotid artery bifurcation. In one case he found the left facial artery, thyroid artery and lingual artery arising from the same trunk. In another patient, the left facial artery and the submental artery shared the same trunk.²⁹ Valéria Paula Sassoli Fazan estimated the origin distances for the right and left lingual arteries from the common carotid artery bifurcation to be 1.05 +/- 0.11 and 1.02 +/- 0.11 cm respectively with no differences compared to the lingual-facial trunks.³⁰ A case of the lingual artery originating from the common carotid artery was reported by Theodore Troupis.²⁸ In the present study, LFT formation was seen in 13.6 %. In rest of the cases, LA was seen arising 1.26 +/- 0.73 cm from CB and FA originates 1.7 +/- 0.7 cm from CB. Ovhal A.et al. in his study showed TLT formation in 8.33 % and TLFT in 1.67 %. Al Rafiah et al. reported TLT (1.7 %) and TLFT (1.7 %) and Ozgur.Z. et al. noted TLT (2.5 %). In the present study, TLT or TLFT common trunk formation was not observed.

OA and PAA were seen originating 1.8 +/- 0.7 cm and 2.2 +/- 0.8 cm from CB respectively in the present study. Ovhal A. et al. (5 %), Al Rafiah et al. (2.7 %) and Sanjeev et al. (2.7 %) reported OA and PAA as common occipitoauricular trunk. Anu VR et al. also found a similar pattern where the occipital and posterior auricular arteries arose as a common trunk from the ECA and gave a muscular branch to the sternocleidomastoid.²⁵ No such variation was noted in the present study.

Superficial temporal artery and maxillary artery were seen as the terminal branches within the substance of parotid gland in all the 44 cases, with an average distance

of 5.2 +/- 0.7 cm from CB. In an angiographic study by Takenoshita the superior thyroid, lingual and facial arteries had a common origin from the ECA while the maxillary, superficial temporal and occipital arteries arose from the ICA.³¹ An anomaly of the carotid system reported by Bretter showed bilateral maxillofacial trunks. In this case, the maxillary artery had a common origin with the facial artery anteromedially from the external carotid artery on both sides.³²

Accessory branches reported in previous literatures were superior laryngeal artery, muscular arteries and tonsillar artery from ECA. Devadas. D. et al. reported accessory branches in 7.5 % cases and Ovhal.et al. reported in 18.33 %. In this study, 2.3 % cases showed the origin of superior laryngeal artery as a direct branch of ECA. Anu VR et al. identified, in addition to the named branches, two glandular branches which supplied the parotid gland arising directly from the ECA.²⁵

	High Level of CB (%)	STA from CCA (%)	STA from CB (%)	Linguofacial Trunk (%)	SLA from ECA (%)
Lucev et al. (2000)	12.5	-	22.5	-	-
Zumro et al. (2005)	55	-	-	20	-
Ito et al. (2006)	31.2	-	-	-	-
Standring et al. (2008)	25	-	-	-	-
Kipre et al. (2008) ³³	13	-	-	-	-
Ozygur et al. (2009)	-	-	40	7.5	-
Sanjeev et al. (2010)	-	35.14	-	18.9	5
A. Al Rafiah et al. (2011)	18.3	18.3	1.7	1.7	-
Anitha et al. (2011)	-	-	19	-	-
Nayak et al. (2011) ³⁴	-	-	-	-	5.4
Natsis et al. (2011)	-	61	-	-	-
Mata et al. (2012)	-	3.5	45.3	19.9	-
Mompeo et al. (2015)	36.9	-	-	-	-
Ovhal A G et al. (2016)	-	11.7	-	28.3	-
Gupta D et al. (2017)	-	-	40	-	-
Devadas D et al. (2018)	25	-	8.3	20	3.8
Dessie M A et al. (2018)	-	26.7	27.9	-	-
Present study	27.3	7	5.9	13.6	2.3

Table 3. Comparison of the Present Study Findings with Previous Studies

CONCLUSIONS

A thorough anatomical knowledge of normal and anomalous variations in the origin and branching pattern of ECA is important to surgeons and radiologists to prevent iatrogenic injuries. In the present study out of 44 specimens studied, high carotid bifurcation was noted in 27.3 % cases. The origin of superior thyroid artery from carotid bifurcation (59.1 %) was the commonest variation. The second common variation was linguofacial trunk formation (13.6 %). Although these variations were documented in previous literatures, the percentage of occurrence is different in our population.

Data sharing statement provided by the authors is available with the full text of this article at jebmh.com.

Financial or other competing interests: None.

Disclosure forms provided by the authors are available with the full text of this article at jebmh.com.

We thank the teaching and nonteaching faculties of Department of Anatomy, Govt. Medical College, Alappuzha, and Thiruvananthapuram, for their kind support. The authors thank and pay respect to all those kind hearts who have donated their body for research and education purposes without whom this work would not have been accomplished.

REFERENCES

- [1] Standring S. Grays Anatomy. In: The anatomical basis of clinical practice. Vol. 31. 39th edn. Edinburg: Elsevier/Churchill Livingstone 2005: p. 543-544.
- [2] Dutta AK. Essentials of human anatomy. In: Head and Neck. 6th edn. Calcutta: Current Books International 2017: p. 100-103.
- [3] Romanes GJ. Cunningham’s Manual of Practical Anatomy. Vol. 3. 15th edn. Oxford Medica Publication 1986: p. 78-82.
- [4] Heltzel S, Jelinek L, Jaynes D. Variation in the caudal branches of the external carotid artery: comparison of sex and side. Med Res Arch 2015;1:1-10.
- [5] Lohan DG, Barkhordarian F, Saleh R, et al. MR angiography at 3 T for assessment of the external carotid artery system. AJR Am J Roentgenol 2007;189(5):1088-1094.
- [6] Kasper GC, Welling RE, Wladis AR, et al. A multidisciplinary approach to carotid paragangliomas. Vasc Endovascular Surg 2006;40(6):467-474.
- [7] Vokes DE, Mclover NP, Wattie WJ, et al. Endovascular treatment of epistaxis. ANZ Journal of Surgery 2004;74(9):751-753.
- [8] Nakasato T, Katoh K, Sone K, et al. Superselective continuous arterial infusion chemotherapy through superficial temporal artery for oral cavity tumors. Am J Neuroradiol 2000;21(10):1917-1922.
- [9] Kushida-Contreras BH, Manrique OJ, Gaxiola-García MA. Head and neck reconstruction of the vessel-depleted neck: a systematic review of the literature. Ann Surg Oncol 2021;28(5):2882-2895.
- [10] Chung JH, Kim KJ, Jung KY, et al. Recipient vessel selection for head and neck reconstruction: a 30-year experience in a single institution. Arch Craniofac Surg 2020;21(5):269-275.
- [11] Wong KK, Higgins KM, Enepekides DJ. Microvascular reconstruction in the vessel-depleted neck. Curr Opin Otolaryngol Head Neck Surg 2010;18(4):223-226.
- [12] Larsen W. Human Embryology. 2nd edn. New York: Churchill Livingstone 1998: p. 191-195.
- [13] Sanjeev IK, Anita H, Ashwini M, et al. Branching pattern of external carotid artery in human cadaver. J Clin Diagn Res 2010;4:3128-3133.
- [14] Lucev N, Bobinac D, Mariac I, et al. Variations of the great vessels in the carotid triangle. Otolaryngol Head Neck Surg 2000;122(4):590-591.
- [15] Zumre O, Salbacak A, Cicekcibasi AE, et al. Investigation of the bifurcation level of the common carotid artery and variations of the branches of the external carotid artery in human foetuses. Ann Anat 2005;187(4):361-369.
- [16] Ito H, Mataga I, Kageyama I, et al. Clinical anatomy in the neck region--the position of external and internal

- carotid arteries may be reversed. *Okajimas Folia Anat Jpn* 2006;82(4):157-167.
- [17] Mompeo B, Bajo E. Carotid bifurcation: clinical relevance. *Eur J Anat* 2015;19(1):37-42.
- [18] Natsis K, Raikos A, Foundos I, et al. Superior thyroid artery origin in Caucasian Greeks: a new classification proposal and review of the literature. *Clin Anat* 2011;24(6):699-705.
- [19] Al-Rafiah A, El-Haggagy AA, Aal IH, et al. Anatomical study of the carotid bifurcation and origin variations of the ascending pharyngeal and superior thyroid arteries. *Folia Morphol (Warsz)* 2011;70(1):47-55.
- [20] Dessie MA. Variations of the origin of superior thyroid artery and its relationship with the external branch of superior laryngeal nerve. *PLoS One* 2018;13(5):e0197075.
- [21] Ovhal AG, Ansari MM, Rajgopal L. A cross sectional study of variations in the external carotid artery in cadavers. *Indian Journal of Clinical Anatomy and Physiology* 2016;3(3):285-289.
- [22] Mata JR, Mata FR, Souza MCR, et al. Arrangement and prevalence of branches in the external carotid artery in humans. *Ital J Anat Embryol* 2012;117(2):65-74.
- [23] Gupta P, Bhalla AS, Thulkar S, et al. Variations in superior thyroid artery: a selective angiographic study. *Indian J Radiol Imaging* 2014;24(1):66-71.
- [24] Anitha T, Dombé D, Asha K, et al. Clinically relevant variations of the superior thyroid artery: an anatomic guide for neck surgeries. *Int J Pharm Biomed Sci* 2011;2:51-54.
- [25] Anu VR, Pai MM, Rajalakshmi R, et al. Clinically-relevant variations of the carotid arterial system. *Singapore Med J* 2007;48(6):566-569.
- [26] Devadas D, Pillay M, Sukumaran TT. A Cadaveric study on variations in branching patterns of external carotid. *Anatcellbiol* 2018;51(4):225-231.
- [27] Ozgur Z, Govsa F, Ozgur T. Anatomical evaluation of the carotid artery bifurcation in cedavers: implications for open and endovascular therapy. *Surg Radiol Anat* 2008;30(6):475-480.
- [28] Troupis T, Michalinos A, Dimovelis I, et al. Bilateral abnormal origin of the anterior branches of the external carotid artery. *Ann Vasc Surg* 2014;28(2):494.e5-e7.
- [29] Jiang GH, Yan JH, Lin CL, et al. Anatomic study of the facial artery using multislice spiral CT angiography. *Nan Fang Yi Ke Da Xue Xue Bao* 2008;28(3):457-459.
- [30] Fazan VPS, Da Silva JHN, Borges CT, et al. An anatomical study on the lingual-facial trunk. *Surg Radiol Anat* 2009;31(4):267-270.
- [31] Takenoshita H. Case of hypoplasia of the internal carotid artery associated with persistent primitive hypoglossal artery. *Kaibogaku Zasshi* 1983;58(5):533-550.
- [32] Pretterklieber ML, Krammar EB, Mayr R. A bilateral maxillofacial trunk in man: an extraordinary anomaly of the carotid system of arteries. *Acta Anat (Basel)* 1991;141(3):206-211.
- [33] Zunon-Kipre Y, Ouattara D, Broalet E, et al. Investigations of the collateral branches of the external carotid artery in population from West Africa. About 60 cadaver dissections. *Morphologie* 2008;92(299):176-180.
- [34] Nayak SR, Krishnamurthy A, Prabhu LV, et al. Variable origin of the superior laryngeal artery and its clinical significance. *Al Ameen J Med Sci* 2011;4(1):69-74.