

CASE REPORT

VALSALVA LIKE RETINOPATHY SECONDARY TO LEUKEMIA: A CASE REPORT

Shashidhar S¹, Manasa Penumetcha², Shilpa Y. D³, Kailash P. Chhabria⁴

HOW TO CITE THIS ARTICLE:

Shashidhar S, Manasa Penumetcha, Shilpa Y. D, Kailash P. Chhabria. "Valsalva like Retinopathy Secondary to Leukemia: A Case Report". Journal of Evidence based Medicine and Healthcare; Volume 2, Issue 11, March 16, 2015; Page: 1725-1729.

INTRODUCTION: Pre-retinal haemorrhages (Sub-ILM or Sub-hyaloid) are seen to be associated with valsalva retinopathy, Tersons syndrome, blood dyscrasias and blunt trauma. However spontaneous Sub-ILM/Sub-hyaloid haemorrhage is a rare presentation. A Case report of Spontaneous Sub - ILM haemorrhage has been described by Mayer et al secondary to Acute myeloid leukemia with thrombocytopenia where a vitrectomy was done. Borges et al reported a case of non hodgkins lymphoma on chemotherapy who developed sudden onset loss of vision in both eyes. Vitrectomy with ILM peeling was done for both eyes at an interval of 1 week. It was observed that the eye which was operated first had a better visual outcome than the other eye hence the authors advocated early intervention. A case of spontaneous bilateral premacular hemorrhage was reported by L. Wan-Wei et al in a patient of idiopathic thrombocytopenic purpura. The patient was offered a vitrectomy to resolve the subhyaloid haemorrhage associated with vitreous haemorrhage, but patient denied treatment. The underlying condition of ITP was treated medically and the hemorrhages improved with recovery of vision. We report a case of spontaneous pre-retinal haemorrhage in acute myeloid leukemia with complete resolution of the same over a period of two months of close follow up.

KEYWORDS: Sub-ILM hemorrhage, Sub-hyaloid haemorrhage, Acute myeloid leukemia.

CASE REPORT: A 17 year old female with history of acute myeloid leukemia type M2 (French-American-British classification) on chemotherapy came to the ophthalmology Out-patient department with sudden onset visual loss in the right eye. She denied any pain associated with eye movements, diplopia, or any valsalva inducing activities.

Snellen's visual acuity in Right eye was 3/60 and 6/6 in left eye. Anterior segment of both eyes was within normal limits also extraocular movements and intraocular pressure in both eyes was normal. Dilated fundus examination in the right eye revealed dilated tortuous vessels, a premacular haemorrhage of 2.5DD and a pre-retinal haemorrhage of 4.5 DD in the inferonasal aspect of retina along with few superficial haemorrhages along the arcades and blurring of nasal margins of the disc. In the left eye also there were dilated tortuous vessels with a preretinal haemorrhage of 4.5 DD. located along the superior vascular arcade sparing the macula with flame shaped haemorrhages along the vascular arcades with blurring of nasal margins of the disc. Initial laboratory work up was significant for haemoglobin 6.6 gm/dl and platelet count of 17000/cumm. Patient was advised Nd YAG posterior hyaloidotomy. Patient refused the procedure and continued with the course of chemotherapy, hence, she was advised for a regular follow up.

At 2 months follow up the pre-retinal haemorrhage was noted to have spontaneously resolved and her visual acuity in right eye improved to snellen's visual acuity of 6/6 and in left

CASE REPORT

eye it was noted to be 6/6. On dilated fundus examination all haemorrhages pre-retinal and intra-retinal resolved spontaneously.

The patient had completed both induction and consolidation phase of chemotherapy at the above mentioned follow up.

DISCUSSION: Leukemic retinopathy was first described by Liebhaf in 1860 and since that time, virtually all ocular structures have been found to become involved.^[1,2]

The eye is involved in leukemia either directly or indirectly from thrombocytopenia, anaemia, hyperviscosity or chemotherapeutic agents. The retina is the tissue most frequently involved in leukemic complication seen in the form of haemorrhages. Other fundus findings include preretinal white clumps or masses, focal white lesions within retinal hemorrhages and cotton wool spots.^[3] Alemany et al (1996) estimated that up to 69 % of all patients with leukemia show fundus changes at some point in the course of their disease.^[4] Retinal haemorrhage is usually seen at the posterior pole, can occur in all levels of the retina and may extend into the subretinal space or vitreous.^[1,2]

Prior studies have shown that the prevalence of retinopathy in patients with anemia or thrombocytopenia is 28.3%. But with both conditions in the same patient, the prevalence increases to 42%, suggesting a synergistic effect. 70% of patients were found to have fundus lesions at a haemoglobin level of less than 8gm/d.^[5,6] This can be understood by knowing the related pathophysiology. Low haemoglobin levels lead to a decrease in oxygen carrying capacity hence damage to the endothelial capillary lining of retinal vessels.^[7] Normally, platelets provide a degree of protection for the compromised endothelial cell lining. However, in presence of thrombocytopenia with anemia, there are insufficient platelets to adequately protect the endothelial lining, placing the tissue at risk for hemorrhage.^[6]

At the time of presentation our patient also showed laboratory parameters of anemia and thrombocytopenia (Haemoglobin-6.6gm/dl, platelet count - 17000/cumm) explaining the cause of the preretinal haemorrhage. Also it was noted that ocular complaints developed one month after the start of chemotherapy. Studies have shown that the chemotherapeutic agents used for leukemias are known to cause bone marrow suppression which could be the cause for low platelet counts and the resultant anemia.^[8]

Premacular subhyaloid haemorrhage is one of the important causes of poor vision in leukemic children. The haemorrhage can cause profound visual loss and if it is bilateral it can hamper the daily routine activities. Spontaneous resolution of pre macular haemorrhage usually takes several months.

Hence it has been advocated that these premacular haemorrhages(sub-hyaloid and sub-ILM) should be treated early.in view of scarring which can occur due to Retinal pigment epithelial migration to the site of haemorrhage with the development of scar tissue in the form of epiretinal membrane(1),^[9] also there can be toxic injury to the retina due to prolonged contact with haemoglobin and iron.^[10] One of the well accepted treatment modalities includes posterior hyaloidotomy which is considered the safest amongst the available treatment options.^[11]

However immediate treatment was delayed due to the degree of her thrombocytopenia, anemia and non-willingness of the patient for the procedure. In this particular case close

CASE REPORT

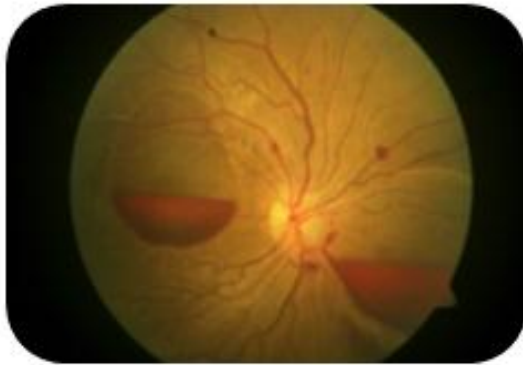observation for a period of 2 months did result in spontaneous resolution without any residual visual morbidity and the patient had a final snellen's visual acuity of 6/6.

CONCLUSION: We report a case which demonstrates the importance of treating the underlying mechanism by close observation while keeping a keen look for timely intervention when necessary in our case of leukemic retinopathy secondary to thrombocytopenia.

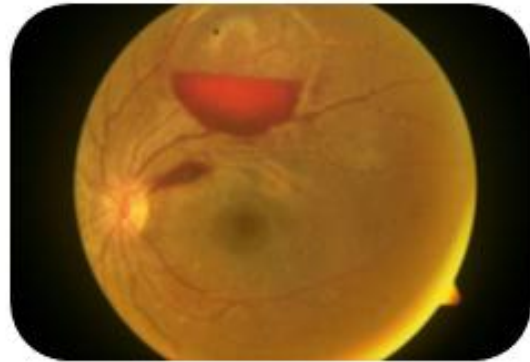
BIBLIOGRAPHY:

1. Ridgeway EW, Jaffe N, Walton DS (1976). Leukemic ophthalmopathy in children. *Cancer*; 38: 1744-1749
2. Mahneke A, Videback A (1964). On Changes in the Optic Fundus in Leukemia. *Acta Ophthalmol*; 42: 201-210.
3. Duke-Elder S (1967). *System of Ophthalmology*. St Louis CV Mosby; Vol 10: 387-390.
4. Alemayehu W, Shamebo M, Bedri A, Mengistu Z (1996). Ocular manifestations of leukemia in Ethiopians. *Ethiop Med J*; 34: 217-224.
5. Carraro MC, Rossetti L, Gerli GC. Prevalence of retinopathy in patients with anemia or thrombocytopenia. *European journal of haematology*. 2001;67(4):238-44.
6. Rubenstein RA, Yanoff M, Albert DM. Thrombocytopenia, anemia, and retinal hemorrhage. *American journal of ophthalmology*. 1968;65(3):435-9.
7. A. Agarwal and D. M. Gass, *Gass' Atlas of Macular Diseases*, Saunders, Philadelphia, Pa, USA, 5th edition, 2012.
8. Robert A. Prinzi,¹ Steven Saraf et al Valsalva-Like Retinopathy Secondary to Pancytopenia following Induction of Etoposide and Ifosfamide. *Case Reports in Ophthalmological Medicine* Volume 2015.page 2-4
9. O'Hanley GP, Canny CL. Diabetic dense premacular hemorrhage. A possible indication for prompt vitrectomy. *Ophthalmology*. 1985;92(4):507-11.
10. Rennie CA, Newman DK, Snead MP, Flanagan DW. Nd:YAG laser treatment for premacular subhyaloid haemorrhage. *Eye*. 2001;15(Pt 4):519-24.
11. Khadka D et al Nd: YAG laser for sub-hyaloid haemorrhage *Nepal J Ophthalmol* 2012; 4 (7):102-107.

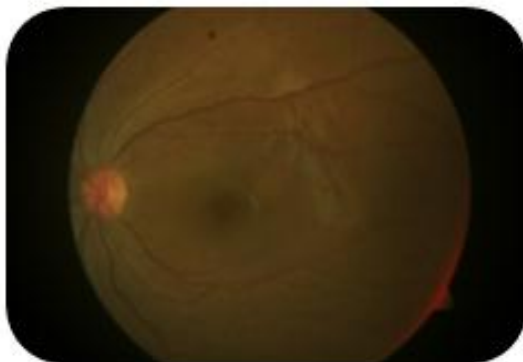
CASE REPORT



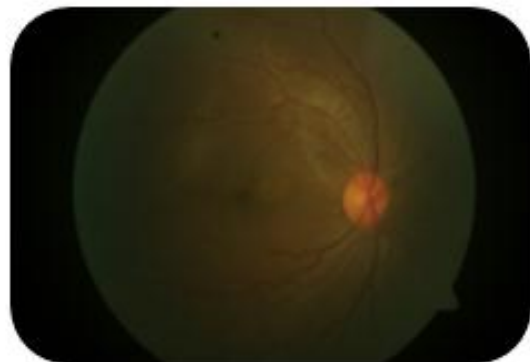
Fundus photograph at presentation of right eye



Fundus photograph at presentation of left eye



Fundus photograph at 2 months follow up of left eye



Fundus photograph at 2 months follow up of right eye

Colour Plates: Valsalva Like Retinopathy Secondary To Leukemia: A Case Report

CASE REPORT

AUTHORS:

1. Shashidhar S.
2. Manasa Penumetcha
3. Shilpa Y. D.
4. Kailash P. Chhabria

PARTICULARS OF CONTRIBUTORS:

1. Associate Professor, Department of Ophthalmology, Minto Ophthalmic Hospital & Regional Institute of Ophthalmology, BMC & RI, A. V. Road, Opposite Central Police Station, Chamaraj Pete, Bangalore, Karnataka, India.
2. Resident, Department of Ophthalmology, Minto Ophthalmic Hospital & Regional Institute of Ophthalmology, BMC & RI, A. V. Road, Opposite Central Police Station, Chamaraj Pete, Bangalore, Karnataka, India.
3. Assistant Professor, Department of Ophthalmology, Minto Ophthalmic Hospital & Regional Institute of Ophthalmology, BMC & RI, A. V. Road, Opposite Central Police Station, Chamaraj Pete, Bangalore, Karnataka, India.

4. Resident, Department of Ophthalmology, Minto Ophthalmic Hospital & Regional Institute of Ophthalmology, BMC & RI, A. V. Road, Opposite Central Police Station, Chamaraj Pete, Bangalore, Karnataka, India.

NAME ADDRESS EMAIL ID OF THE CORRESPONDING AUTHOR:

Dr. Shashidhar S,
Department of Ophthalmology,
Minto Ophthalmic Hospital & Regional
Institute of Ophthalmology,
BMC & RI, A. V. Road,
Opposite Central Police Station,
Chamaraj Pete, Bangalore-560002,
Karnataka, India.
E-mail: swamysashidhar@gmail.com

Date of Submission: 08/03/2015.
Date of Peer Review: 09/03/2015.
Date of Acceptance: 11/03/2015.
Date of Publishing: 16/03/2015.