ULTRASOUND SCREENING OF THYROID GLAND AMONG A SECTION OF POPULATION IN CENTRAL KERALA

Ashok Chirathalattu Babu[1], Mattavana Ramakrishna Pillai Balachandran Nair[2], Anu Kooliyedathu Balan[3], Kiran Thilakarajan[4]

[1]Junior Resident, Department of Radiodiagnosis, Jubilee Mission Medical College and Research Institute, Thrissur, Kerala.
[2]Professor and HOD, Department of Radiodiagnosis, Jubilee Mission Medical College and Research Institute, Thrissur, Kerala.
[3]Junior Resident, Department of Radiodiagnosis, Jubilee Mission Medical College and Research Institute, Thrissur, Kerala.
[4]Junior Resident, Department of Radiodiagnosis, Jubilee Mission Medical College and Research Institute, Thrissur, Kerala.

ABSTRACT

BACKGROUND

Thyroid diseases are commonest endocrine disorders in India. Studies have shown that one in ten adults in India suffer from hypothyroidism. But it is often underdiagnosed and goes undetected for years. The present study was intended to perform thyroid ultrasound screening among a section of Thrissur population for evaluating the prevalence, various patterns of thyroid pathologies, its age and sex relation.

MATERIALS AND METHODS

Ultrasound screening for thyroid gland was done for 100 individuals selected from a skewed population of St. Joseph's Church, Kuriachira, Thrissur, Kerala between Nov. 16– Nov. 30 of 2016.

RESULTS

Among 100 individuals, 51 were found to have thyroid diseases. Among these 51, various patterns of thyroid diseases were noted; thyroiditis (17), multinodular goitre (12), benign nodules (17) and atypical nodules (7). 47 out of 73 females and 4 out of 27 males had thyroid abnormalities. The study also demonstrated that prevalence of thyroid disease was more in the age group of 60-70 years (78.5%).

CONCLUSION

Our study demonstrated high prevalence of thyroid diseases (5 in 10) in the study population. Association with increasing age and female predisposition for thyroid diseases also noted.

KEYWORDS

Ultrasound Screening, Hypothyroidism.

HOW TO CITE THIS ARTICLE: Babu AC, Nair MRPB, Balan AK, et al. Ultrasound screening of thyroid gland among a section of population in central Kerala. J. Evid. Based Med. Healthc. 2017; 4(50), 3043-3047. DOI: 10.18410/jebmh/2017/603

BACKGROUND

Endocrine disorders are common among Indian population. Thyroid disorders account for a majority of these endocrine disorders.[1] It is estimated that 42 million people in India have thyroid disorders.[2,3] Hypothyroidism is the most common thyroid disorder in Indian population.[3]

Hypothyroidism includes a broad spectrum ranging from an asymptomatic/subclinical condition with normal levels of T_3 and T_4 to an overt state of myxoedema, end-organ effects and multisystem failure. In the developed world, the prevalence of hypothyroidism is about 4-5% and subclinical hypothyroidism is about 4- 15%.[4]

Financial or Other, Competing Interest: None.
Submission 19-05-2017, Peer Review 26-05-2017,
Acceptance 08-06-2017, Published 20-06-2017.
Corresponding Author:
Dr. Mattavana Ramakrishna Pillai Balachandran Nair,
Professor and HOD,
Department of Radiodiagnosis,
Jubilee Mission Medical College and Research Institute,
Jubilee Mission P.O, Thrissur, Kerala- 680005.
E-mail: mrbaala@gmail.com
DOI: 10.18410/jebmh/2017/603

Studies have shown that one in ten adults in India suffer from hypothyroidism.[4,5] The awareness about the disease and the importance of its diagnosis remains shockingly very low in our country. A recent survey conducted by Indian Thyroid Society depicted that the awareness for the thyroid disease is ranked ninth when compared to other common ailments such as asthma, cholesterol problem, depression, diabetes, insomnia and heart problem. Hypothyroidism is continuing to grow significantly in our country, particularly among women population.[5]

Thyroid disorders can impair the normal functioning of thyroid gland, causing abnormal production of hormones which may lead to hypo/hyperthyroidism, hypothyroidism being more common. If left untreated, it can cause various effects like hypercholesterolaemia, hypertension, cardiovascular complications, decreased fertility, and depression. Unlike other diseases, thyroid diseases have an upper hand for evaluation because of their ease of diagnosis and accessibility of medical treatment. Early diagnosis and treatment remain the cornerstone of management.[6]

Ultrasonography plays an important role in the evaluation and management of thyroid disorders. Thyroid ultrasonography is the most common, extremely useful,

non-invasive, safe, inexpensive and widely available method to image the thyroid gland and its pathology, as recognised in guidelines for managing thyroid disorders published by the American Thyroid Association.[7,8] The major drawback of ultrasound in thyroid imaging is that it cannot determine thyroid function, (whether thyroid gland is normal in function, under-active or overactive) for which a blood test (TFT) or radioactive isotope uptake test is usually required.[8] Ultrasound screening for thyroid disease will help to identify and treat the patients at risk of thyroid dysfunction before they become clinically apparent. The present study was to perform thyroid ultrasound screening among a section of population in central Kerala (Thrissur) for evaluating the prevalence of various patterns of thyroid pathologies, its age and sex relation.

MATERIALS AND METHODS

A free medical camp was organised by Jubilee Mission Medical College & RI, Thrissur for the parish population of St. Joseph's Church, Kuriachira, Thrissur, Kerala. As a part of it, free thyroid ultrasound screening programme was done between Nov. 16 – Nov. 30 of 2016. Screening was done for 100 individuals in the age group of 20–70 years. All individuals were physically healthy and did not give history of any illness. There was no history of taking any thyroid medications or surgeries in the past. On our physical examination, 12 individuals had palpable neck swelling which they were unaware of/failed to notice. Ultrasonographic examinations were performed at the Department of Radiodiagnosis, Jubilee Mission Medical College with GE VOLUSON 730PRO A44912 scanner using a 12-MHz ultrasound probe.

RESULTS

Of the 100 subjects, the findings in 49 (49%) were considered normal (a normal-sized gland with no distinct nodules). Ultrasound findings were abnormal in 51 subjects (51%). These findings included various focal and diffuse abnormalities. Seventeen subjects had features of thyroiditis, of which Hashimoto's thyroiditis was seen in 10. Multinodular goitre was detected in 12 subjects. Benign nodules were seen in 17 and atypical nodules in 7 subjects. In 2 subjects, atypical nodules were identified in the background of multinodular goitre.

The prevalence of thyroid disorders was seen to be more common in females, consistent with worldwide reports. Among our study population of 100 individuals, 73 were female and 27 were male. Of the 73 females, 47 had some thyroid abnormalities and of the 27 male subjects, only 4 had thyroid disease. Prevalence of thyroid diseases was also found to increase with increasing age and the highest prevalence was in the age group of 60-70 years (78.5%).

Depending upon the age group distribution, prevalence of thyroid diseases were depicted in Table 1. The relation between the pattern of disease and age group is depicted in Table 2.

Age Group	Total Subjects	Disease	Prevalence Percentage
20- 30	13	1	7.6
30-40	35	18	51.4
40-50	30	16	53.3
50-60	8	5	62.5
60-70	14	11	78.5

Table 1. Prevalence of Thyroid Diseases Depending Upon Age Group Distribution

Age Group	Hashimoto's Thyroiditis	Other Thyroiditis	MNG	Benign Nodule	Atypical nodule
20-30	0	0	0	1	0
30-40	6	3	2	5	2
40-50	1	2	4	7	2
50-60	0	0	1	3	1
60-70	3	2	5	1	2

Table 2. Age Group vs. Various Patterns of Thyroid Disease Relation

DISCUSSION

High resolution ultrasonography (USG) is regarded as the most sensitive imaging modality for thyroid gland evaluation.[8] Both longitudinal and transverse scans will be required for comprehensive assessment of thyroid gland. Transverse scan will be useful to locate thyroid nodules, their relationship to trachea, major vessels in carotid sheath, and also to assess internal architecture and extrathyroidal extension. Longitudinal scan will help to evaluate internal architecture, vascularity and extrathyroidal extension.

Thyroid nodule evaluation is divided into - ultrasound features of thyroid nodule- evaluation of adjacent structures (including trachea, oesophagus, strap muscles, carotid artery, internal jugular vein) and cervical lymph nodes.[9]

USG is useful in the evaluation of diffuse as well as focal thyroid abnormalities. Common conditions presenting as diffuse thyroid enlargement includes multinodular goitre, de-Quervain's thyroiditis and autoimmune thyroiditis. Graves' disease and Hashimoto's thyroiditis account for the majority of cases of autoimmune thyroiditis.

Multinodular goitre (MNG) is the common cause for asymmetric thyromegaly. About 3-5% of population are affected in developed countries. Ultrasonography is a key tool for its evaluation, as it can identify the presence of suspicious nodules (if any) and mass effect. Ultrasonographic appearance of MNG is usually a diffusely enlarged gland with multiple nodules. Most nodules are iso/hyperechoic and when enlarged provide heterogeneous echo pattern. Nodules often undergo degenerative changes like cystic degeneration with anechoic appearance to the nodule, haemorrhage/infection within the cyst to appear as moving internal echoes/septations. Colloidal degenerations produce comet-tail artefact. Dystrophic calcification often appears as coarse or curvilinear. (Figure 1)

Graves' disease is characterised by thyrotoxicosis due to circulating thyroid-stimulating hormone (TSH) receptor autoantibodies (TRAb) with thyroid-stimulating activity. On

USG, thyroid is diffusely enlarged (2-3 times its normal size) with hypoechoic and heterogeneous echo pattern. Colour Doppler shows marked increase in parenchymal vascularity (Thyroid inferno).

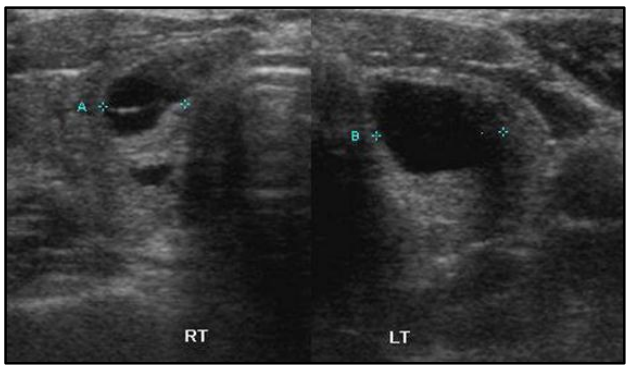

Figure 1. A 42-year-old Female with Multiple Nodular Lesions of Varying Sizes in both Lobes Having Cystic Changes Consistent with MNG

Hashimoto's thyroiditis is characterised by chronic, autoimmune-mediated lymphocytic inflammation of thyroid gland which ultimately leads to destruction of the gland and hypothyroidism. Ultrasound features vary with different stages of disease. The characteristic ultrasonographic appearance is focal or diffuse, moderately enlarged, hypoechoic, heterogenous, micronodular gland with lobulated outlines and with fine, fibrotic streaks within. (Figure 2). De Quervain's thyroiditis is a self-limiting inflammatory condition that usually occurs following a viral illness. Patients typically present with neck pain, thyroid tenderness, fever and constitutional symptoms. On USG, appears as focal, ill-defined, hypoechoic, nodular area in thyroid (subcapsular) in the acute phase and as diffuse goitre with patchy or confluent ill-defined hypoechoic area with hypovascular/avascular appearance in subacute phase.[8, 10]

Ultrasonography is also very useful in differentiating between malignant and benign nodules. Common causes of benign thyroid nodules are nodular hyperplasia, thyroid adenomas, thyroid cysts, Hashimoto's thyroiditis. USG findings suggestive of benign nodules include iso/hyperechogenicity of thyroid nodule, cystic nodule, spongiform appearance, presence of a complete uniform hypoechoic halo around the nodule, coarse/curvilinear calcifications, ring down/comet-tail sign and perinodular flow/spoke and wheel like appearance of vessels on colour Doppler (Figure 3). Malignant tumours of thyroid includes papillary carcinoma, follicular carcinoma, medullary carcinoma, anaplastic carcinoma, lymphoma and metastases. Anaplastic thyroid carcinoma and lymphoma are highly aggressive tumours with early and extensive local invasion. Metastases to thyroid gland are rare and main primary tumours are malignant melanoma, breast carcinoma and renal cell carcinoma. USG features predictive of malignant nodules include presence of microcalcifications, local invasion, lymph node metastases, marked hypoechogenicity, microlobulated or irregular margins, solid composition, taller than wide shape (Figure 4). [8,11-13]

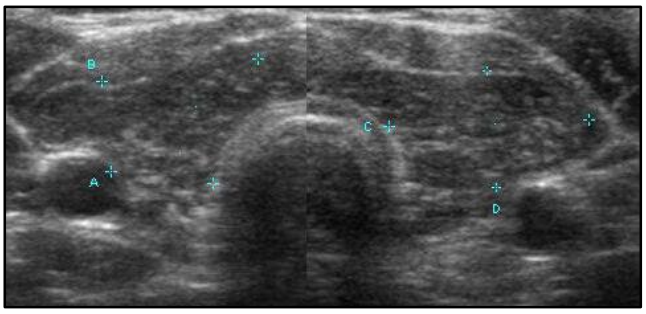

Figure 2. Ultrasound of a 36-year-old Female Showing Diffuse Enlargement, Hypoechoic Glandular Parenchyma, Coarse Echotexture and Fine Linear Strands Suggestive of Hashimoto's Thyroiditis.

Figure 3. Benign Nodule with Homogenous Echotexture and Thin Hypoechoic Continuous Halo Around

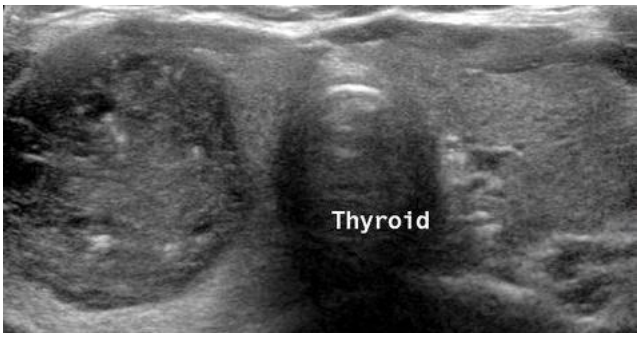

Figure 4. A Large Hypoechoic Heterogeneous Nodule with Cystic Changes and Focal Areas of Microcalcifications in Right Lobe. FNAC Proved it to be Papillary Carcinoma

Colour Doppler ultrasound is an imaging technique that assesses the presence and distribution of vessels within the thyroid nodule. Nodule vascularity is categorised as absent blood flow (type 1), marked perinodular and absent or slight intranodular blood flow (type 2), and marked intranodular and absent or slight perinodular blood flow (type 3). Intranodular vascularity is associated with malignancy.[14]

Ultrasound elastography is used to detect the nature of thyroid nodules, by measuring the tissue stiffness noninvasively. Malignant nodules tend to be much harder than benign ones. Strain and shear wave elastography are the 2 types currently used in clinical practice. Strain (Static compression) elastography evaluates elasticity through tissue displacement caused by compression, with degree of

displacement being larger in soft tissue than in hard tissue. It requires an external compression with a probe or endogenous stress such as physiologic pulsations from the carotid artery as the sole compression source. Shear wave elastography evaluates elasticity through propagation speed of transverse oriented shear waves, with wave speed being faster in hard tissue than in soft tissue. Two approaches in shear wave elastography include the supersonic shear wave and the acoustic radiation force impulse (ARFI) methods. Supersonic shear wave uses focused ultrasonic beams that propagate through the entire imaging area. ARFI uses short-duration acoustic pulses that excite the tissue within the region of interest. Role of elastography is to identify nodules that are benign that would have otherwise been biopsied, to identify nodules likely to be malignant that require biopsy/further followup and to highlight areas within nodules to target/avoid for FNAC to reduce nondiagnostic or inadequate cytology.[14,15]

Studies in western countries have shown that about 50% of people have microscopic nodules, 5% of women have overt hypothyroidism or hyperthyroidism, 15% have palpable goitres, 3.5% have occult papillary carcinoma.[16-18] Thyroid cancer is the most common endocrine malignancy with more mortality.[19]

In the study by Unnikrishnan et al, hypothyroidism was found to be the common form of thyroid dysfunction affecting 10.9% of Indian study population. Predominance of thyroid dysfunction in women was also shown in the study, especially those in midlife (46-54 years).[3] In a population-based study done in Cochin among 971 adult subjects, the prevalence of hypothyroidism was found to be 3.9%. The prevalence of subclinical hypothyroidism was 9.4%. In women, the prevalence was higher at 11.4%, when compared with men (6.2%).[20]

Sensitivity of clinical examination in the detection of nodules was 38% in the study by Christensen and Tibblin.[21] As expected, the prevalence is high with thyroid ultrasound when compared with that in clinical epidemiologic studies and autopsy studies. Ultrasonography is much more sensitive in the identification of nodules. Carroll reported thyroid nodules in 13.4% patients referred for ultrasound of the carotid arteries.[22] Stark et al found one or more nonpalpable thyroid lesions in 40% of patients referred for parathyroid surgery.[23] Higher prevalence was also reported by Horlocker et al (462 of 1,000),[24] Woestyn et al (77 of 300),[25] Stark et al (26 of 65).[23]

The increasing effects of ageing and female sex on prevalence of thyroid disease were demonstrated by ultrasonography as in clinical studies. Oertel and Klinck reported an 8% prevalence (8 of 97) of nodules in healthy men in the 2nd decade of life and a prevalence of 24% (9 of 38) in the 3rd decade.[26]

Brander et al in 1989 performed thyroid ultrasound among 101 women aged 49-58 years in an urban area in southern Finland. Thyroid nodules or abnormalities of echotexture were found in 36 (35.6%) subjects. Seventeen (47.2%) subjects had solitary nodules, 14 (38.9%) had multiple nodules, and five (13.9%) had diffuse abnormalities.[27] Brander et al in 1991 again performed thyroid ultrasound in 253 subjects (130 women and 123 men in the age group 19-50 years) in the same area. Thyroid echo abnormalities were found in 69 subjects (27.3%). Abnormalities were solitary in 39 subjects (57%), multiple in 15 (22%), and diffuse in 15 (22%). Prevalence of abnormalities were shown to increase with age. Women showed more lesions than men in each decade.[28]

CONCLUSION

The prevalence of thyroid diseases in our study population was found to be surprisingly very high (5 in 10) when compared to recent Indian standards (1 in 10). Our study may have been biased and influenced by many factors, but still the results of our study is an eye opener. Even in our state with high literacy rate, majority of the population is still unaware and has only little knowledge about thyroid diseases. Hence, further epidemiological studies must be carried out for detailed assessment of the current situation.

ACKNOWLEDGEMENT

We extend our sincere gratitude to faculty members of Jubilee Centre for Medical Research for editing this article.

REFERENCES

[1] Nagarkar R, Roy S, Akheel M, et al. Incidence of thyroid disorders in India: an institutional retrospective analysis. International Journal of Dental and Medical Speciality 2015;2(2):19-23.
[2] Nimmy NJ, Aneesh PM, Narmadha MP, et al. A survey on prevalence of thyroid disorders induced by demography and food habits in south Indian population. Indian Journal of Pharmacy Practice 2012;5(2):49-52.
[3] Bagcchi S. Hypothyroidism in India: more to be done. Lancet Diabetes Endocrinol 2014;2(10):778.
[4] Unnikrishnan AG, Kalra S, Sahay RK, et al. Prevalence of hypothyroidism in adults: an epidemiological study in eight cities of India. Indian J Endocrinol Metab 2013;17(4):647-652.
[5] Sushmi Dey. 1 in 10 Indians suffer from thyroid disorder: study. The times of India. 2015 Jan25. http://timesofindia.indiatimes.com/india/1-in-10-Indians-suffer-from-thyroid-disorder-Study/articleshow/46007453.cms
[6] Unnikrishnan AG, Menon UV. Thyroid disorders in India: an epidemiological perspective. Indian J Endocrinol Metab 2011;15(Suppl2):78-81.
[7] Kangelaris GT, Kim TB, Orloff LA. Role of ultrasound in thyroid disorder. Otolaryngol Clin North Am 2010;43(6):1209-1227.
[8] Chaudhary V, Bano S. Thyroid ultrasound. Indian Journal of Endocrinology and Metabolism 2013;17(2):219-227.
[9] Wong KT, Yolanda YP, Lee, et al. Thyroid gland. In: Ahuja AT, ed. Diagnostic ultrasound: head and neck. 1st edn. Amirsys Publishing 2014:p. 52.
[10] Wong KT, Ahuja AT. Benign thyroid conditions. In: Sofferman RA, Ahuja AT, eds. Ultrasound of the thyroid

and parathyroid glands. New York: Springer 2012:63-87.
[11] Grant EG, Tessler FN, Hoang JK, et al. Thyroid ultrasound reporting lexicon: white paper of the ACR thyroid imaging, reporting and data system (TIRADS) committee. J Am Coll Radiol 2015;12(12 Pt A):1272-1279.
[12] Kwak JY, Han KH, Yoon JH, et al. Thyroid imaging reporting and data system for US features of nodules: a step in establishing better stratification of cancer risk. Radiology 2011;260(3):892-899.
[13] Tessler FN, Middleton WD, Grant EG, et al. ACR thyroid imaging, reporting and data system (TI-RADS): white paper of the ACR TI-RADS committee. J Am Coll Radiol 2017;14(5):587-595.
[14] Ebeed AE, Romeih MA, Refat MM, et al. Role of ultrasound, color Doppler, elastography and Micropore imaging in differentiation between benign and malignant thyroid nodules. Egypt J Radiolo Nucl Med 2017.
[15] Kwak JY, Kim EK. Ultrasound elastography for thyroid nodules: recent advances. Ultrasonography 2014;33(2):75-82.
[16] Aghini-Lombardi F, Antonangeli L, Martino E, et al. The spectrum of thyroid disorders in an iodine-deficient community: the pescopagano survey. J Clin Endocrinol Metab 1999;84(2):561-566.
[17] Laurberg P, Pedersen KM, Hreidarsson A, et al. Iodine intake and the pattern of thyroid disorders: a comparative epidemiological study of thyroid abnormalities in the elderly in Iceland and in Jutland, Denmark. J Clin Endocrinol Metab 1998;83(3):765-769.
[18] Vanderpump MP. The epidemiology of thyroid disease. Br Med Bull 2011;99:39-51.
[19] Unnikrishnan AG, Menon UV. Thyroid disorders in India: an epidemiological perspective. Indian J Endocrinol Metab 2011;15(Suppl 2):S78-81.
[20] Menon UV, Sundaram KR, Unnikrishnan AG, et al. High prevalence of undetected thyroid disorders in an iodine sufficient adult south Indian population. J Indian Med Assoc 2009;107(2):72-77.
[21] Christensen SB, Tibblin S. The reliability of the clinical examination of the thyroid gland. Ann Chir Gynaecol 1985;74:151-154.
[22] Carroll BA. Asymptomatic thyroid nodules: incidental sonographic detection. AJR Am J Roentgenol 1982;133(3):499-501.
[23] Stark DD, Clark OH, Gooding GA, et al. High-resolution ultrasonography and computed tomography of thyroid lesions in patients with hyperparathyroidism. Surgery 1983;94(6):863-868.
[24] Horlocker U, Hay EJ, James EM, et al. Prevalence of incidental nodular thyroid disease detected during high-resolution parathyroid ultrasonography. In: Medeiros-Neto G, Gaitan E, eds. Frontiers in thyroidology, Vol II. Proceedings of the Ninth International Thyroid Congress, Sao Paulo, Brazil 1985. New York: Plenum 1986:1309-1312.
[25] Woestyn J, Afschrift M, Schelstraete K, et al. Demonstration of nodules in the normal thyroid by echography. Br J Radmol 1985;58(696):1179-1182.
[26] Oertel JE, Klinck GH. Structural changes in the thyroid glands of healthy young men. Med Ann DC 1965;34:73-77.
[27] Brander A, Vilkinkoski P, Nickels J, et al. Thyroid gland: US screening in middle-aged women with no previous thyroid disease. Radiology 1989;173(2):507-510.
[28] Brander A, Vilkinkoski P, Nickels J, et al. Thyroid gland: US screening in a random adult population. Radiology 1991;181(3):683-687.