

TWO NEWER METHODS OF PTERYGIUM SURGERY- A COMPARATIVE STUDY

Veerendra Bhimashankar Atnoor¹, Sachin Sundarrao Pandhare², Sonali Ashok Bhosale³

¹Associate Professor, Department of Ophthalmology, Dr. V. M. Medical College, Solapur.

²Assistant Professor, Department of Ophthalmology, Dr. V. M. Medical College, Solapur.

³Senior Resident, Department of Ophthalmology, Dr. V. M. Medical College, Solapur.

ABSTRACT

BACKGROUND

This study aims to evaluate the surgical treatment of pterygium by pterygium excision with conjunctival autografting without glue without sutures and preoperative subconjunctival injection of 5-fluorouracil with bare sclera technique.

MATERIALS AND METHODS

Sixty eyes of 60 consecutive patients with primary progressive pterygium were selected, who presented to our hospital with primary progressive pterygium. Group A consisted of pterygium excision with conjunctival autografting without glue without suture and Group B consisted of sub conjunctival injection of 5-fluorouracil, one day before pterygium excision with bare sclera technique. Thirty patients were included in each group and a comparison was made between these groups. Patients were followed up from at least 6 months to 18 months.

RESULTS

Recurrence rate of pterygium after conjunctival autografting without glue without suture was zero % with average duration of follow up 11.70 +/- 3.14 months and recurrence rate in bare sclera technique with preoperative 5-fluorouracil found was 6.6% with average duration of follow up 10.53 +/- 3.53 months.

CONCLUSION

Both the methods i.e. conjunctival autografting without glue without suture and subconjunctival injection of 5-FU one day before pterygium excision with bare sclera technique are useful alternatives for treatment of pterygium but conjunctival autografting without glue without suture is marginally superior to subconjunctival injection of 5-FU one day before pterygium excision with bare sclera technique in terms of recurrence rate and complications.

KEYWORDS

Pterygium, Autograft, Glue, 5 Fluorouracil.

HOW TO CITE THIS ARTICLE: Atnoor VB, Pandhare SS, Bhosale SA. Two newer methods of pterygium surgery- a comparative study. J. Evid. Based Med. Healthc. 2018; 5(4), 367-372. DOI: 10.18410/jebmh/2018/74

BACKGROUND

Conjunctival autografting seems to be an effective method for pterygium treatment that effectively prevents recurrence. Traditionally the conjunctival autograft is secured in place with absorbable or non-absorbable sutures, however suturing is more time consuming, technically more demanding and suture induced redness and irritation are frequent symptoms.^{1,2} To prevent this, ophthalmic surgeons are switching over to sutureless surgery with fibrin glue which not only shortens the surgery but also reduces postoperative discomfort.¹ But the major limitation about fibrin glue is cost and its availability is an issue, cold chain has to be maintained meticulously and rarely anaphylactic reactions can occur with fibrin glue.² So the newer technique

conjunctival autografting without glue without sutures is being tried now a days with natural clotting mechanism of patient's own blood to reduce postoperative discomfort. It also reduces the surgery time, is simple, economical and avoids disadvantages of other methods of conjunctival autografting.³ In pterygium surgery mitomycin-c and 5-fluorouracil are used as an adjunct in several modalities like preoperative injection, intraoperative and postoperative application to prevent recurrence.^{4,5,6} Both the agents prevents pterygium recurrence by inhibiting fibroblast proliferation and contraction at the level of episclera.⁷ However intraoperative use of mitomycin-c is sometimes associated with vision threatening complications like glaucoma, corneal oedema, corneal perforation, scleral melting and cataract formation.⁸ Although some studies reported conjunctival and corneal necrosis, superficial keratitis, scleral granuloma with intraoperative use of 5-FU.⁷ The newer technique, subconjunctival injection of 5-fluorouracil allows exact dose delivery directly to the activated fibroblasts in subconjunctival space, where it can work directly on cells responsible for pterygium recurrence.⁹ Purpose of this study was to find out whether 1) A simpler technique like subconjunctival injection of 5-fluorouracil one day before pterygium excision with bare sclera technique

Financial or Other, Competing Interest: None.

Submission 02-01-2018, Peer Review 06-01-2018,

Acceptance 19-01-2018, Published 22-01-2018.

Corresponding Author:

Dr. Sachin Sundarrao Pandhare,

Flat No. 04, Math Sankul Society,

Civil Lines, Solapur-413002.

E-mail: sachin0259@gmail.com

DOI: 10.18410/jebmh/2018/74



gives result comparable to conjunctival autograft in terms of recurrence rate and other complications 2) Whether this technique is associated with complications like ocular surface toxicity seen with its intraoperative application and with the use of mitomycin-c in pterygium surgery. In this study, we evaluated and compared two new different therapeutic methods for pterygium excision i.e. preoperative subconjunctival 5-fluorouracil, one day before pterygium excision with bare sclera technique and conjunctival autografting without glue without sutures.

Aims and Objectives

- To evaluate the surgical treatment of pterygium by-
 - Pterygium excision with Conjunctival autografting (without glue without sutures) and
 - Subconjunctival injection of 5-fluorouracil, one day before pterygium excision with bare sclera technique.
- Compare the two techniques with regards to-
 - Recurrence rate of pterygium.
 - Complications.

MATERIALS AND METHODS

Study period was from December 2013 to June 2015.

Patients

Sixty eyes of 60 consecutive patients with primary progressive pterygium were selected, who presented to our hospital with primary progressive pterygium.

Group A

Pterygium excision with conjunctival autografting without glue without suture (30 patients).

Group B

Subconjunctival injection of 5-fluorouracil (0.1 cc of 12.5 mg/ml), one day before pterygium excision with bare sclera technique (30 patients). 5- FU is available as injection FLURACIL, 500 mg/10 ml cost of one vial is 17 rupees. We are giving it as 12.5 mg/ml by diluting it as 1:3 with distilled water.

Patients were followed up from at least 6 months to 18 months.

Inclusion Criteria

- The patient presented to ophthalmology OPD in our hospital and diagnosed as having primary progressive pterygium.
- The patient who met the indications of surgical treatment.

Exclusion Criteria

- Patient having recurrent pterygium.
- Patient having atrophic pterygium.
- Patient having uveitis, glaucoma, scleritis.
- Follow up less than 6 months.

- Patient having coexistent conjunctival diseases. A clinical photograph of every patient was taken preoperatively and postoperatively on each follow up visit. Patients followed up at 1st postoperative day, one week, one month, three months, six months, twelve months and eighteen months.

RESULTS

Sr. No.	Group	Surgical technique	No. of eyes
1.	A	Co Conjunctival autografting without glue without suture	30
2.	B	Bare sclera with pre-operative 5-Fluorouracil	30

Table 1. Distribution of Eyes According to Technique of Surgery

Table 1. Shows number of eyes and group as per the surgical technique. Sixty eyes of 60 patients were included in the study.

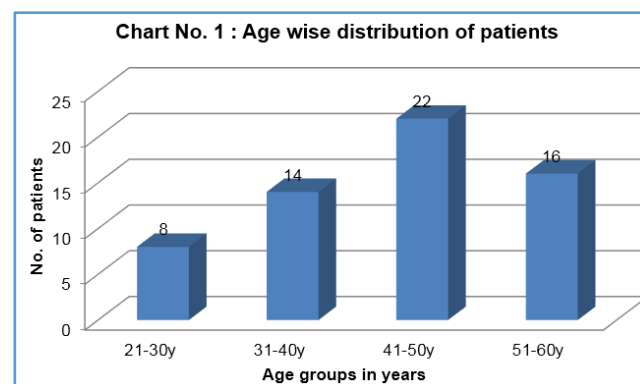


Chart 1. Shows Age Wise Distribution. Maximum Numbers of Patients 38 (63.33%) were Noted in Age Group 41-60 Years

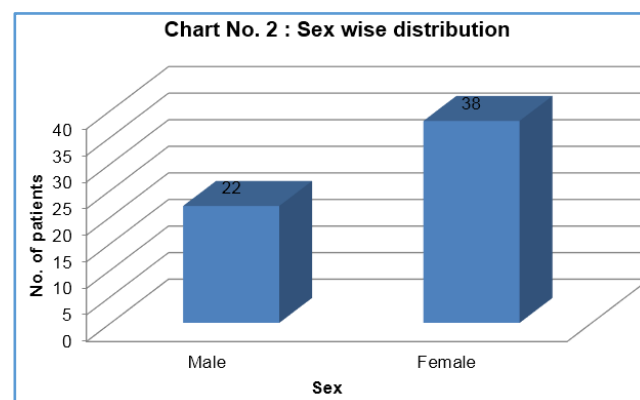


Chart 2. Shows Sex Wise Distribution. Out of 60 Patients 22 (36.66%) were Males and 38 (63.33%) were Females

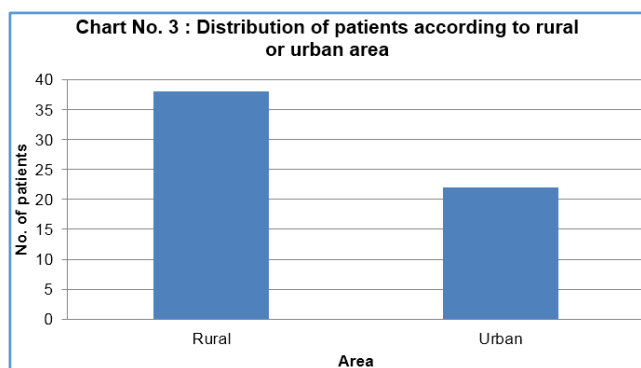


Chart 3. Shows Distribution of Patients According to Living Environment. Out of 60 Patients, 38 (63.33%) were Residing in Rural Areas While 22 (36.33) Patients were Residing in Urban Areas

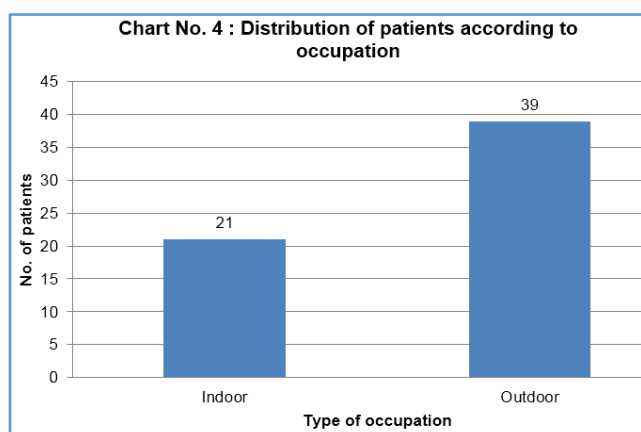


Chart 4. Shows Occupation Wise Distribution. Out of 60 Patients 21 (35%) Patients had Indoor Occupations and 39 (65%) Patients had Outdoor Occupations

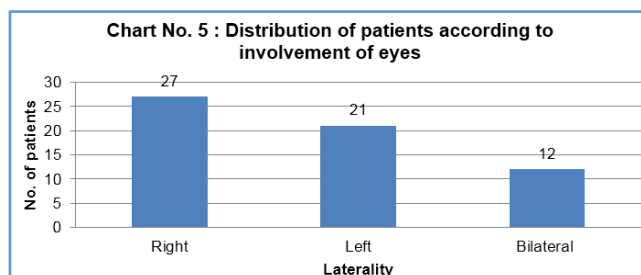


Chart 5. Shows Distribution of Eyes According to Laterality. Out of 60 Patients 27 (41.66%) Patients Had Pterygium in Only Right Eye, 21 (23%) in Only Left Eye and 12 (20%) Patients had Bilateral Pterygia. It Means out of 60, 48(80%) Patients had Unilateral Pterygia

Sr. No.	Group	Surgical Technique	Average Duration of Surgery (Minutes)
1.	A	Conjunctival autografting without glue without suture	28.73± 1.74
2.	B	Bare sclera with pre-op 5-FU	17.10 ±1.90

Table 2. Average Duration of Surgery of both Groups

Table No. 2 shows average surgical time for pterygium excision with bare sclera with pre-operative subconjunctival 5-FU was 17.10+1.90 minutes, which includes duration of both for subconjunctival injection of 5-FU and pterygium excision with bare sclera technique. Average surgical time for group Ai. Conjunctival autografting without glue without suture was 28.73+1.74 minutes which includes duration of surgery and waiting time after graft was placed over scleral bed(waiting time for adherence of graft was about 6-8 minutes).

Sr. no.	Group	Surgical Technique	No. of Eyes Operated	Mean follow up (months)
1.	A	Conjunctival autografting without glue without suture	30	11.70 ± 3.14
2.	B	Bare sclera with pre-op 5-FU	30	10.53 ± 3.53

Table 3. Mean Follow up Period of Both Groups

Table No. 3 shows mean follow up period of both groups. All patients were followed up from at least 6 months to 18 months after surgery. There is no statistically significant difference between follow up period of two groups (t test = 1.37; p> 0.05).

Sr. No.	Group	Surgical technique	No. of Eyes Operated	No. of Eyes with Recurrence
1.	A	Conjunctival autografting without glue without sutures	30	No recurrence
2.	B	Bare sclera with pre-op 5-FU	30	2 (6.66%)

Table 4. Pterygium Recurrence Rate of Two Techniques

Statistically there is no significant difference between recurrence rates by above two surgical techniques (z test =1.43, p>0.05).

DISCUSSION

Recently adjunctive 5-FU and mitomycin-c have become more commonly used antimitotic drugs in preventing pterygium recurrence. The newer technique of subconjunctival injection of 5-FU allows exact dose delivery to directly to the activated fibroblast in subconjunctival space, where it can work directly on the cells responsible for pterygium recurrence without damaging surface epithelial stem cells and limbal stem cells, which play no role in pterygium formation.

The aim of this study includes finding out whether preoperative subconjunctival 5-FU reduces recurrences rate after bare sclera excision to acceptable level without causing significant complications and whether it can be considered as a good alternative to standard techniques of pterygium management.

In the present study youngest patient was 23 years old and oldest patient was 57 years old. Mean age of group A patient was 38.17 ± 9.40 years and that of group B was 47.90 ± 7.08 years. Age group of 41-50 years consists of 36.66% patients and 26.66% patients in the age group of 51-60 years. Gazzard et al⁷ in their study found that prevalence rates of pterygium in subjects over 51 years were 6 times higher than of 21-30 years age group.

In the present study out of 60 patients, 22 (36.66%) patients were males and 38 (63.33%) patients were females. In group A, 13 males and 17 females and in group B, 9 males and 21 females were present. More number of females as compared to males were found in present study especially in rural areas. In present study also wherein 63.33% patients were living in rural areas where both males and females do outdoor work in the form of farming.

Out of sixty patients, 39 (65%) patients were pursuing outdoor occupations and 21 (35%) patients were pursuing indoor occupations in the present study. Outdoor occupation is a known risk factor for the development of pterygium, reason being increased exposure to heat, dry, dusty environment and also UV radiation.

In the present study 38 (63.33%) patients were residing in rural areas and remaining 22(36.66%) were from urban areas. Thus, from present study it can be stated that pterygium is more common in rural residents than urban residents. This may be due to the fact that most of the people in rural areas have farming as a occupation in which there is prolonged sun exposure as well as exposure to dry, dusty environment which are important etiological factors of pterygium.

Out of 60 patients, 27(45%) patients had pterygium only in right eye, 21(35%) patients had pterygium only in left eye and 12(20%) patients had bilateral pterygium. There was slight right preponderance.

Average surgical time for group B i.e. pterygium excision with bare sclera with pre-operative subconjunctival injection of 5-fluorouracil was 17.10 ± 1.90 minutes, which included duration both for subconjunctival injection of 5-FU and pterygium excision with bare sclera technique. Average surgical time for group A i.e. conjunctival autografting without glue without suture was 28.73 ± 1.74 minutes which includes duration of surgical technique as well as time (6-8 minutes) taken by graft to stick over the bare sclera. Surgical time for conjunctival autografting without glue without suture was significantly more. However pre-operative subconjunctival injection of 5-FU before bare sclera excision was two stage procedure. One stage is pre-operative subconjunctival injection of 5-FU one day before bare sclera technique and second stage is bare sclera excision after 24 hours of subconjunctival injection of 5-FU. So the patient had to visit operation room twice which is a major factor to be considered.

In our study, recurrence rate was 6.66% in the 5-FU one day before bare sclera technique i.e. group B while there was no recurrence in conjunctival autografting without glue without sutures i.e. group A.

Sr. no.	Year	Author	Follow up period	Recurrence rate
1.	2010	Wit D et al ¹⁰	12 months	No recurrence
2.	2011	Mitra S et al ¹¹	6 months	No recurrence
3.	2012	Malik KPS et al ¹²	9 months	2.5%
4.	2012	Sayli B Kulthe et al ¹³	6 months	No recurrence
5.	2013	Majumdar CS et al ¹⁴	6 months	2.13%
6.	2014	Jawed Alam et al ¹⁵	6 months	No recurrence
7.	2014	Kurian A et al ¹⁶	12 months	6.25%
8.	2015	Present study	12 months	No recurrence

Recurrence Rates in other Studies After Conjunctival Autografting Without Glue Without Suture

In our study in pterygium excision with bare sclera with pre-operative subconjunctival 5-FU the recurrence rate was 6.66% at the mean follow up period of 10.53 ± 3.53 months. Both recurrences were detected at the 3 months follow up visit postoperatively.

Sr. No.	Timing of 5-FU application	Year	Author	Follow up	Re-currence rate
1.	Pre operative	2002	C A Shiratori et al ¹⁷	16 months	27.3%
2.	Post operative	2005	C O Bekibele et al ¹⁸	16 months	11.4%
3.	Intra operative	2008	Rehman et al ¹⁹	12 months	33.33%
4.	Intra operative	2012	Kareem AA et al ²⁰	18 months	18%
5.	Intra operative	2013	Krishna Kuldeep et al ⁷	12 months	25%
6.	Intra operative	2013	Josephine et al ²¹	12 months	27.27%
7.	Pre operative	2015	Present Study	12 months	6.66%

Recurrence Rate in Various Studies Using 5-FU as Adjunct Perioperatively to Bare Sclera Technique

In group A, all patients had conjunctival congestion post-operatively due to surgical trauma which decreased with topical steroid antibiotic eye drops. One patient had subconjunctival haemorrhage which cleared in a week after surgery. Two patients had graft oedema; two patients had graft haemorrhage on first postoperative day which cleared with topical steroid antibiotic eye drops till 1 week postoperatively. One patient had graft retraction on first postoperative day. Two patients had graft loss on the first post-operative day which was followed up without any intervention and had no recurrence within study period. One

patient from group A had conjunctival granuloma at the donor site on first week post-operatively which resolved completely with topical steroid and lubricating eye drops on 1 month follow up.

In group B, all patients had conjunctival congestion post-operatively due to surgical trauma which decreased with topical steroid antibiotic eye drops. Two patients had subconjunctival haemorrhage after subconjunctival injection of 5-FU which cleared in a week after surgery. No patients had any signs of conjunctival or corneal staining after subconjunctival injection of 5-FU in any follow up visit. Two patients from group B had conjunctival granuloma at the bare sclera site on first week post-operatively which resolved completely with topical steroid and lubricating drops on 1 month follow up. None of the patients had any serious complications like superficial keratitis, corneal opacity, scleral granuloma, conjunctival necrosis, symblepharon which are associated with intraoperative topical application of 5-fluorouracil or those associated with intraoperative application of mitomycin-c.

SUMMARY AND CONCLUSION

1. Maximum number of patients 38 (63.33%) were from age group 41-60 years.
2. More number of female patients 38 (63.33%) as compared to male 22 (36.66%) patients was found, especially in rural areas.
3. Unilateral involvement pterygium either right or left has more preponderance than bilateral involvement.
4. Majority (65%) of patients were pursuing outdoor occupations.
5. Majority (63.33%) of patients were residing in rural area.
6. Average surgery time for conjunctival autografting without glue without suture was more compared to subconjunctival injection of 5-FU, one day before pterygium excision with bare sclera technique.
7. Subconjunctival injection of 5-FU, one day before pterygium excision with bare sclera technique is associated with more recurrence rate (6.66%) than conjunctival autografting without glue without suture showing no recurrence.
8. Neither surgical technique was found to be associated with any serious vision threatening complications.

Thus from the present study it is concluded that conjunctival autografting without glue without suture is safe, simple, economical, effective and less time consuming than other methods. The recurrence rate is also very low.

Subconjunctival 5-FU one day before pterygium excision with bare sclera is simple, safe, economical, less time consuming technically less demanding and effectively reduces recurrence to acceptable levels. It has definite role in patients with recurrent pterygium, large double headed pterygia, patients with glaucoma who may require filtration surgery in future and combined pterygium with cataract patients. It has a potential to replace other adjunctive drugs like mitomycin-c, triamcinolone because it is readily

available, cheaper than other drugs, and reduces recurrence of pterygium effectively with less and mild complications. As these drugs can produce deleterious effect after long period of application longer follow up is required in these cases. So larger study with large number of patients with longer follow up is needed.

Both these methods are useful alternatives for treatment of pterygium but conjunctival autografting without glue without suture is marginally superior to subconjunctival injection of 5-FU one day before pterygium excision with bare sclera technique in terms of recurrence rate and complications.

REFERENCES

- [1] Karalezli A, Kucukerdonmez C, Akova Y, et al. Fibrin glue versus sutures for conjunctival autografting in pterygium surgery: a prospective comparative study. *Br J Ophthalmol* 2008;92(9):1206-1210.
- [2] Javadekar SD, Deokrishna S, Sharma A. Autologous fibrin glue versus sutures for conjunctival autografting in pterygium surgery. *International Journal of Recent Trends in Science and Technology* 2013;7(1):1-5.
- [3] Kumar SV, Waikar S, Srivastava VK. Conjunctival limbal autograft transplantation in pterygium surgery by natural haemostasis. *Med J Armed Forces India* 2015;71(Suppl 1):S43-S45.
- [4] Akarsu C, Taner P, Ergin A. 5-fluorouracil as chemoadjuvant for primary pterygium surgery: preliminary report. *Cornea* 2003;22(6):522-526.
- [5] Zaky KS, Khalifa YM. Efficacy of preoperative injection versus intraoperative application of mitomycin in recurrent pterygium surgery. *Indian J Ophthalmol* 2012;60(4):273-276.
- [6] Salustiano Correa E Silva R, Pereria Avila M, Rassi AR. Intra-operative use of 5-fluorouracil in pterygium surgery: a comparative. *Semin Ophthalmol* 2013;28(1):34-36.
- [7] Kuldeep K, Kumar Y, Singh P, et al. Comparison of surgical techniques for pterygium using mitomycin-C or 5-fluorouracil as adjuncts. *Journal of Evolution of Medical and Dental Sciences* 2013;2(44):8581-8590.
- [8] Rubinfeld RS, Pfister RR, Stein RM, et al. Serious complications of topical mitomycin-C after pterygium surgery. *Ophthalmology* 1992;99(11):1647-1654.
- [9] Donnenfeld ED, Perry HD, Fromer S, et al. Subconjunctival mitomycin C as adjunctive therapy before pterygium excision. *Ophthalmology* 2003;110(5):1012-1016.
- [10] de Wit D, Athanasiadis I, Sharma A, et al. Sutureless and glue-free conjunctival autograft in pterygium surgery: a case series. *Eye (Lond)* 2010;24(9):1474-1477.
- [11] Mitra S. Autoblood as tissue adhesive for conjunctival autograft fixation in pterygium surgery. Poster presented at the Annual Meeting of the American Academy of Ophthalmology, Orlando. Oct 22 and 23, 2011.

- [12] Malik KP, Goel R, Gutpa A, et al. Efficacy of sutureless and glue free limbal conjunctival autograft for primary pterygium surgery. *Nepal J Ophthalmol* 2012;4(2):230-235.
- [13] Kulthe SB, Bhosale AP, Patil PU, et al. Is the surgical technique of a sutureless and glue-free conjunctivolimbal auto graft after pterygium excision complications free? *Med J DY Patil Univ* 2015;8(3):308-312.
- [14] Majumder CS. A prospective study on? pterygium excision and conjunctival autograft-without suture, without glue? *J Clin Exp Ophthalmol* 2014;5(3):146.
- [15] Ascher KW, Anderson JR. A pterygium map (Discussion) *Acta XVII Conc. Ophthal* 1954;3:1640-1641.
- [16] Kurian A, Reghunadhan I, Nair KG. Autologous blood versus fibrin glue for conjunctival autograft adherence in sutureless pterygium surgery: a randomised controlled trial. *Br J Ophthalmol* 2015;99(4):464-470.
- [17] Shiratori CA, Erika H, Artioli S, et al. Preoperative 5-fluorouracil infiltration in pterygium surgery. *Arq Bras Ophthalmol* 2003;66(4):499-503.
- [18] Bekibele CO, Baiyeroju AM, Olusanya BA, et al. Pterygium treatment using 5-FU as adjuvant treatment compared to conjunctiva autograft. *Eye (Lond)* 2008;22(1):31-34.
- [19] Rahman LU, Baig MA, Islam QU. Prevention of pterygium recurrence by using intra-operative 5-fluorouracil. *Pak Armed Forces Med J* 2008;58(1):57-61.
- [20] Kareem AA, Farhood QK, Alhammami HA. The use of antimetabolites as adjunctive therapy in the surgical treatment of pterygium. *Clin Ophthalmol* 2012;6:1849-1854.
- [21] Ubah JN, Gbadegesin OG. A comparison of recurrence rates of pterygium after excision with conjunctival autograft and 5-fluorouracil. *International Journal of Biology and Biological Sciences* 2013;2(5):88-90.