

**TRIAD OF SENSORY FINDINGS LOCALISES TO CORTEX- ANALYSIS OF 5 CASES**

Beena Vasanthi Vijayan<sup>1</sup>, Gourisankar Peringattu Thankappan Nair<sup>2</sup>, Vijayan Chandrathil Parameswaran Nair<sup>3</sup>

<sup>1</sup>Associate Professor, Department of Neurology, Government Medical College, Kottayam, Kerala.

<sup>2</sup>Senior Consultant, Department of Radiologist, Hindlabs, MCH, Kottayam.

<sup>3</sup>Professor and Co-Convener, Nodal Centre for Faculty Development, Government Medical College, Kottayam.

**ABSTRACT****BACKGROUND**

A fifty-two-year-old man presented with acute onset right lower facial and ear numbness and facial weakness, after two weeks of the onset of symptoms. Examination revealed right central facial palsy, depressed corneal reflex and hemifacial sensory loss (mild over forehead, severe over lower cheek, jaw & pinna) Localization was proposed in brainstem Vs Cerebellopontine angle. MRI Brain revealed infarct in peri Rolandic area; four more patients had similar presentation over next few years.<sup>1</sup> Core findings were ipsilateral graded facial sensory impairment with central facial palsy, ear involvement & impaired corneal reflex. Four had spastic hand.

Hypothesis- Cortical lesions can have LMN- like presentation; impairment of facial and external ear (pinna) sensations, and attenuated corneal reflex.

**MATERIALS AND METHODS**

Settings and Design- Patients presenting to the Neurology OPD with facial weakness and isolated sensory loss of face were admitted and evaluated with detailed neurological examination, including facial & ear sensations and corneal reflex; Stroke work up & MRI Brain with MRA was done. They were treated and kept under follow up.

**RESULTS**

Patients with post central gyrus infarct had uniformity in presentation, graded sensory loss over face, depressed corneal reflex & ear involvement, had uniformity in presentations and medical help seeking usually were delayed. Two had lower face (mandibular region) severely affected; while three had maxillary involvement. Spastic hand weakness was found in four.

**CONCLUSION**

Cortical lesions can produce LMN-like sensory phenomena, of face. Corneal reflex abnormality & ear involvement occur in cortical lesions. Ear representation is closer to lower face in sensory cortex. Four out of five patients had spastic hand in this series. Hence in spastic hand due to cortical lesions, triad of sensory findings should be specifically elicited.

**KEYWORDS**

Cortical Stroke, Localization, Graded Facial Sensory Loss, Corneal Reflex, Ear-Representation, Spastic Hand.

Keymessages- LMN type of facial sensory involvement occur in postcentral gyrus lesions producing a triad of clinical findings- graded facial sensory involvement, sluggish corneal reflex & pinna affection. This helps in localization. Stroke if involving precentral gyrus, (occurring in four of five patients) is associated with central facial palsy & spastic hand.

**HOW TO CITE THIS ARTICLE:** Vijayan BV, Nair GPT, Nair VCP. Triad of sensory findings localises to cortex-analysis of 5 cases. J. Evid. Based Med. Healthc. 2018; 5(7), 570-574. DOI: 10.18410/jebmh/2018/117

**BACKGROUND**

Graded facial sensory involvement occurs in trigeminal neuropathy and intramedullary lesions; Sensory findings of face, limb and trunk occur in brain stem & thalamic lesions, isolated truncal sensory involvement localizes to thalamus.<sup>2</sup> LMN like, sensory involvement as pseudo ulnar or pseudo radial type, is described in cortical strokes.<sup>3</sup> Focal sensory syndrome confined to tip of tongue & lower lip.<sup>4</sup> is described.

Cortical stroke causing facial sensory loss, with gradation & simultaneous involvement of ear was not described previously.

*Financial or Other, Competing Interest: None.*

*Submission 22-01-2018, Peer Review 29-01-2018,*

*Acceptance 05-02-2018, Published 07-02-2018.*

*Corresponding Author:*

*Dr. Beena Vasanthi Vijayan,*

*Associate Professor, Department of Neurology,*

*Government Medical College, Kottayam, Kerala.*

*E-mail: beenavdr@gmail.com*

*DOI: 10.18410/jebmh/2018/117*

**MATERIALS AND METHODS**

Subjects seen at Neurology OPD, fulfilling the criteria were admitted, subjected to detailed neurological examination, including facial and external ear sensations for fine touch, deep touch, temperature (cold 20°C and warm 40°C) and corneal reflex and taste sensations. General systemic examination, cardiac evaluation and workup for aetiology and risk factors of stroke were carried out.

**Setting-** Neurology Ward, Govt. Medical College, Kottayam.

**Study Period-** July 2014 to 2017 (completion of five patients).

**Inclusion Criteria**

1. History of acute onset of facial sensory symptoms
2. History of acute onset of facial weakness
3. Conscious and alert
4. Neuroimaging (MRI Brain) showing cortical infarcts



**Exclusion Criteria**

1. Hemisensory loss
2. Hemiplegia.
3. Aphasia
4. Features of posterior circulation stroke like vertigo, vomiting, ataxia or crossed hemiplegia.

**RESULTS**

Four were males and one was female. The youngest was forty-six; oldest sixty-six. Three had left sided and two had right sided symptoms. The delay to seek medical help was seen in all; shorter, two weeks to longer, six weeks. Two had TIA earlier; and four (males) had other risk factors for stroke than age, in the form vascular disease and smoking.

The sensation of touch was appreciated over whole of face; while temperature and pain were significantly affected over the lower / middle part of the face and minimally

affected over the upper part of the face (<20% was appreciated on lower face and >70% on upper face on a graded scale). The sensory testing of external ear was severe in gradation. Intraoral numbness was reported in three, but taste was normally appreciated by all. Corneal reflex was sluggish and delayed as compared to the normal side for all.

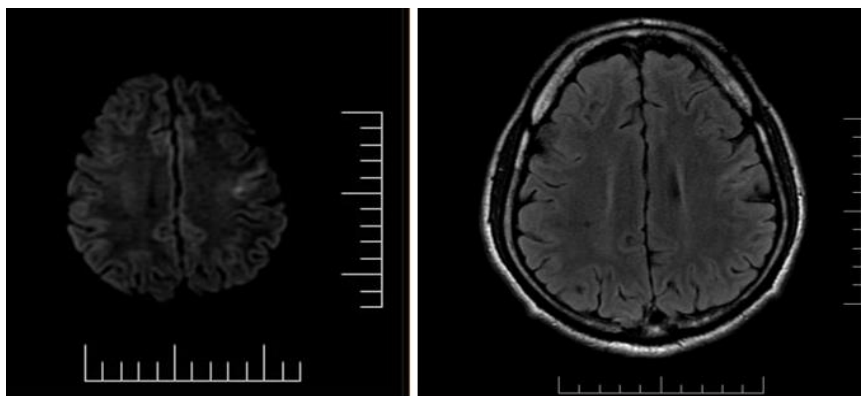
Four of the subjects had spastic hand weakness, which was noticed at the time of onset of facial symptoms.

Investigations did not reveal Carotid stenosis or cardiac source of embolism. All subjects presented late, about two to six weeks of onset; reported facial numbness as disturbing & fearful phenomena. Additional finding noteworthy is spastic weakness of hand in four of five. All were counselled for risk factors and initiated on antiplatelets and kept under follow up. Both sensory and motor improvement is noticed in three; one is awaited and one lost to follow up.

Sl. No.	Age	Sex	Symptoms; time of presenting – weeks of onset	Signs	MRI Brain	Follow up 6 Months	Follow up 1 year
1.	52	M	R face numbness & weakness; 2 weeks	R UMN facial palsy and graded sensory loss pinna + sluggish corneal reflex	DWI- L pre & post central gyrus-cortical infarct	Total improvement – motor & sensory upper face& corneal reflex; lower face & ear persisting	Normal
2.	46	M	Paraesthesia of L face & weakness; L hand spastic weakness  2 weeks	L central Facial palsy; facial graded sensory loss; sluggish corneal reflex; pinna involved; spastic hand;	Diffusion restriction - R precentral& post central gyrus-cortical infarct	Upper face sensory symptoms with corneal reflex improved; lower face, ear minimal improvement; hand weakness better	Awaited
3.	52	M	Paraesthesia-L face; spastic hand; 6 weeks	L face graded sensory loss; sluggish corneal reflex; pinna involved; hand spastic	DWI & Flair infarct R precentral & postcentral gyri-recent infarcts	Lost to follow up	
4.	55	F	L face paraesthesia & weakness, impaired corneal reflex; 2 months later L hand weakness; 6 weeks	L UMN facial palsy, graded sensory loss; sluggish corneal reflex; pinna involved; hand spastic	DWI & Flair - cortical hyperintensity in R pre, post central gyri & middle frontal gyri-recent infarcts	Upper facial sensations & corneal reflex normal. Mild symptom of lower face & ear. weakness of hand moderate improvement	Awaited
5.	66	M	R sided weakness, numbness with central facial palsy, facial sensory motor symptoms; limb improved; facial symptoms persisting; 4 weeks	R UMN facial palsy with graded sensory loss; sluggish corneal reflex; pinna involved. R hand spastic	DWI & Flair shows hyperintensity in L pre & post central gyri -recent cortical infarcts	Awaited	

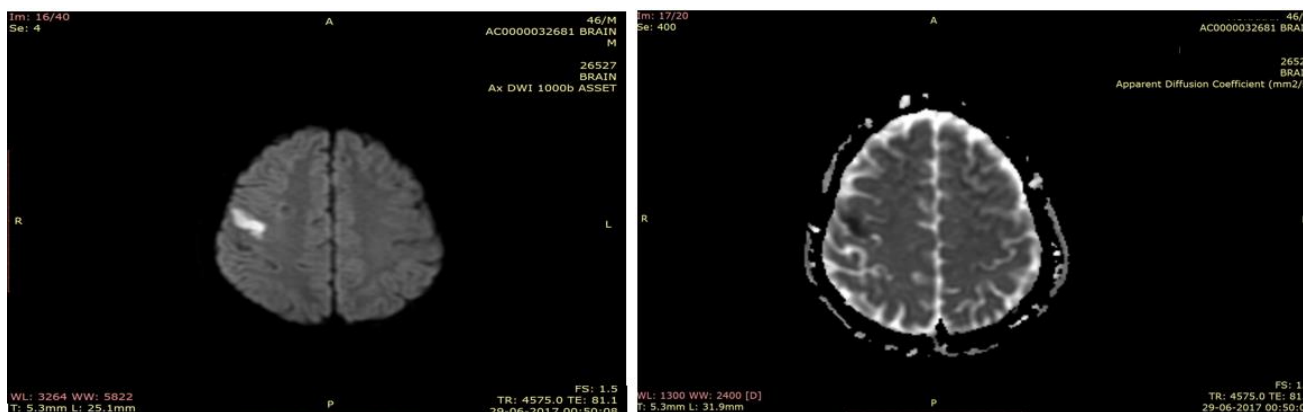
**Table 1. Clinical and Imaging Features of Subjects**

**Case 1**




**Figure (a) & (b) MRI Brain Diffusion Restriction- Left Pre & Post-central Gyri - Acute Cortical Infarct**

**Case 2**




**Figures (c) & (d) MRI Brain - Diffusion Restriction -Right Pre-Central Gyrus & Post-Central Gyrus s/o Acute Cortical Infarct**

**Case 3**



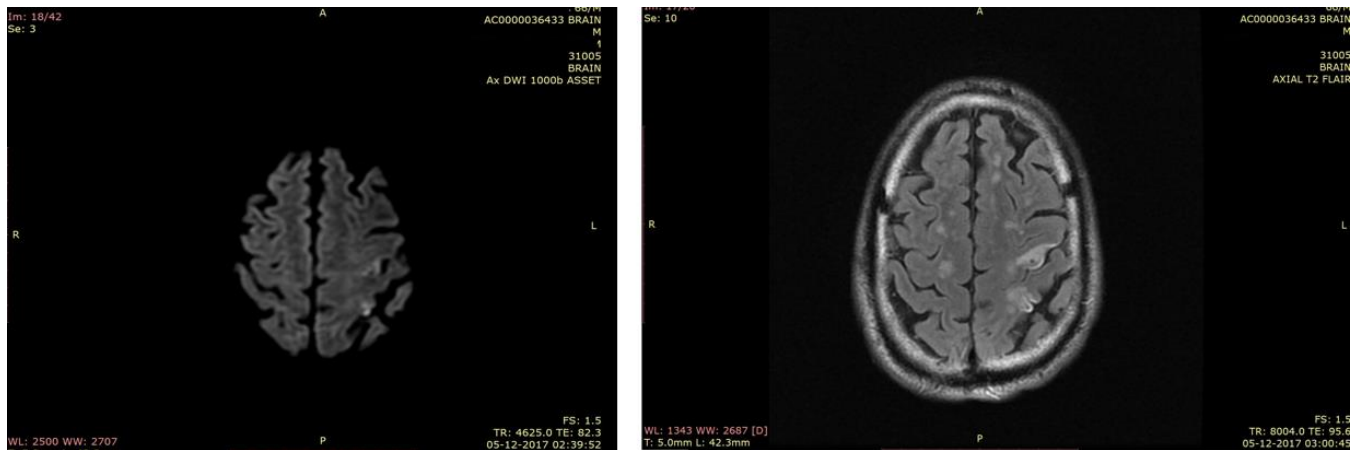
**Figure (e) & (f) Diffusion Weighted and Flair Images Showing Cortical Hyperintensity in Right Precentral & Post Central Gyrus - Subacute Cortical Infarcts**

**Case 4**



**Figures (g) & (h) DWI & Flair - Cortical Hyperintensity in R Pre- & Post-Central & Middle Frontal Gyri-Recent Infarcts**

## Case 5



**Figures (i) & (j) MRI - Hyperintensity DWI & Flair- L Pre- & Post-Central Gyri- recent Cortical Infarcts**

## DISCUSSION

Cortical involvement simulating nerve pattern involvement, e.g.; pseudo ulnar or radial neuropathy like presentation, in the hand.<sup>3</sup> thalamic or capsular affection causing hemisensory loss, medullary involvement causing crossed sensory pattern are described, but graded facial sensory loss, involving face is described presently for first time.<sup>1</sup> except by the authors as a case report. The sensory pattern found was almost like trigeminal sensory loss, affecting face but not confined to face alone as angle of jaw and ear were involved. There was selective sparing of upper part of face with regards to severity of symptoms, minimal paraesthesia around eyes and forehead, with more severe involvement of lower or middle face- maxillary and mandibular areas. Severity of involvement of external ear was similar to that of lower face. Corneal reflex was affected, delayed and weaker in comparison. All patients reported late, after variable period of two weeks to eight weeks. Recovery pattern was note-worthy, upper face improved rapidly over six weeks, while lower or middle continued to be symptomatic, with total improvement noted in three subjects, over about four to six months. There was intraoral numbness in three of five but taste was normally appreciated.

### Representation of Upper Face Vs Lower & Middle Face

1. The brain area activated by passive and active eye movement is located bilaterally in somato-sensory area extending into motor and premotor areas; it is here extra ocular movement proprioception is processed.<sup>3</sup> Human proprioception of extra ocular movement representation is in sensory-motor cortices of both hemispheres. This bilateral representation in somato-sensory cortex extending into premotor cortex suggests integrative nature of eye position signals from two eyes and probably is mechanism for coordinated yoked movements of eye muscles; on command; known as efference copy, and volition.<sup>5</sup> This could be the reason why minimal involvement and rapid improvement of upper facial sensation occurs.

2. Mechanical stimulation of forehead and lower lip of one side in 14 healthy subjects with MRI showed areas corresponding to upper and lower face relayed sensory signals to contralateral SI (primary somato-sensory cortex) & SII (secondary somato-sensory cortex), and they overlapped. But ipsilateral representation is different. Lower face activated contralateral sensory cortex, while upper face activated SI and bilateral SII, suggesting there are distinct type of cortical representations within facial territories.<sup>6</sup>
3. Magnetic encephalographic (MEG) studies show tactile information is first received in contralateral SI; then it flows to contralateral SII; Ipsilateral SII is activated initially by contralateral SI and then SII. Majority of SII neurons display bilateral receptive fields, giving idea of information processing in healthy humans.<sup>6</sup> This could add upon the cause of relative sparing and early improvement of upper face and minimal corneal reflex involvement with its early recovery.
4. In nonhuman primates, stimulation with air puff over face, activation of primary, secondary somato-sensory areas and large cortical network of prefrontal, premotor, parietal, temporal, cingulate, striate, and extra striate visual areas occurred. Within large cortical network, there is subnetwork in parieto-temporo-prefrontal appearing to represent visual space around head.<sup>7</sup> There are several cortical areas representing touch to centre of face and periphery, which in absence of definite topographical organization, suggest functional segregation to process information regarding tactile sources, which have ecological significance, which is important for survival.
5. Afferent corneal reflex is lost in peripheral or pontomedullary lesions; but due to suprasedgmental modulation, reflex is modified, in cortical lesions. Cornea responds only to pain & somatotopic representation to painful stimuli is in primary somatosensory area SI, contralaterally. As there is extensive representation of cornea, contralaterally and ipsilaterally, corneal reflex is.<sup>8</sup> relatively involved. This also explains early recovery of corneal reflex.

**Explanation for Graded Sensory Involvement-** Due to significance of yoked ocular muscle proprioception & important special sensory organ, eye with vulnerable cornea, upper face is bilaterally and extensively represented, there is minimal sensory symptom & signs of upper face. Hence upper face quickly recovers from insult.

**Significance of Graded Facial Sensory Loss & Ear involvement-** Graded sensory loss thus localizes to somatosensory cortex, suggesting bilateral and extensive representation of upper face.

Pinna is supplied by five different nerves,<sup>9</sup> branches from mandibular, facial, glossopharyngeal, vagus, and spinal nerves, greater auricular, lesser occipital. When face and ear involvement occur simultaneously, it is considered not due to structural lesion. But, in all five cases, pinna was involved.

Stimulation studies suggest ear areas in SI has variability between subjects, which is located in border between neck and face.<sup>10</sup>

In five subjects, pinna was involved as severe as lower face, and symptoms persisted after improvement of upper face, suggesting area of external ear in SI is near lower face area.

**Spastic Hand-** Four of five patients, there is ipsilateral spastic weakness of hand. Hence all patients with spastic hand weakness, due to stroke, facial & ear sensation with corneal reflex should be tested.

Localization in neurology evolved by strokes and in strokes. It is proposed that in cortical strokes involving postcentral gyrus, triad of clinical findings, graded sensory involvement of face, sluggish corneal reflex and external ear (pinna) involvement occurs localizing infarct. If affecting precentral gyrus also (which occurred in four of five patients,) it is associated with central facial palsy and spastic hand.

## CONCLUSION

Trigeminal neuropathy like (Nerve pattern) sensory abnormality can occur in cortical lesions of post-central gyrus. Differentiating features are gradation in sensory abnormalities within face and involvement of external ear. If precentral gyrus is also involved, which is usual, it is associated with central facial palsy and spastic hand weakness. The upper face and eyes appear to have bilateral representation; proved by electrophysiology and stimulation

studies but evidence is shown clinically by the present one. The ear representation is near face.

All patients with spastic hand weakness should be examined specifically for graded facial sensory loss, corneal reflex and external ear sensory abnormalities, as this forms a triad of findings, localizing lesion to cerebral cortex.

## REFERENCES

- [1] Beena V, George S, Gourisankar, et al. Cortical Stroke causing graded facial sensory involvement. *Journal of Evidence Based Medicine and Healthcare* 2014;1(17):2227-2231.
- [2] Fisher CM. Pure sensory stroke and allied conditions. *Stroke* 1982;13(4):434-447.
- [3] Cerrato P, Lentini A, Baima C, et al. Pseudo-ulnar sensory loss in a patient from a small cortical infarct of the postcentral knob. *Neurology* 2005;64(11):1981-1982.
- [4] Shimohata M, watanabe Y, Tanaka H. Numbness in the tip of the tongue and lower lip caused by thalamic haemorrhage. *J Stroke Cerebrovasc Dis* 2014;23(3):557-559.
- [5] Belslev D, Albert NB, Miall C. Eye muscle proprioception is represented bilaterally in the sensorimotor cortex. *Hum Brain Mapp* 2011;32(4):624-631.
- [6] Eickhoff SB, Grefkes C, Fink GR, et al. Functional lateralization of face, hand & trunk representation in anatomically defined human somatosensory areas. *Cerebral Cortex* 2008;18(12):2820-2830.
- [7] Moulton EA, Becera L, Rosenthal P, et al. An approach to localizing corneal pain representation in human somatosensory cortex. *PLoS ONE* 2012;7(9):e44643.
- [8] Wardak C, Guipponi O, Pinede S, et al. Tactile representation of the head and shoulders assessed by fMRI in the nonhuman primate. *Journal of Neurophysiology* 2016;115(1):80-91.
- [9] Ueno N, Sudo H, Hattori Y, et al. Innervation of the external ear in humans and the musk shrew. *Nihon Jibiinkoka Gakkai Kaiho* 1993;96(2):212-218.
- [10] Nihashi T, Kakigi R, Miki K, et al. Effect of tactile interference stimulation of the ear in human primary somatosensory cortex: a magneto encephalographic study. *Clinical Neurophysiology* 2003;114(10):1866-1878.