

## TREATMENT OF DISPLACED MID SHAFT CLAVICULAR FRACTURES WITH OPEN REDUCTION AND INTERNAL FIXATION WITH PLATE AND SCREWS

Prakash Channabasappa Wali<sup>1</sup>, Satish Shankar Nesar<sup>2</sup>

<sup>1</sup>Associate Professor, Department of Orthopaedics, Belagavi Institute of Medical Sciences, Belagavi.

<sup>2</sup>Assistant Professor, Department of Orthopaedics, Belagavi Institute of Medical Sciences, Belagavi.

### ABSTRACT

#### BACKGROUND

Midshaft clavicular fractures are most common fractures encountered. Treatment of choice was conservative whether comminuted or displaced. Figure-of-eight bandage was used in treating all these fractures. Many of fractures went in for nonunion and some gross malunion. In course of time, internal fixation either percutaneously using Steinman pin, K wire or TENS nail/ORIF with plate and screws for displaced fractures were used. This prospective study was conducted to evaluate the results of plating using a 3.5-mm reconstruction plate for the treatment of middle third displaced clavicle fractures.

#### MATERIALS AND METHODS

From 2013-2015, twenty five patients with middle third displaced clavicle fractures were treated with plating using 3.5 reconstruction plate. The indications for surgery included complete displacement and comminution as accordingly classified following Allman's classification.

#### RESULTS

The mean time to union was 11 weeks (range 8-14 weeks). At the time of last followup, i.e. 24 weeks, all the fractures were healed and were advised to get back to their pre-injury activity.

#### CONCLUSION

Plating is an effective and definitive treatment modality for middle third displaced clavicle fractures with few complications and early return of shoulder function. The procedure provides stable fixation, avoids risk to vital structures below the clavicle and is associated with a low rate of implant-prominence problems.

#### KEYWORDS

Clavicle, Clavicle Fractures, Open Reduction and Plating.

**HOW TO CITE THIS ARTICLE:** Wali PC, Nesar SS. Treatment of displaced mid shaft clavicular fractures with open reduction and internal fixation with plate and screws. J. Evid. Based Med. Healthc. 2017; 4(4), 201-204. DOI: 10.18410/jebmh/2017/38

#### BACKGROUND

Clavicular fractures represent 2.6% to 5% of all fractures and middle third fractures account for 69% to 82% of fractures of the clavicle. The junction of the outer and middle third is the thinnest part of the bone and is the only area not protected by or reinforced with muscle and ligamentous attachments. These anatomic features make it prone to fracture particularly with a fall on the point of the shoulder, which results in an axial load to the clavicle. Optimal treatment of nondisplaced or minimally displaced midshaft fracture is with a sling or figure-of-eight dressing; the nonunion rate is very low. However, when midshaft clavicular fractures are completely displaced or comminuted, and when they occur in elderly patients or females, the risk

of nonunion, cosmetic deformity and poor outcome maybe markedly higher. Thus, some surgeons propose surgical stabilisation of a complex midshaft clavicular fracture with either plate-and-screw fixation or intramedullary devices.<sup>1</sup>

More recent data, based on detailed classification of fractures, suggest that the incidence of nonunion in displaced comminuted midshaft clavicular fractures in adults is between 10 and 15%.

The literature favours rigid internal fixation with plates for symptomatic midclavicular nonunion. However, the use of open reduction in the treatment of fresh fractures is controversial with wide geographic and institutional variations in the choice of treatment. More papers have been published on the complications of clavicle fractures and the treatment of nonunion than on the primary operative treatment.

Moderately displaced fractures of the mid third of the clavicle can be treated nonoperatively with satisfactory results. However, the results of nonoperative treatment for severely displaced fractures (Allman type 1b and 1c) in adults are poor.

*Financial or Other, Competing Interest: None.*

*Submission 15-12-2016, Peer Review 23-12-2016,*

*Acceptance 03-01-2017, Published 12-01-2017.*

*Corresponding Author:*

*Dr. Prakash Channabasappa Wali,*

*Plot No. 326, CTS NO. 5090/12,*

*2nd Stage, Hanuman Nagar,*

*Belgavi-590019.*

*E-mail: pakwali@yahoo.com*

*DOI: 10.18410/jebmh/2017/38*

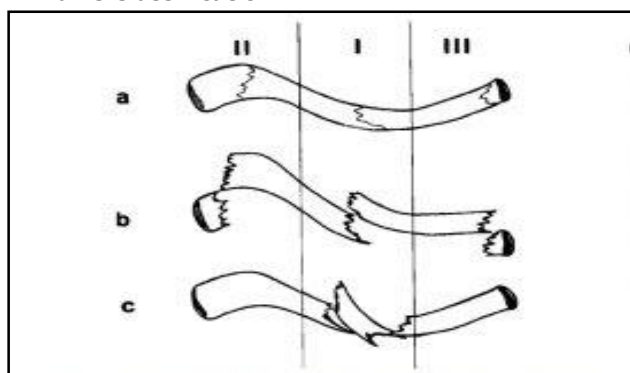


## MATERIALS AND METHODS

For the past few years, the standard treatment for displaced midclavicular fractures at our hospital has been operative. We found the Allman classification<sup>2</sup> for midshaft fractures to be simple and gives into account of displacement and comminution.

From 2010-2015, a total of 25 patients were seen with acute nonpathologic mid shaft fractures clavicle; 22 patients were Allman type 1b whereas 3 pts. were Allman type 1c were operated. Patients with multiple shoulder girdle injuries were not included. The fracture was caused by fall in 23 patients and by motorcycle accidents in 2 cases. All cases were operated upon within 3 days of injury. The indications for operation included displacement of the bone ends by more than 100% of the diameter of the clavicle or the presence of fracture comminution.

### Allman's Classification



### Operative Procedure

The operation was performed under general anaesthesia or interscalene block with the patient in a supine position. A longitudinal incision parallel to the long axis of the clavicle and centred above the fracture was made along the superior border of the bone. The fracture was plated with a 3.5 mm reconstruction plate. Comminuted fragments were reduced and held with cerclage wire. Interfragmentary screws were used as needed. The length of the plate was determined by the degree of comminution and the aim was to restore clavicular length and to obtain purchase of at least four to six cortices on each side of the fracture. Bone grafting was not done primarily. Postoperatively, the limb was maintained in a sling for 4 weeks for patient comfort. No other support was used. The patients were seen at regular intervals until the final result of treatment was clear. Patients were questioned about pain, difficulty in lifting, pain with shoulder straps, pain on sleeping on affected side, local tenderness/numbness on palpation, impaired range of movement, impaired strength, signs of nerve compression, cosmetic abnormality, return to work and overall patient satisfaction.

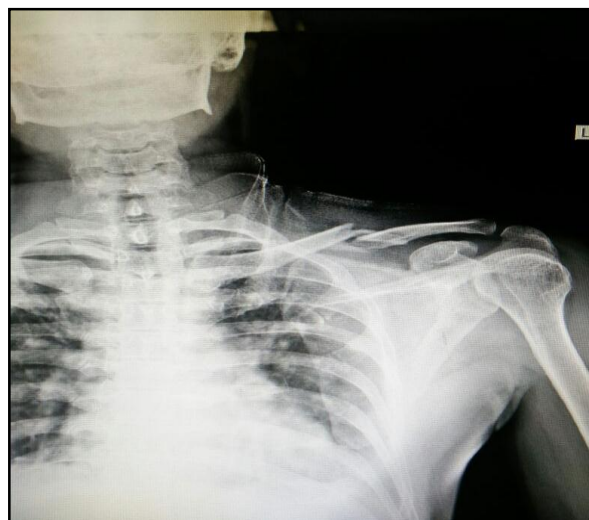### RESULTS

Sufficient data were collected for followup in 25 patients. There were 22 men and 3 women, the average age being 37.3 years (range 22-65). The mean follow-up was 6 months. The right clavicle was fractured in 14 cases and the

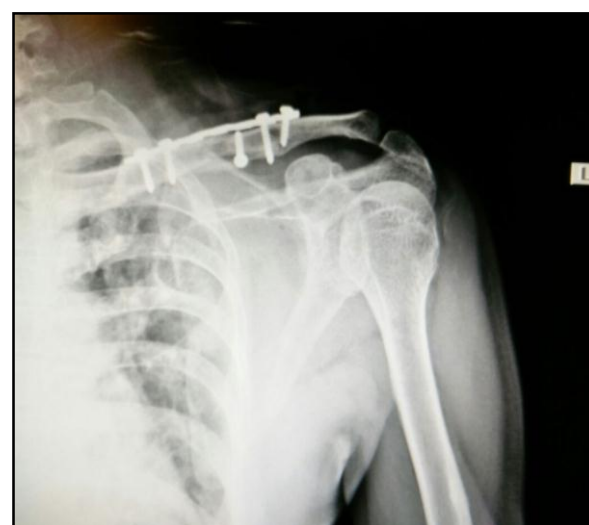left in 11 cases. Cerclage wires were used in 2 cases and interfragmentary in 2 cases.

No patient had neurovascular impairment or pulmonary injury attributable to the procedure. Pain subsided after 3 days postoperatively. The time to radiographic union was 8 weeks in 18 patients and 14 weeks in 7 patients.

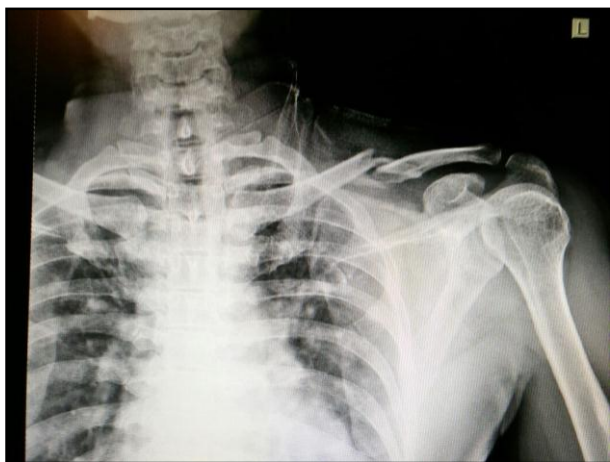
Clinically, 8 patients complained of mild soreness with weather and activity and 2 patients had impairment in terminal 20 degrees of shoulder movement. These patients were elderly and diabetic; this did not handicap them from their daily activities. Eighteen patients after eight weeks and seven patients after fourteen weeks with radiological union were advised to return to their routine regular activities and were abstained from heavy work. At 24 weeks, they were advised to go back to the preinjury activities.



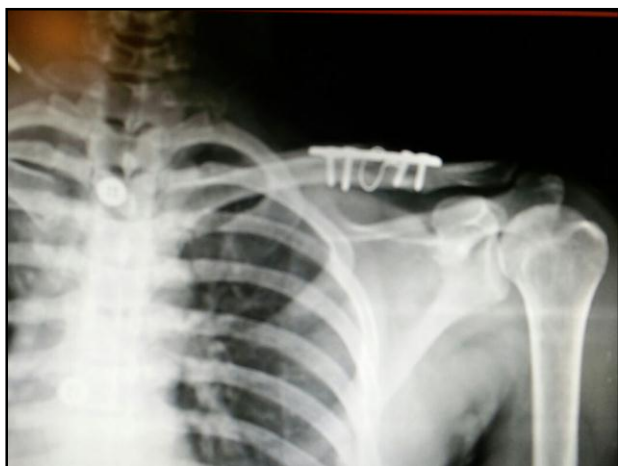**Figure 1. Preoperative X-Ray with Displaced Butterfly Fragment**



**Figure 2. Postoperative X-Ray Treated with Plate and Screw with Interfragmentary Fixation of the Butterfly Fragment**



**Figure 3. Preoperative X-Ray with Displaced Butterfly Fragment**



**Figure 4. Postoperative X-Ray - Treated with Plate and Screw with Encirclage Wire of the Butterfly Fragment**

## DISCUSSION

In this retrospective assessment, we present the outcome of plating of fresh displaced mid third clavicle fractures. Most orthopaedic surgeons prefer nonoperative treatment for nondisplaced middle third fractures of the clavicle using a sling or a figure 8 support. The optimal treatment modality for acute displaced middle third fractures of the clavicle remains controversial, however.<sup>3</sup> Although, most middle third clavicle fractures unite uneventfully, conservative treatment has been found to be associated with higher rates of nonunion and patient dissatisfaction with the final result.<sup>4</sup> A prospective randomised-controlled trial by the Canadian Orthopaedic Trauma Society compared plate and screw fixation with nonoperative treatment for displaced middle third clavicle fractures.<sup>5</sup> The results showed that time to union was shorter in the operative group than in the nonoperative group; moreover, surgical fixation of a displaced clavicle fracture resulted in improved functional outcome and lower rates of malunion and nonunion compared with nonsurgical treatment after a year of follow-up.

Midshaft clavicle fractures get short shrift in medical texts. Craig, in classifying clavicle fractures, subdivided both medial and distal third clavicle fractures into five subtypes,

but did not find it necessary to subclassify mid third clavicle fractures.<sup>6</sup> This despite the fact that midshaft fractures occur much more often than medial and distal fractures combined. We have found it useful to separate out the displaced and comminuted fractures when deciding management and for years have been using a classification system of Allman. In this system, type 1b indicates a displaced midclavicular fracture, type 1c indicates comminuted or large butterfly fragment.

The mechanism of injury was fall in 23 patients and road traffic accidents in 2 patients. Robinson, studying 1000 adults found 27% due to road traffic accidents.<sup>7</sup> The relatively high energy impact of motorcycle accidents probably accounts for the high percentage of open and comminuted fractures in this series.

The many articles on the treatment of clavicular nonunion and malunion found on computerised literature searches and referenced by Simpson and Jupiter<sup>8</sup> suggest that the true incidence of nonunion is much higher.

In Robinson's series, the delayed union rate was 2.1% and the nonunion rate was 4.6% for type 2B1 fractures. For type 2B2, the delayed union rate was 6.3% and the nonunion rate was 9.4%. In Hill's series of displaced mid third clavicle fractures, 8/52 (15%) developed nonunion. White and Anson analysed 112 adult clavicle shaft fractures retrospectively and found 18 delayed unions and 9 nonunions.<sup>9</sup> When further subclassified, the nonunion rate was 13% in the high energy group. We agree with Robinson that the initial morphology of the fracture provides the best indication of the risk of delayed or nonunion irrespective of the mechanism of injury.

Plate fixation of fresh midclavicular fractures has been practiced for decades, yet very few clinical series have been published on the subject in the English literature.<sup>10</sup> To our knowledge, the largest is the series of 122 patients by Poigenfuerst et al<sup>11</sup> 102 of which were midclavicular fractures. They found nine cases (7.3%) of superficial disturbances of wound healing, but no case of osteomyelitis or infected pseudarthrosis.

In a study looking at closed treatment of displaced mid third fractures of the clavicle, Hill et al reviewed 52 out of 66 patients 38 months after injury and found that 13 patients had pain requiring the use of medication, 20 patients had pain with shoulder straps, 23 patients had pain sleeping on the affected side, 20 patients had local tenderness on palpation and 13 had notable cosmetic abnormality. Only 36 patients (69%) were satisfied with the result.

Nonunion developed in eight fractures (15%). They recommended open reduction and internal fixation of severely displaced fractures of the middle third of the clavicle in adult patients. Stanley and Norris, while comparing the efficacy of figure-of-eight bandages versus a broad arm sling stated that 33% of those over the age of 20 still had symptoms 3 months after fracture.<sup>12</sup>

W. J. Shen et al<sup>13</sup> in study of 251 patients stated early plate fixation may never become the treatment of choice for clavicular fractures, a knowledge of its outcome and complications is necessary to determine its relative merits.

The authors agree that clavicular fractures, which are not severely displaced can be managed nonoperatively. However, severely displaced and comminuted fractures behave differently from and should not be treated the same way as undisplaced or minimally displaced fractures.

Closed reduction is rarely successful for displaced or comminuted clavicle fractures. The deforming pull of the sternocleidomastoid muscle is too great and the deformity recurs very shortly despite the use of supports such as the figure-of-eight bandage. At our hospital, acute plating of displaced clavicle fractures has been standard procedure for the past few years. Union rate has been 100% compared with non-operated patient's pain relief is quicker and even when malunion occurs, it is much less severe. Clinically, there is less problem with shoulder straps.

Reconstruction plates can be contoured best to the complex three-dimensional anatomy of the clavicle. As with any tubular bone fracture, fixation of four or more cortices on each side is desirable. The plate should not be removed for at least one year to avoid refracture.

### CONCLUSION

Plating is an effective and definitive treatment modality for middle third displaced clavicle fractures with few complications and early return of shoulder function. The procedure provides stable fixation, avoids risk to vital structures below the clavicle and is associated with a low rate of implant-prominence problems.

### REFERENCES

- [1] Kyle JJ. Acute midshaft clavicular fracture. *Journal of American Academy of Orthopaedic Surgeons* 2007;15(4):239-248.
- [2] Allman FL, Georgia A. Fractures & ligamentous injuries of the clavicle & its articulation. *J BJS Am* 1967;49-A:774-784.
- [3] Zlowodzki M, Zella BA, Cole PA, et al. Treatment of acute midshaft clavicle fractures: systematic review of 2144 fractures: on behalf of the evidence-based orthopaedic trauma working group. *J Orthop Trauma* 2005;19(7):504-507.
- [4] Hill JM, McGuire MH, Crosby LA. Closed treatment of displaced middle-third fractures of the clavicle gives poor results. *J BJS Br* 1997;79(4):537-539.
- [5] Canadian Orthopaedic Trauma Society. Nonoperative treatment compared with plate fixation of displaced midshaft clavicular fractures. A multicenter, randomized clinical trial *J BJS Am* 2007;89(1):1-10.
- [6] Craig EV. Fractures of clavicle. In: Bucholz RW, Heckman JD, eds. *Rockwood and Green's fracture in adults*. 5<sup>th</sup> edn. Philadelphia: Lippincott-Raven publishers 1996:1109-1161.
- [7] Robinson CM. Fractures of the clavicle in the adult. Epidemiology and classification. *J BJS [Br]* 1998;80(3):476-484.
- [8] Simpson NS, Jupiter JB. Clavicular nonunion and malunion: evolution and surgical treatment. *J Am Acad Orthop Surg* 1996;4:1-8.
- [9] White RR, Anson PS, Kristiansen. Adult clavicle fractures: relationship between mechanism of injury and healing. *Orthop Trans* 1989;13:514-515.
- [10] Bostman O, Manninen M, Philajamaki M. Complications of plate fixation in freshly displaced midclavicular fractures. *J Trauma* 1997;43(5):778-783.
- [11] Poigenfurst J, Rappold G, Fischer W. Plating of fresh clavicular fractures: results of 122 operations. *Injury* 1992;23(4):237-241.
- [12] Stanley D, Norris SH. Recovery following treatment of clavicle fractures treated conservatively. *Injury* 1998;19(3):162-164.
- [13] Shan WJ, Liu TJ, Shen YS. Plate fixation of fresh displaced midshaft fractures clavicle fractures. *Injury, Int J Care Injured* 1999;30:497-500.