

TO COMPARE MANUKA HONEY DRESSING WITH CONVENTIONAL DRESSING IN SURGICAL WOUND

Ashok Kshirsagar¹, Abhishek Mahna², Akshay Pednekar³, Mayank Vekariya⁴, Ronak Chaudhari⁵, Vaibhav Gupta⁶, Ashar Shaikh⁷, Ritvij Patankar⁸

HOW TO CITE THIS ARTICLE:

Ashok Kshirsagar, Abhishek Mahna, Akshay Pednekar, Mayank Vekariya, Ronak Chaudhari, Vaibhav Gupta, Ashar Shaikh, Ritvij Patankar. "To Compare Manuka Honey Dressing with Conventional Dressing in Surgical Wound". Journal of Evidence based Medicine and Healthcare; Volume 1, Issue 11, November 17, 2014; Page: 1418-1424.

ABSTRACT: Surgical wounds can cause painful lengthy hospital stay, multiple stages of surgeries, prolonged disability, prolonged rehabilitation, loss of income and enormous financial burden. Manuka honey has high level of non-peroxide anti-bacterial and anti-inflammatory activity which makes it highly suitable for topical use in the treatment of wounds. Manuka honey is gathered in New Zealand from the manuka bush, *Leptospermum scoparium*, which grows uncultivated throughout the country. Aim of the study is to compare the efficacy of manuka honey dressing and conventional dressing on surgical wounds. This study was carried out in the Department of Surgery, Krishna Institute of Medical Sciences, Karad. Data was collected from 100 patients with surgical wounds admitted in the hospital during the period from May 2013 to April 2014 for this study considering the inclusion and exclusion criteria. In our study we found that manuka honey dressing lead to faster healing of wounds as compared to that of conventional dressing. In case of superficial burn wound, disrupted abdominal wound following caesarean section, chronic leg ulcer, diabetic foot healing was faster as compared to conventional method but in Fournier gangrene healing was delayed with manuka honey. Results are formulated and conclusion of my study is that there was large body of evidence to support the use of honey as a wound dressing for a wide range of types of wound. Its antibacterial activity rapidly clears infection and protects wounds from becoming infected, thus it provides a moist healing environment.

KEYWORDS: Conventional dressing; Manuka honey; surgical wounds.

INTRODUCTION: Surgical wounds can cause painful lengthy hospital stay, multiple stages of surgeries, prolonged disability, prolonged rehabilitation, loss of income and enormous financial burden. Wound dressing plays an important role in tackling these issues. It is therefore appropriate that the process and problems of wound healing should be vigorously addressed by all practitioners and investigators involved in the treatment of surgical wounds and in the development and use of new wound repair material.^[1]

An ideal dressing used in the wound management should be economical, easy to apply and readily available that will provide good pain relief, protect the wound from infection, promote healing, keep moisture, be non - antigenic and adhere well to the wound promoting spontaneous epithelization and formation of healthy granulation tissue.^[2]

Honey has antibacterial activity but manuka honey has high level of non-peroxide anti-bacterial and anti-inflammatory activity which makes it highly suitable for topical use in the

ORIGINAL ARTICLE

treatment of wounds. Manuka honey is gathered in New Zealand from the manuka bush, *Leptospermum scoparium*, which grows uncultivated throughout the country.

Manuka honey dressing has better advantage over conventional dressing in terms of healthy granulation tissue formation with greater reduction in inflammatory cells during healing period resulting in reduced time of healing, where as conventional dressing has minimal granulation tissue formation, high grade of inflammation during the healing period with maximum exudates formation resulting in increased healing time.

This study compares the efficacy of manuka honey dressing with that of conventional dressing in the management of surgical wounds.

AIMS AND OBJECTIVES: To compare the efficacy of manuka honey dressing and conventional dressing on surgical wounds.

MATERIALS AND METHODS: This study was carried out in the Department of Surgery, Krishna Institute of Medical Sciences, Karad. Data was collected from 100 patients with surgical wounds admitted in the hospital during the period from May 2013 to April 2014 for this study considering the inclusion and exclusion criteria. All patients were interviewed as per a predesigned pretested proforma and a complete clinical examination was done. Cases were allocated randomly into test group and control group, each group consisting of 50 patients. The test group was treated with manuka honey dressing and control group was treated with conventional betadine and silver sulfadiazine dressings. In this study effect of manuka honey dressing was studied and compared with conventional betadine and silver sulfadiazine dressings with respect to time required for wound healing.

INCLUSION CRITERIA: Age group 20-60 years of age irrespective of sex.

SURGICAL WOUNDS: Who are willing to participate in the study.

EXCLUSION CRITERIA:

- Patients below 20 years of age
- Patients not willing to participate in this study.
- Patients who are allergic to manuka honey.
- The mean time for healing for five different categories of surgical wounds was calculated for both the control and study groups. Statistical analysis of the data as done using the level of significance at p value of <0.05 was considered significant.

ORIGINAL ARTICLE

OBSERVATION AND RESULT:

Type of wound	Mean time for healing with conventional dressing	Mean time for healing with manuka honey dressing	Standard error	P value
Superficial burn wound	9.5	16	0.359	0.05
Disrupted abdominal wound following caesarian section	4.7	15	0.261	0.01
Chronic leg ulcer	15	18	0.348	0.04
Diabetic foot	28.5	45	1.668	0.05
Fournier gangrene	24	18	0.745	>0.1

TABLE 1: SHOWING MEAN TIME OF WOUND HEALING FOR 5 DIFFERENT CATEGORIES OF SURGICAL WOUNDS WITH THE P VALUE

FIGURE 1: GRAPH SHOWING MEAN TIME OF WOUND HEALING FOR 5 DIFFERENT CATEGORIES OF SURGICAL WOUNDS AND COMPARISON BETWEEN MANUKA HONEY AND CONVENTIONAL DRESSINGS

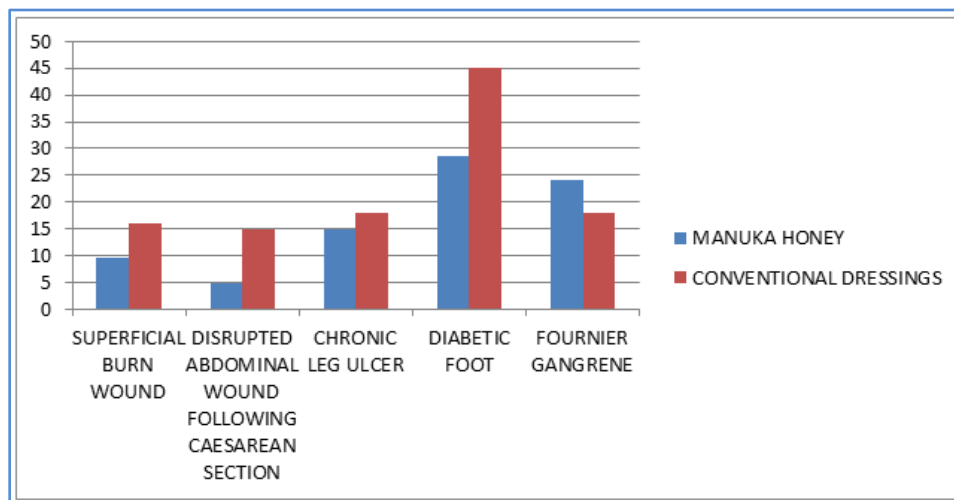


Fig. 1

DISCUSSION: The evidence presented in this article amply demonstrates that honey, the oldest wound dressing material known to medicine, can give positive results where the most modern products are failing. Because people generally are unaware of the historical usage of honey as a wound dressing, or know only of its ancient usage, its clinical usage is presumed to be a new development or something that has been "rediscovered."³

Further evidence to support the use of honey as a wound dressing comes from laboratory studies that have clearly demonstrated that honey has bioactivities that would be beneficial in

ORIGINAL ARTICLE

wound care. In work with cultures of leukocytes, honey has been shown to stimulate cytokine production by monocytes.^{4,5} The release of cytokines is what initiates the tissue repair process as well as the immune response to infection. Also, stimulation by honey of other aspects of the immune response, the proliferation of B- and T-lymphocytes and the activity of phagocytes, has been shown.⁶

The number of publications on laboratory studies showing that honey has antibacterial activity with a very broad spectrum is very large.⁷

A number of studies have shown that manuka honey has a broad spectrum antibacterial activity and anti-inflammatory action. Manuka honey contains a high level of additional non-peroxide anti-bacterial component. The non-peroxide anti-bacterial action of manuka honey is unique as compared to other honeys. Laboratory studies with Leptospermum honey with antibacterial potency near the median level have shown the MIC (minimum inhibitory concentration) to be 2-3% for *Staphylococcus aureus*, 3.3-4% for coagulase-negative staphylococci, 5.5-9% for pseudomonads, 2.7-3% for MRSA, and 3.8-5% for VRSA.

UMF indicates the honey has high antibacterial activity. UMF is a guarantee and measure of the anti-bacterial potency of honey. UMF 10 is minimum level. UMF was first discovered by DR Peter Molan of Waikato University. UMF is only found in manuka honey.

Manuka honey has an anti-microbial property not shared by other honey. This property is called the unique manuka factor (Fig. 2). Unique manuka factor is not affected by the catalase enzyme present in body tissue and serum. This enzyme will break down, to some degree, the hydrogen peroxide which is the major antibacterial factor found in other types of honey. If a honey without UMF were used to treat an infection, the potency of the honey antibacterial activity most likely is reduced because of the action of catalase.

The enzyme that produces hydrogen peroxide in honey is destroyed when honey is exposed to heat and light. However, UMF is stable, so there is no concern about manuka honey losing its activity in storage.

Honey with UMF is more effective than that with hydrogen peroxide against some type of bacteria. For example active manuka honey with UMF is about twice effective as other honey against *Escherichia coli* and *staphylococcus aureus*^{8,9}, the most common cause of the infected wound.

Honey can be sterilised by gamma irradiation without loss of any of its antibacterial activity.¹⁰

In our study we found that patient who underwent dressing with Manuka honey for superficial burns the mean healing time for granulation tissue formation was 9.5 days as compared to control group which was 16 days. Patient showed better compliance in terms of alleviation of pain, reduced hospital stay and expenses. Our study results are similar to the study done by Subrahmanyam M.¹¹

The second group comprised of patients having disrupted abdominal wounds from caesarean section. With use of manuka honey the mean healing time was 4.7 days as compared to control group which was 15 days. With honey, slough and necrotic tissue were replaced by granulation and advancing epithelialization within 4 days, wounds became odour less and sterile within 8 days. Study results are similar to study done by Phuapradit W, Saropala N.¹²

ORIGINAL ARTICLE

The third group comprised of patients with chronic leg ulcer in which mean healing time was 15 days with manuka honey dressing as compared to the control group which was 18 days (Fig 3, 4). Patients showed early healing of wounds with use of manuka honey and that too with less antibiotic usage as compared to the control group. Results are similar to the study done by Oluwatosin OM, Olabanji JK, Oluwatosin OA, et al.¹³

In case of patients with diabetic foot complete healing with manuka honey dressing was seen in approximately a mean of 28.5 days as compared to control group which took approximately 45 days for healing (Fig. 4, 5). With use of manuka honey no effect was found in the blood sugar levels of patients.

However in patients with Fournier's gangrene, dressing with conventional method was better as compared to manuka honey as wound healing time was less with conventional method which required approximately a mean of 18 days as compared to trial group which required approximately 24 days. Study was compared with study done by Efem SEE.¹⁴

A 2002 review found that although the anti-bacterial activity had been demonstrated in vitro, the number of clinical case studies was small. The review concluded that there was a potential for its use in the management of large number of wounds types.

CONCLUSION: There is a large body of evidence to support the use of Manuka honey as a wound dressing for a wide range of types of wound. Its antibacterial activity rapidly clears infection and protects wounds from becoming infected, thus it provides a moist healing environment. It also rapidly debrides wound and its anti-inflammatory activity reduces oedema and exudate, and prevents or minimize hypertonic scarring. It also stimulates the growth of granulation tissue and epithelial tissue so that healing is hastened.

REFERENCES:

1. Office of Complementary Medicines. Honey scientific report [Online]; 1998. Available from URL: ijl.sagepub.com/content/5/1/40.refs.
2. Fox C. Honey as a dressing for chronic wounds in adults. *Br J Community Nurs* 2002; 7 (10): 530-4.
3. Zumla A, Lulat A. Honey—a remedy rediscovered. *J R Soc Med* 1989; 82 (7): 384-5.
4. Tonks A, Cooper RA, Price AJ, et al. Stimulation of TNF- α release in monocytes by honey. *Cytokine* 2001; 14 (4): 240-2.
5. Tonks AJ, Cooper RA, Jones KP, et al. Honey stimulates inflammatory cytokine production from monocytes. *Cytokine* 2003; 21 (5): 242-7.
6. Abuharfeil N, Al-Oran R, Abo- Shehada M. The effect of bee honey on proliferative activity of human B- and T-lymphocytes and the activity of phagocytes. *Food Agric Immunol* 1999; 11: 169-77.
7. Molan PC. The antibacterial activity of honey: 1. The nature of the antibacterial activity. *Bee World* 1992; 73 (1): 5-28.
8. Willixdj, Molanpc. A comparison of the sensitivity of wound infecting species of bacteria to the antibacterial activity of manuka honey. *J Appl Bacteriol* 1992; 73: 388-94.

ORIGINAL ARTICLE

9. Cooper RA, Molan pc, Harding KG. Antibacterial activity of manuka honey against strains of staphylococcus aureus from infected wound. JR Soc Med 1999; 92; 283-5.
10. Molan pc, Allen KL. The effect of gamma-irradiation on the antibacterial activity of honey. J Pharmacol 1996; 48 1206-9.
11. Subrahmanyam M. Topical application of honey in treatment of burns. Br J Surg 1991; 78 (4): 497-8.
12. Phuapradit W, Saropala N. Topical application of honey in treatment of abdominal wound disruption. Aust N Z J Obstet Gynaecol 1992; 32 (4): 381-4.
13. Oluwatosin OM, Olabanji JK, Oluwatosin OA, et al. A comparison of topical honey and phenytoin in the treatment of chronic leg ulcers. Afr J Med Sci 2000; 29 (1): 31-4.
14. Efem SEE. Recent advances in the management of Fournier's gangrene preliminary observations. Surgery 1993; 113 (2): 200-4.



Fig. 1: Manuka honey

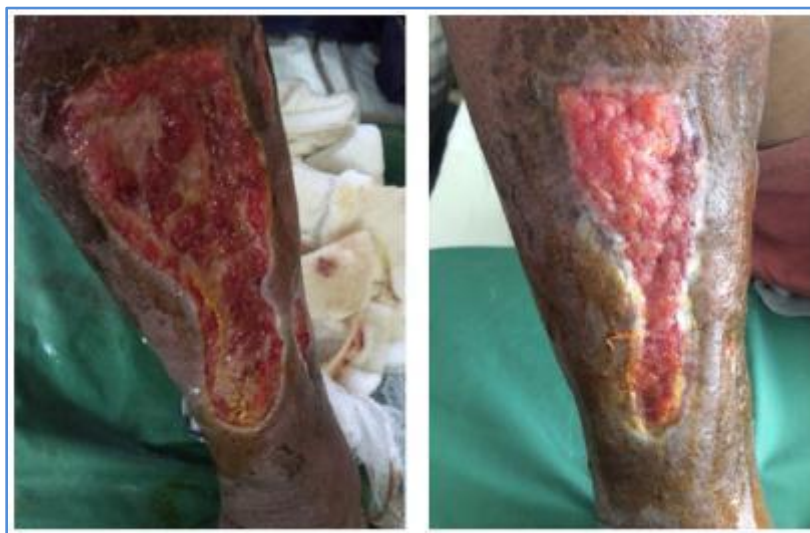

Fig. 2 & 3: Chronic leg ulcer Healing after Manuka honey dressing

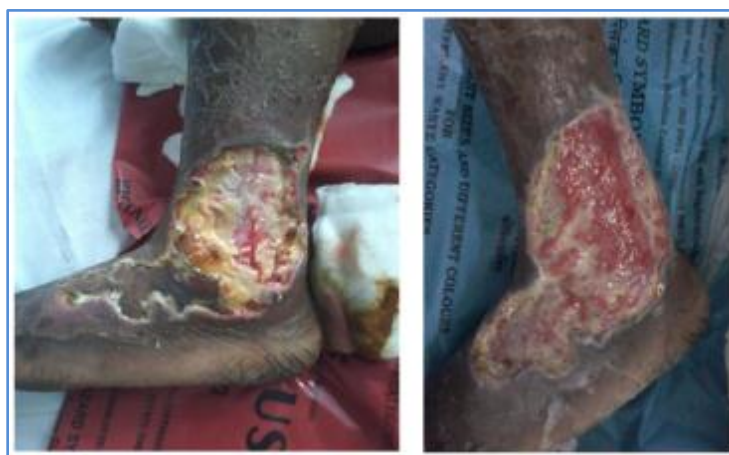

Fig. 4 & 5: Diabetic foot After Conventional dressing

AUTHORS:

1. Ashok Kshirsagar
2. Abhishek Mahna
3. Akshay Pednekar
4. Mayank Vekariya
5. Ronak Chaudhari
6. Vaibhav Gupta
7. Ashar Shaikh
8. Ritvij Patankar

PARTICULARS OF CONTRIBUTORS:

1. Professor, Department of General Surgery, Krishna Institute of Medical Sciences University, Karad, Maharashtra, India.
2. Resident, Department of General Surgery, Krishna Institute of Medical Sciences University, Karad, Maharashtra, India.
3. Resident, Department of General Surgery, Krishna Institute of Medical Sciences University, Karad, Maharashtra, India.
4. Resident, Department of General Surgery, Krishna Institute of Medical Sciences University, Karad, Maharashtra, India.
5. Resident, Department of General Surgery, Krishna Institute of Medical Sciences University, Karad, Maharashtra, India.

6. Resident, Department of General Surgery, Krishna Institute of Medical Sciences University, Karad, Maharashtra, India.
7. Resident, Department of General Surgery, Krishna Institute of Medical Sciences University, Karad, Maharashtra, India.
8. Resident, Department of General Surgery, Krishna Institute of Medical Sciences University, Karad, Maharashtra, India.

NAME ADDRESS EMAIL ID OF THE CORRESPONDING AUTHOR:

Dr. Ashok Kshirsagar,
Department of General Surgery,
Krishna Institute of Medical Sciences
University Campus, Karad,
Maharashtra, India.
E-mail: kshirsagarashok007@gmail.com

Date of Submission: 13/10/2014.
Date of Peer Review: 14/10/2014.
Date of Acceptance: 11/11/2014.
Date of Publishing: 13/11/2014.