

## THYROGLOSSAL CYST- VARIABLE PRESENTATIONS

Visweswara Rao Suraneni<sup>1</sup>, Ayyappa Amara<sup>2</sup>

<sup>1</sup>Associate Professor, Department of ENT, Maharaja Institute of Medical Sciences, Nellimarla, Vizianagaram, Andhra Pradesh.

<sup>2</sup>Junior Resident, Department of ENT, Maharaja Institute of Medical Sciences, Nellimarla, Vizianagaram, Andhra Pradesh.

### ABSTRACT

#### BACKGROUND

Thyroglossal cysts are the most common cause of congenital cyst formation in the neck that may present at any age. Classically, it presents as an anterior midline neck swelling that moves with deglutition and protrusion of the tongue. Occasionally, thyroglossal cyst present clinically in atypical manner, which may pose a diagnostic challenge.

#### MATERIALS AND METHODS

Patients came to outpatient department with anterior neck swellings of the neck during the period from June 2014 till May 2015 were included in this study. Swellings of the thyroid gland are excluded.

#### RESULTS

A total of 10 patients were included in the study. All patients were found to be adults in our study out of them 8 were males (80%) and 2 were females (20%). The site of the cyst was infrahyoid in 9 cases and 1 case showed suprahyoid (Figure 6). Clinically, 8 cases (80%) showed classical midline cystic presentation and in two cases (20%) the cysts were presented in lateral neck up to the level of sternocleidomastoid muscle and movement with deglutition and protrusion of tongue was not appreciated. In these two cases, fine needle aspiration and ultrasound were inconclusive. In all patients, Sistrunk's operation was performed. Histopathological report in these two cases reported as thyroglossal cyst.

#### CONCLUSION

In all lateral presentations of cystic swellings of the neck and absence of mobility during deglutition and tongue protrusion - cannot exclude a diagnosis of thyroglossal cyst. In all the cases, Sistrunk's operation was performed and no recurrence was observed.

#### KEYWORDS

Thyroglossal Cyst, Sistrunk's Operation.

**HOW TO CITE THIS ARTICLE:** Suraneni VR, Amara A. Thyroglossal cyst- variable presentations. J. Evid. Based Med. Healthc. 2016; 3(93), 5107-5110. DOI: 10.18410/jebmh/2016/1068

#### BACKGROUND

Thyroglossal cyst is the most common anomaly of the neck representing more than 75% of congenital midline neck masses.<sup>1</sup> There is no gender predilection. Age of affected patients range from birth to 70 years approximately. 50% of patients present before 20 years of age.

Thyroglossal cysts originate from persistent epithelial remnants of the thyroglossal duct that are present during the descent of the thyroid gland from the foramen cecum to its final position in the anterior neck.<sup>2</sup> Thyroglossal cyst usually presents as a painless midline simple cystic neck swelling that moves with deglutition and protrusion of the tongue. Occasionally, thyroglossal cyst can present laterally up to sternocleidomastoid muscle, which may pose a

diagnostic challenge. Failure to anticipate the possibility of a thyroglossal cyst maybe associated with the performance of an inadequate surgical procedure such as simple excision or incision and drainage, both of which are associated with significant recurrence rates.<sup>3</sup> We described a case series of thyroglossal cyst presentations. Out of them, two were lateral neck presentations not showing movement with deglutition and tongue protrusion. In those two cases, fine needle aspiration and ultrasound were inconclusive.

#### AIM AND OBJECTIVES

The aim of this study is to review cases diagnosed with thyroglossal cysts as regards clinical presentation focusing on patients with lateral cystic neck mass.

#### MATERIALS AND METHODS

The present study was carried out in Otolaryngology Department in a tertiary care hospital from June 2014 to May 2015. All patients with neck swelling were clinically examined and investigated. Those who were clinically diagnosed as thyroglossal cyst were included in this study. Swellings of the thyroid glands are excluded.

Classically, the thyroglossal cyst is a painless midline neck swelling, which moves with deglutition and protrusion of the tongue with typical radiological appearance of a

*Financial or Other, Competing Interest: None.  
Submission 18-10-2016, Peer Review 28-10-2016,  
Acceptance 07-11-2016, Published 18-11-2016.*

*Corresponding Author:*

*Dr. Visweswara Rao Suraneni,  
Associate Professor, Department of ENT,  
Maharaja Institute of Medical Sciences,  
Nellimarla, Vizianagaram, Andhra Pradesh.  
E-mail: dr.s.visweswararao@gmail.com  
DOI: 10.18410/jebmh/2016/1068*



simple cystic swelling in the neck. Any deviation in the clinical presentation was considered as a variant of thyroglossal cyst.

## RESULTS

All patients were found to be adults between 20-45 yrs. in our study. Out of them, 8 were males (80%) and 2 were females (20%). The site of the cyst was infrahyoid in 9 cases and suprahyoid in 1 case. Clinically, 8 cases (80%) showed classical midline cystic presentation and in two cases (20%), the cysts were presented in lateral neck up to the level of sternocleidomastoid muscle and movement with deglutition and protrusion of tongue was not appreciated. In these two cases, fine needle aspiration and ultrasound were inconclusive. In all patients, Sistrunk's operation was performed. Histopathological report in these two cases was reported as thyroglossal cyst (Sistrunk's procedure- Excision of cyst along with body of the hyoid bone).

### Cases with Atypical Presentation

#### Case 1

A 35-year-old male presented with a 6-month history of swelling on the left side of his neck. A 3 x 4 cm cystic swelling was found extending superiorly up to the submandibular region inferiorly up to the lower border of the thyroid cartilage and laterally up to the anterior border of the sternocleidomastoid muscle. Movement with deglutition and protrusion of the tongue was not well appreciated.

The clinical photographs of the patient are shown in Figure 1.

The following differential diagnoses were considered-

- Solitary thyroid nodule.
- Branchial cyst.
- Thyroglossal duct cyst.

#### The Following Investigations were done

Thyroid function tests were normal. Ultrasonography showed unilocular cystic mass in a normal-appearing thyroid gland. Fine needle aspiration cytology was suggestive of inclusion cyst. A radionuclide thyroid scan obtained before surgery revealed that there was no ectopic thyroid tissue within the cyst or the cyst wall.

Elective surgery was planned for this patient for what was presumed to be a branchial cleft cyst.

Lateral neck incision was given over the cyst. Superior and inferior flaps were developed and whole cyst was exposed. Apart from the thyroid gland, a large cyst was identified and it was adherent surrounding tissues and entering between the thyroid and body of the hyoid bone. The incision was extended to the opposite side crossing the midline to expose body of the hyoid bone completely. The cyst was found to be going under the body of the hyoid bone. The cyst and along with the body of the hyoid bone was excised.

The operative picture is shown in Figure 2 and excised specimen in Figure 3.

## Case-2

### CLINICAL PRESENTATION

A 21-year-old male presented with a left lateral neck swelling that had been increasing in size over a 4-month period.

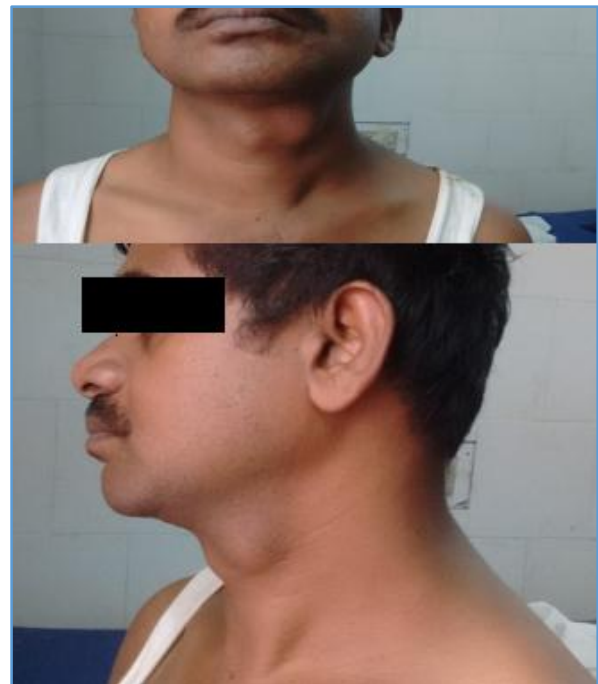On examination, 3 x 3 cm, soft and mobile swelling was seen, which was best palpated on the anterior border of the left Sternocleidomastoid Muscle (SCM) extending superiorly below the left submandibular region and inferiorly up to lower border of thyroid cartilage. Movement with deglutition and protrusion of tongue was not well appreciated.

The clinical photographs of the patient are show in Figure 4.

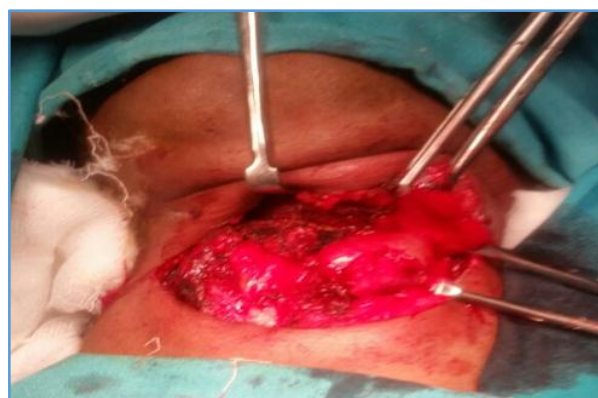
Through a horizontal skin crease incision, the mass was noted to be well contained by a cyst wall with a very thin stalk tracking under the body of the hyoid and a Sistrunk's procedure was performed.

The operative picture is show in Figure 5.

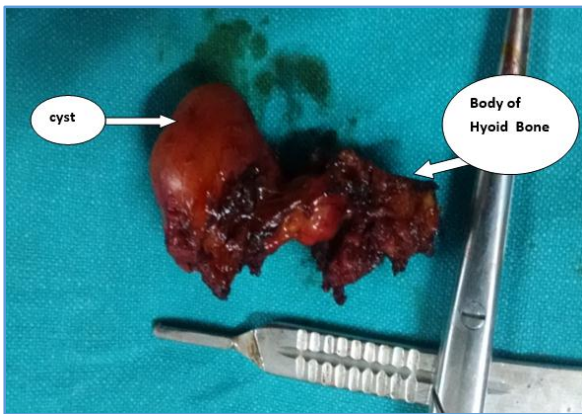
## CASE 1



**Figure 1. Clinical Photographs of the Patient**

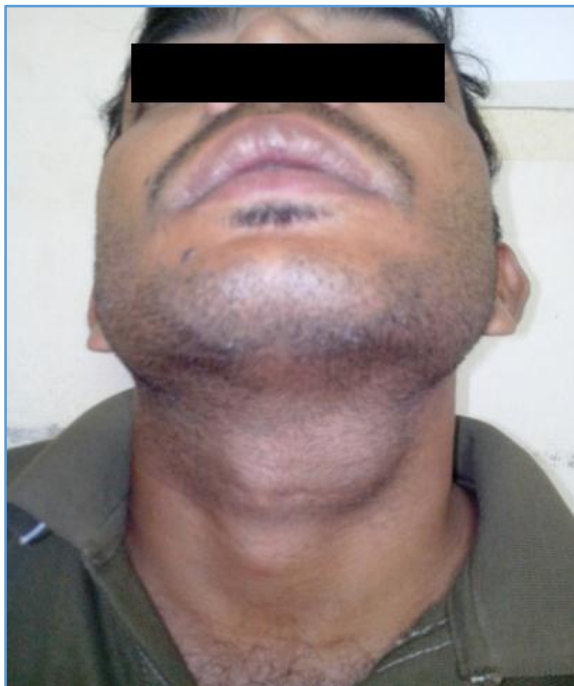

**Figure 2. Wide Surgical Field after Extending the Incision to the Opposite Side to Expose the Hyoid Bone**

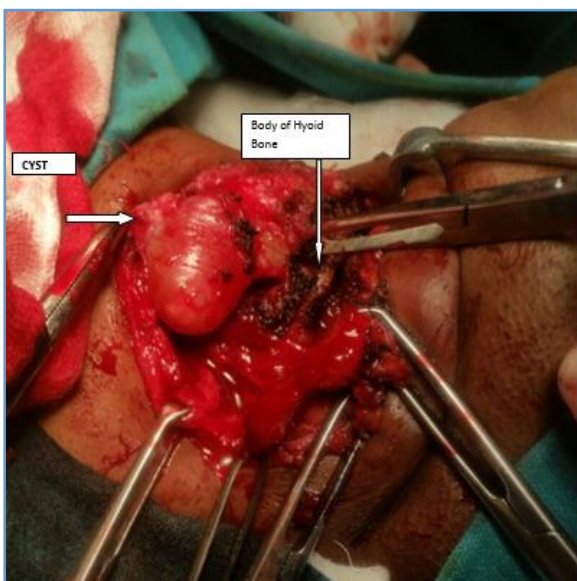


**Figure 3. Surgical Specimen**

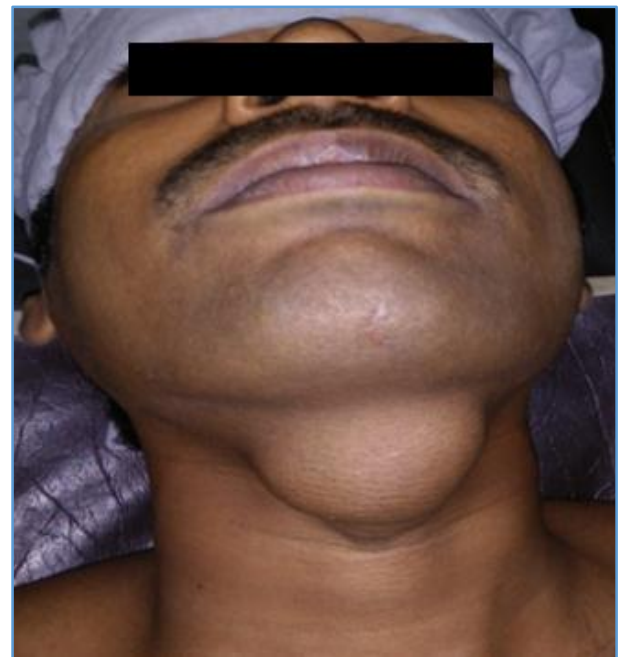**CASE 2**



**Figure 4. Clinical Photograph of the Patient**



**Figure 5. Surgical Field Showing Cyst Along with the Hyoid Bone**



**Figure 6. Suprahyoid Variety of Thyroglossal Cyst**

**DISCUSSION**

The thyroid gland begins to develop during the 3rd week of foetal life as a median outgrowth from the floor of the primitive pharynx. The normal migration of the primitive thyroid from the foramen cecum to its mature position in the anterior neck results in the creation of the thyroglossal duct. The lumen of the duct is usually obliterated by the 9th or 10th week of gestation.<sup>4</sup> However, endothelial elements of the ductal lining may produce mucus resulting in the development of a cyst. Theories attempting to explain this phenomenon speculate either- 1) a blockage in the tract that leads to the accumulation of secretions or 2) recurrent throat inflammation that leads to the cystic degeneration of the tract.<sup>5</sup>

Thyroglossal duct cysts are the most common cause of congenital neck mass.<sup>6</sup> Other conditions in the differential diagnosis of a painless neck mass would include ectopic thyroid tissue, a dermoid cyst, a branchial cleft cyst, a cystic hygroma, a lymph node, a lipoma and a sebaceous cyst.<sup>7</sup> Though, thyroglossal cysts may present at any age, the prevailing thought has been that the peak incidence is in the 1-10 year age group; however, recently, it has been shown that thyroglossal cysts are more common in the adult population than previously believed. It has been demonstrated that thyroglossal cysts may have a bimodal distribution with peaks at 6 and 45 years of age.<sup>8</sup> In our series, all patients were adults. Approximately, 7% of the population have thyroglossal duct remnants.<sup>9</sup>

Thyroglossal cysts are epithelium-lined that can arise at any point along the duct's course from the foramen cecum at the base of the tongue to the lower midline of the neck. There are four general types of thyroglossal cysts based on location- thyrohyoid (60.9% of cases), suprahyoid (24.1%), suprasternal (12.9%) and intralingual (2.1%). In all our cases, the cyst presented as thyrohyoid type.<sup>10</sup> Patients typically present with a painless midline swelling below the

hyoid bone. Small cyst usually present in the midline following any infection within the cyst, accumulation of secretion and insufficient space to accommodate it may cause the cyst to enlarge and present laterally up to sternocleidomastoid muscle. Most thyroglossal cysts move during swallowing. Small cyst usually present in the midline following any infection within the cyst, accumulation of secretion and insufficient space to accommodate it, may cause the cyst to enlarge and present laterally up to sternocleidomastoid muscle and during protrusion of the tongue. The degree of movement depends on the size of the cyst. The mobility of larger cysts is restricted in the two cases described above. The large size of the cysts probably explains why the swelling did not move during protrusion of the tongue. Moreover, it was found intraoperatively that the cysts were adherent to the surrounding structures to some extent, such adhesions can also contribute to the restricted mobility of the swelling.<sup>10</sup> Intraoperatively, projection of cyst going under the body of hyoid bone made us to realise that it is thyroglossal cyst.<sup>11-13</sup>

Shahin et al showed that FNAC has a sensitivity of 62% and a positive predictive value of 69%. So, it can be helpful in establishing the diagnosis of a thyroglossal cyst in the correct clinical scenario. The cytopathological findings noted on FNAC are not unique, though the clinical presentation and radiological findings must be considered in making a diagnosis.<sup>14</sup>

On all radiological images, a thyroglossal cyst appears as a cyst like mass either at the level of the hyoid bone or inside the strap muscles.

Surgical resection is indicated for cosmetic appearance, recurrent infections, sinus and fistula formation and rarely suspicion of malignancy.<sup>15</sup> The treatment of choice for removing thyroglossal cysts is Sistrunk's operation.<sup>16</sup>

Hawkins et al proposed that Sistrunk's procedure is associated with recurrence rates of only 2 to 8%, but when the hyoid bone is not removed, the recurrence rate is 85%. In our series, following Sistrunk's operation, no recurrence was observed.<sup>17</sup>

In more than 60% of cases, ectopic thyroid tissue is present in the cyst wall. This tissue can give rise to carcinoma.<sup>10</sup> So, detailed histological examination is essential not only to establish the diagnosis of a thyroglossal cyst, but also to exclude carcinoma. No ectopic thyroid tissue was found in our patients.

## CONCLUSION

- In all lateral presentations of cystic swellings of the neck in the absence of mobility during deglutition and tongue protrusion- a diagnosis of thyroglossal cyst should be considered.
- In all our cases, Sistrunk's operation was performed and no recurrence was observed.

## ACKNOWLEDGEMENTS

To our department staff and computer department.

## REFERENCES

1. Allard RH. The thyroglossal cyst. *Head Neck Surg* 1982;5(2):134-146.
2. Mondin V, Ferlito A, Muzzi E, et al. Thyroglossal duct cyst: personal experience and literature review. *Auris Nasus Larynx* 2008;35(1):11-25.
3. Ducic Y, Chou S, Drkulec J, et al. Recurrent thyroglossal duct cysts: a clinical and pathologic analysis. *Int J Pediatr Otorhinolaryngol* 1998;44(1):47-50.
4. Weldon BC, Krafcik JM. Breath-holding-like spells in an infant: an unusual presentation of lingual thyroglossal duct cyst. *J Pediatr Surg* 2000;35(9):1381-1384.
5. Asmat SI. Thyroglossal duct cyst: a descriptive study of 41 cases. *J Postgrad Med Inst* 2010;24(3):231-233.
6. Dedivitis RA, Camargo DL, Peixoto GL, et al. Thyroglossal duct: a review of 55 cases. *J Am Coll Surg* 2002;194(3):274-277.
7. Chon SH, Shinn SH, Lee CB, et al. Thyroglossal duct cyst within the mediastinum: an extremely unusual location. *J Thorac Cardiovasc Surg* 2007;133(6):1671-1672.
8. Brousseau VJ, Solares CA, Xu M, et al. Thyroglossal duct cysts: presentation and management in children versus adults. *Int J Pediatr Otorhinolaryngol* 2003;67(12):1285-1290.
9. Tas A, Karasalihoglu AR, Yagiz R, et al. Thyroglossal duct cyst in hyoid bone: unusual location. *J Laryngol Otol* 2003;117(8):656-657.
10. Maran AG. Benign diseases of the neck. In: Kerr AG, ed. *Scott-Brown's otolaryngology*. 6<sup>th</sup> edn. Vol. 5. Oxford: Butterworth Heinemann 1997:1-4.
11. O'Hanlon DM, Walsh N, Corry J, et al. Aberrant thyroglossal cyst. *J Laryngol Otol* 1994;108(12):1105-1107.
12. Thompson CQ, Smith JW. Thyroglossal duct cyst presenting laterally. *JAMA* 1967;201:565-566.
13. Som PM, Smoker WRK, Curtin HD, et al, eds. Congenital lesions. In: Som PM, Curtin HD, eds. *Head and neck imaging*. 4<sup>th</sup> edn. St Louis: Mosby Year Book 2003:1828-1864.
14. Shahin A, Burroughs FH, Kirby JP, et al. Thyroglossal duct cyst: a cytopathologic study of 26 cases. *Diagn Cytopathol* 2005;33(6):365-369.
15. Brewis C, Mahadevan M, Bailey CM, et al. Investigation and treatment of thyroglossal cysts in children. *J R Soc Med* 2000;93(1):18-21.
16. Sistrunk WE. The surgical treatment of cysts of the thyroglossal tract. *Ann Surg* 1920;71(2):121-126.
17. Hawkins DB, Jacobsen BE, Klatt EC. Cysts of the thyroglossal duct. *Laryngoscope* 1982;92(11):1254-1258.