

SURGICAL MANAGEMENT OF CONGENITAL VASCULAR ANOMALIES WITH N BUTYL CYANOACRYLATE

Rajendra Prasad Dash¹, Biswajit Mishra²

HOW TO CITE THIS ARTICLE:

Rajendra Prasad Dash, Biswajit Mishra. "Surgical Management of Congenital Vascular Anomalies with N Butyl Cyanoacrylate". *Journal of Evidence based Medicine and Healthcare*; Volume 2, Issue 22, June 01, 2015; Page: 3259-3265.

ABSTRACT: BACKGROUND: Congenital vascular malformation is stressful both to the patient and the treating physician. Use of sclerosing agent followed by surgical excision has been used by many. In our study we have used percutaneous injection of N-butyl cyanoacrylate (NBCA) in such lesions to make these lesions amenable to easy excision. N Butyl Cyanoacrylate (NBCA) is a rapidly hardening liquid adhesive often referred to as glue. The substance polymerizes immediately on contact with blood or other ionic fluid. Polymerization result in an exothermic reaction that destroys the vessel wall obliterating the entire peripheral feeding vessel. The condensed mass is excised in toto. **STUDY DESIGN:** we have conducted a prospective study to evaluate the effectiveness of n butyl cyanoacrylate in the treatment of vascular anomalies. 30 cases were included. The amount of post-operative bleeding, tissue reaction, post-operative complications, and recurrence rate was noted. **RESULT:** Post-operative bleeding was minimal, less than 30 ml in our study. There was no tissue reaction. Only one case had post-operative infection. None had any recurrence. **CONCLUSION:** N butyl cyanoacrylate is safer and effective sclerosing agent for treatment of vascular malformation.

KEYWORDS: Congenital vascular malformation, Hemangioma, N Butyl cyanoacrylate, Sclerosant.

INTRODUCTION: Congenital vascular malformation (CVM) and tumor are rather unsightly lesions that most commonly occur in the childhood. Many classifications have been proposed for vascular anomalies. However mulliken classification of the lesions broadly into vascular tumors and malformations are now widely accepted.^{(1),(2),(3)} Congenital vascular malformation still remain as one of the most difficult and confusing diagnostic and therapeutic enigma due to (1) wide range of clinical presentation and unpredictable course. (2) Poor understanding of anatomy and pathophysiology of the lesion. (3) High morbidity related to various surgical and non-surgical treatment. (4) High recurrence rate following treatment. Early aggressive approach to CVM by vascular surgeon alone on the basis of limited experience and knowledge brought unacceptable treatment with high morbidity and mortality. Different modalities of treatment like observation, pressure by local bandaging,⁽⁴⁾ laser therapy,⁽⁵⁾ cryotherapy,^(6,7) cauterisation, use of steroids,⁽⁸⁾ high selective embolisation^(9,10) and surgical resection have evolved through years. Injection of sclerosant materials is also another method for treatment. Ideal sclerosant should fulfil requirement for the long term safety, ease of handling and delivery, ability to reach and occlude the nidus besides permanent destruction of the lesion with no recurrence. N Butyl Cyanoacrylate (NBCA)⁽¹¹⁾ is a rapidly hardening liquid adhesive often referred to as glue The substance polymerizes immediately on contact with blood or other ionic fluid. Polymerization result in an exothermic reaction that destroys the vessel wall obliterating the entire peripheral feeding vessel. The

ORIGINAL ARTICLE

condensed mass is excised in toto. In our study we have used N- Butyl cyanoacrylate as a sclerosant for the treatment of hemangiomas and malformation.

MATERIAL AND METHODS: Our study includes 30 cases between 2008 to 2011 presented to the department of surgery, pediatric surgery and plastic surgery. 22 cases were malformations and 8 cases were involuting hemangiomas. Patient's age ranged from 4 year to 40 year. 12 case (40%) were in head and neck, 12(40%) in upper limb, 4(13%) in the lower limb and 2 cases (6%) were in trunk. male 20 cases (66.33%) female (33.33%). Diagnosis was done by clinical examination and color Doppler ultrasound. All the head and neck lesions were taken up by general anesthesia and the rest were treated by regional anesthesia under all available aseptic conditions NBCA was injected in to the lesion after compressing the lesion. The quantity of NBCA is roughly calculated taking in to consideration the diameter and the height of the lesion. All lesions are roughly taken as hemisphere and the volume is calculated as $\pi r^2 / h$.

NBCA produces an exothermic reaction raising the temperature up to 60⁰ C To minimize the effect of heat ice packs are applied for 3-5 minutes after the injection of the sclerosant. The lesion is condensed to a hard mass. The mass is excised in Toto. After attaining homeostasis wound is closed over a suction drain. None of the cases had significant bleeding during surgery. Negative suction was given in 6 cases for 24 hours, but none had drain collection more than 10 ml. None of the patients required any blood transfusion. One of our cases had wound infection which was well under control. Rest all had excellent cosmetic result. All patients were discharged on third day of surgery. During a span of 2 years there was a follow up for 22 months in 12 cases, 14 months for 10 cases, and 10 month for 6 cases, 4 months for 2 cases. There was no recurrence reported.

DISCUSSION: In 1982, Mulliken and Glowacki classified hemangiomas based on the cellular biology and natural history of these lesions, dividing vascular birthmarks into two groups: hemangiomas and vascular malformations.⁽¹⁾ A modification of this classification system was accepted by the International Society for the Study of Vascular Anomalies in 1996.^(2,3) Hemangiomas are the most common tumors of infancy. The true incidence of infantile hemangiomas is unknown. Although they are classically said to occur in up to 10 percent^(2,3) of Caucasian infants 4 to 5 percent is probably a better estimate.⁽¹²⁾ Infantile hemangiomas are generally noticed within the first few days to months of life. Although most hemangiomas occur sporadically, familial transmission in an autosomal dominant fashion has been reported.⁽¹³⁾ Hemangiomas can be seen in 1.1% to 2.6% of term neonates,^(12,13) and their frequency is estimated to be as high as 10% to 12% within the first year of life.⁽¹⁴⁾ Among Indian studies, a prevalence varying from 0.1% to 0.28% has been reported. Female infants are three times as likely to have hemangiomas as compared to male infants, and there is an increased incidence of premature and low-birth weight babies.^(15,16) Approximately 55% of these tumors are present at birth, and 45% develop in the first weeks of life. By chorionic villous sampling⁽¹⁷⁾ at 9-12 weeks of gestation we can know which infants will develop hemangioma after birth.

The incidence of vascular lesion in our pediatric department is around 1%.The number of patients turning up for the treatment for these lesion in early childhood is rare owing to the poor socioeconomic status and literacy and wait and watch policy advised by local practitioners.

ORIGINAL ARTICLE

Male: Female ratio is 3:1 in our study. It is just opposite to the study by Mulliken. It reflects more concern of the parents towards male child in this part of the world.

In our study 40% were in head and neck, 40% in upper limb, 13% in the lower limb, 6% in the trunk. This is different from the study by Finn et al.⁽¹⁸⁾ Finn et al., in a large series, found that 60% of hemangiomas occurred on the head and the neck, 25% on the trunk and 15% on the extremities.

Richie L. Lin reported cases of multiple hemangiomas.⁽¹⁹⁾ Majority (80%) of patients has a single hemangioma; others have multifocal ones. Multiple hemangiomas is also called hemangiomatosis. They appear as multiple lesions. In our series only one patient had multiple vascular lesions. Though most vascular lesions are sporadic some may be the result of an autosomal dominant trait. One study suggests the association with mutational events that result in a loss of heterozygosity at a specific locus on chromosome 5 (Berg, 2001). In the present study no patient had family history suggestive of vascular lesions. Richards J. Antaya reported that surgical excision of involuted hemangioma is not uncommon because of cutaneous marking resulting from them.⁽²⁰⁾ Surgical excision of proliferating hemangiomas is quite hazardous because of risk of hemorrhage and damage to vital structures associated with them.

Han M. et al⁽²¹⁾ evaluated the use of NBCA for preoperative embolisation for arteriovenous malformation. 14 patients with CVM were treated with injection of NBCA. Lesions were percutaneous punctured with 20 G needle and NBCA was injected during venous compression. The lesions were devascularised and successfully extirpated with no notable blood loss. All patients underwent the procedure under general anesthesia for head and neck lesions and regional anesthesia for other lesions.

Lee B.⁽²²⁾ reported 6 cases of CVM located at surgically accessible areas which were treated with preoperative embolosclectherapy with NBCA. Minimal intraoperative and post-operative morbidity especially dramatic reduction of blood loss during surgical excision was the major achievement for surgical therapy.

Vikas Mallik et al⁽²³⁾ reported 2 cases where NBCA was used for sclerotherapy for CVM over the soft palate since birth that had occasionally bled. Preoperative blood loss was minimal. Another case of tonsillar hemangioma was devascularised with NBCA and followed up by left tonsillectomy along with excision of hemangioma. Preoperative blood loss was negligible and good plane of cleavage was obtained.

NBCA has been used by various authors for craniofacial lesion and peripheral hemangiomas.⁽²⁴⁾ It has also been used for the treatment of laryngeal hemangiomas. Roy et al⁽²⁵⁾ have used NBCA for treatment of venous malformation and unresolved hemangiomas. Initially it was not used for the fear of toxicity but now NBCA has been approved by FDA. There are various formulations of cyanoacrylate. Cyanoacrylate compounds are often used for embolisation of arteriovenous malformations by intervention radiologist, vascular surgeons, and general surgeons^(26,27) as they have low tissue reactivity and toxicity. Their liquid consistency allows easy injection into small-bore catheters. Unlike methylmethacrylate compounds there is no late solidification which may make surgery difficult. The exact dose of NBCA has not been described anywhere. Roy et al⁽²⁵⁾ have described various doses according to the size of the lesion. We have used the formula of $\pi r^2 / h$ to simplify the calculation of the dose. We have not encountered any toxicity due to its injection.

ORIGINAL ARTICLE

CONCLUSION: NBCA fulfills all the safety criteria for an ideal embolosclosing agent in terms of safety, ease of handling, ability to reach and occlude the nidus and permanent ablation of the lesion. NBCA is a useful sclerosing agent for the treatment of vascular malformation.

REFERENCES:

1. Mulliken JB, Glowacki J. Hemangiomas and vascular malformations in infants and children: A classification based on endothelial characteristics. *Plast Reconstr Surg* 1982; 69: 412-20.
2. Enjolras O, Mulliken JB. Vascular tumors and vascular malformations (new issues). *Adv Dermatol* 1997; 13: 375-423.
3. Garzon MC, Enjolras O, Frieden IJ. Vascular tumors and vascular malformations: Evidence for an association. *J Am Acad Dermatol* 2000; 42: 275-9.
4. Kaplan M, Paller AS. Clinical use of self-adhesive compressive wraps in the limb hemangiomas. *Am J Dermatol* 1995 Jan. 32(1); 117-8. (medicine5)
5. Dixon JA, Davis RK, et al, Laser photocoagulation of vascular malformations of tongue. *Laryngoscope* 1986 May 96: 537-41.
6. Godwin RM, Rosoff CB. Cryosurgery for large hemangiomas in adults. *Plast Reconstr Surg* 1969 June 43(6) 605-11.
7. Gongloff RK, treatment of intraoral hemangiomas with nitrous oxide cryosurgery. *Oral Surg, Oral Med, Pathol* 1983 July, 56(1) 20-4.
8. Brown, SH Jr, Nearhout et al. Prednisolone therapy in the management in children and infants. *Surgery*, 1972 FEB 71(2), 168-73.
9. Chok J, Williams DM, Brady TM et al, Transcatheter Embolisation with sodium Tetracycl Sulphate. Experimental and clinical results. 1984 Oct. 153(1):95-99.
10. Kaufman SL, Martin LC, Zuckerman AM et al. Peripheral transcatheter embolism with microcoils. *Radiology*, 1992, Aug. 1984. 20:360-72.
11. Dotter CT, Goldman ML, Rosch J. Instant selective arterial occlusion with isobutyl Cyanoacrylate. *Radiology*, 1975, Jan. 114(1), 227-230.
12. Pratt AG. Birthmarks in infants. *Arch Derm Syphilol* 1953; 67: 302-5.
13. Jacobs AH, Walton RG. The incidence of birthmarks in the neonate. *Pediatrics* 1976; 58: 218-22.
14. Jacobs AH. Strawberry hemangiomas: The natural history of the untreated lesion. *Calif Med* 1957; 86: 8-10.
15. Powell TG, West CR, Pharoah PO, Cooke RW. Epidemiology of strawberry haemangioma in low birthweight infants. *Br J Dermatol* 1987; 116: 635-41.
16. Amir J, Metzker A, Krikler R, Reisner SH. Strawberry hemangioma in preterm infants. *Pediatr Dermatol* 1986; 3: 331-2.
17. Burton BK, Schulz CJ, Angle B, Burd LI. An increased incidence of hemangiomas in infants born following chorionic villus sampling (CVS). *Prenat Diagn* 1995; 15.
18. Finn MC, Glowacki J, Mulliken JB. Congenital vascular lesions: Clinical application of a new classification. *J Pediatr Surg* 1983; 18: 894-900.
19. Riche L. Lin. MD. UMDN. *New Jersey Medical Journal*, 2004, October 2008. P. 24-28.

ORIGINAL ARTICLE

20. Richard Antaya et al. Surgical Excision of involuted hemangiomas. *Br.J.Plast. Surg.* 2003. Aug. 4(3),270-5.
21. Han MH, Seong SO, Kim HD, Chang KH, Yeon KM, Han MC. Craniofacial arteriovenous malformation: Preoperative embolization with direct puncture and injection of n-butyl Cyanoacrylate. *Radiology* 1999; 211:661-6.
22. Lee BB, Bergan JJ. Multidisciplinary approach for vascular malformation, Arterio Venous fistula and venous malformation by both ethanol and NBCA as sclerotherapy Agent. *Cardio Vasc Surg Dec.*, 2002; 10:823-33.
23. Vikas Mallik et al, *Br. J. Plast Surg.* 2002 Dec.23(4).12507.
24. De Merritt JS, Pile-Spellman J, Mast H, Moohan N, Lu DC, Young WL, et al. Outcome of analysis of pre-operative embolization with N-butyl cyanoacrylate in cerebral arterio Venous malformation. *AJNR Am J Neuroradiol* 1995; 16:1801-7.
25. Ashim kumar Roy 1, Bijay kumar Majumdar, Saswati Majumdar, Management of unresolved hemangiomas and venous malformations by N-butyl cyanoacrylate *IJPS* 2007; 40:8-11.
26. Kesavdas C, Joseph S, Gupta AK, Nair R, Rao VR. Selective catheterization of external Carotid artery feeder and embolization with hydrogel only b) hydrogel foam c) gel foam and d) direct percutaneous puncture and injection of N-butyl Cyanoacrylate. *J Plast Surg* 2000; 33:58-64.
27. Pollok JS, White RJ Jr. The use of Cyanoacrylate adhesive in peripheral embolisation. *J Vasc Interv Radial* 2001; 12: 907-13.

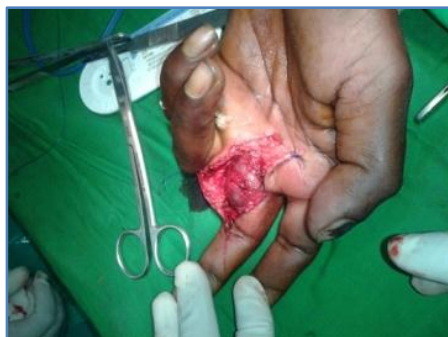

FIG. 1. CASE 1: CVM finger after injection of NBCA

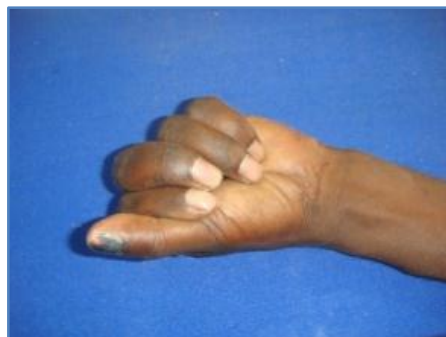

FIG. 2. CASE 1: Post op CVM finger. Full-flexion after excision of the mass



FIG. 3. CASE 1: Post op CVM. Full extension after excision of the lesion

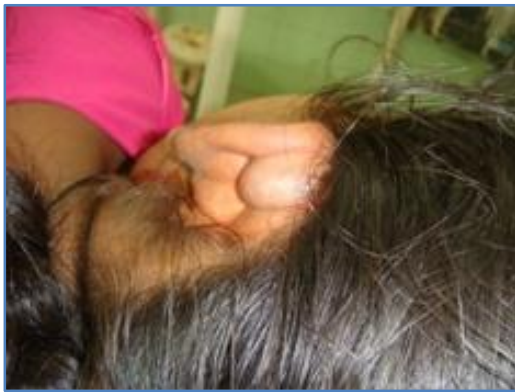

FIG. 4. CASE 2: Venous Malformation of Ear



FIG. 5. CASE 2: Excised Mass in TOTO after NBCA administration

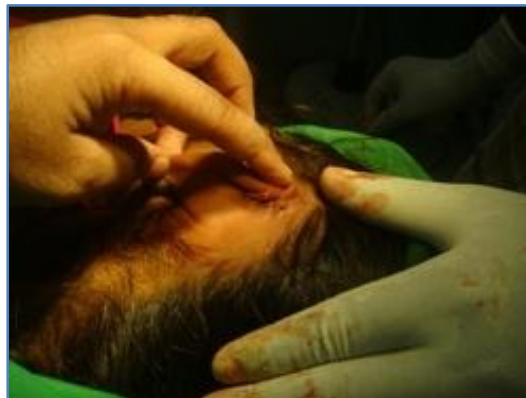

FIG. 6. CASE 2: Post Op Appearance after Excision of the Lesion

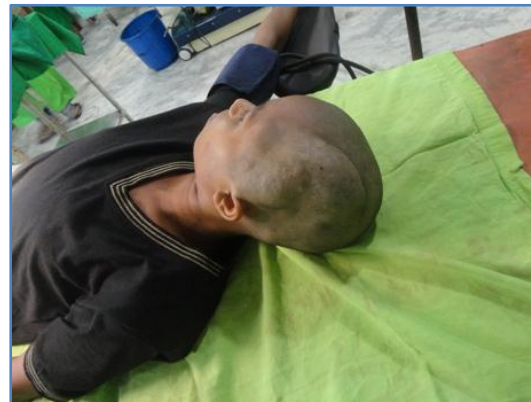
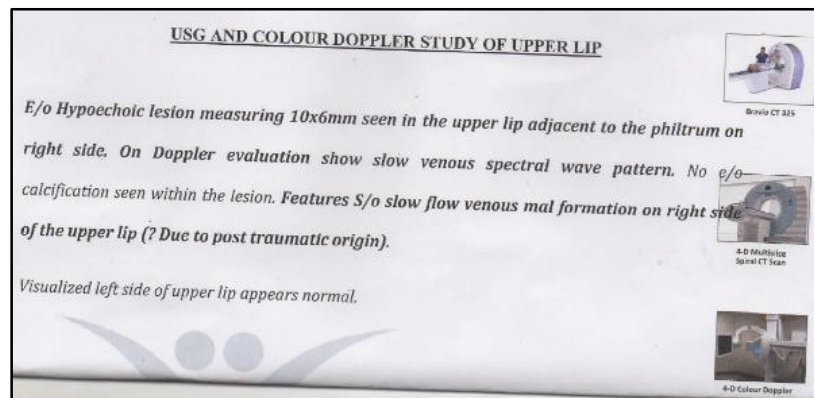


FIG. 7: Venous malformation of scalp

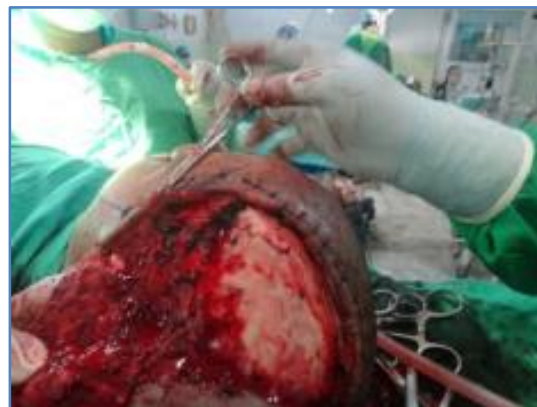
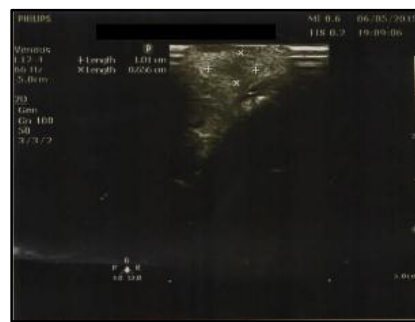
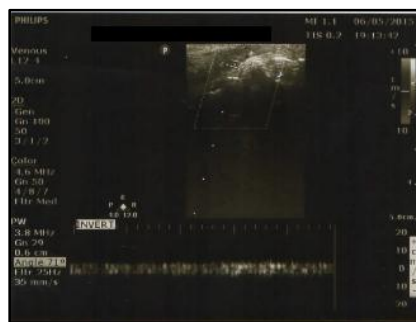FIG. 8. CASE 3: Intra Op Photograph of the Excision of Venous Malformation of Scalp

ORIGINAL ARTICLE



AUTHORS:

1. Rajendra Prasad Dash
2. Biswajit Mishra

PARTICULARS OF CONTRIBUTORS:

1. Associate Professor, Department of Plastic Surgery, M.K.C.G. Medical College, Berhampur, Orissa.
2. Assistant Professor, Department of Plastic Surgery, M.K.C.G. Medical College, Berhampur, Orissa.

NAME ADDRESS EMAIL ID OF THE CORRESPONDING AUTHOR:

Dr. Biswajit Mishra,
Assistant Professor,
Department of Plastic Surgery,
M.K.C.G. Medical College,
Berhampur, Orissa.
E-mail: drbmpl78@gmail.com

Date of Submission: 18/04/2015.
Date of Peer Review: 19/04/2015.
Date of Acceptance: 19/05/2015.
Date of Publishing: 28/05/2015.