

## STUDY OF A NOVEL INDEX MITRAL LEAFLET SEPARATION INDEX BY 2-DIMENSIONAL ECHOCARDIOGRAPHY TO ASSESS THE SEVERITY OF MITRAL STENOSIS

Sumeet Garg<sup>1</sup>, Deepesh Agarwal<sup>2</sup>, Mohammed Shoaib<sup>3</sup>, Rupendra Kumar Bhatt<sup>4</sup>

<sup>1</sup>Assistant Professor, Department of General Medicine, Mahatma Gandhi Medical College and Hospital, Jaipur, Rajasthan, India.

<sup>2</sup>Associate Professor, Department of Cardiology, Mahatma Gandhi Medical College and Hospital, Jaipur, Rajasthan, India.

<sup>3</sup>Senior Demonstrator, Department of Pharmacology, National Institute of Medical Sciences and Research, Jaipur, Rajasthan, India.

<sup>4</sup>Senior Demonstrator, Department of Pharmacology, National Institute of Medical Sciences and Research, Jaipur, Rajasthan, India.

### ABSTRACT

#### BACKGROUND

Mitral stenosis results due to structural abnormality of the mitral valve apparatus, which prevents proper opening of mitral valve during diastole. The Mitral Valve Area (MVA) can be measured by planimetry, pressure half time, continuity equation and proximal isovelocity surface area methods. Direct measurement of MVA by planimetry is accurate, but highly operator dependent and laborious. The novel index proposed by Seow in 2006. This is a mitral leaflet separation index, henceforth referred as MLS index, which is independent measure assessment of severity of mitral stenosis.

#### MATERIALS AND METHODS

The study was a prospective done from July 2014 to October 2014 in Mahatma Gandhi Medical College and Hospital, Jaipur, Rajasthan. Fifty consecutive cases of mitral stenosis without significant other valvular lesion presenting to the Medicine OPD were studied. Identified the severity of mitral stenosis with the help of clinical, radiological, electrocardiographic features and correlates them with new index Mitral Leaflet Separation Index (MLS) with the help of two-dimensional echocardiography.

#### RESULTS

Mitral leaflet separation index was measured in all patients, of which, 12 patients (24%) were in mild mitral stenosis group. Moderate mitral stenosis was found in 13 (26%) patients, whereas 25 (50%) patients belongs to severe group. The mitral valve area by planimetry and pressure half time was correlated with mitral leaflet separation index and analysed with regression analysis, which suggest significant correlation in them. The correlation coefficient was  $(r) = 0.9551$  and P value was  $<0.0001$  was significant for the study.

#### CONCLUSION

The mitral leaflet separation index is a reliable measure of mitral stenosis severity and is technically easy to obtain. This new index could be a useful surrogate measure of the mitral valve area. This study almost conclusively states that the novel index-MLS index is decisive in assessing the severity of mitral stenosis.

#### KEYWORDS

Novel Index Mitral Leaflet Separation Index by 2-Dimensional Echocardiography.

**HOW TO CITE THIS ARTICLE:** Garg S, Agarwal D, Shoaib M, et al. Study of a novel index mitral leaflet separation index by 2-dimensional echocardiography to assess the severity of mitral stenosis. J. Evid. Based Med. Healthc. 2017; 4(95), 5902-5907. DOI: 10.18410/jebmh/2017/1190

#### BACKGROUND

Rheumatic heart disease has been one of the major forms of heart disease in developing countries like India. Mitral stenosis results due to structural abnormality of the mitral

*Financial or Other, Competing Interest: None.*

*Submission 04-12-2017, Peer Review 09-12-2017,*

*Acceptance 18-12-2017, Published 19-12-2017.*

*Corresponding Author:*

*Dr. Deepesh Agarwal,*

*Associate Professor, Department of Cardiology,*

*Mahatma Gandhi Medical College and Hospital,*

*RIICO Institutional Area, Sitapura,*

*Jaipur-302022, Rajasthan, India.*

*E-mail: drdeepeshagarwal@gmail.com*

*DOI: 10.18410/jebmh/2017/1190*

valve apparatus, which prevents proper opening of mitral valve during diastole. Eventually, it means obstruction to left ventricle inflow at the level of the mitral valve. The predominant cause of mitral stenosis is rheumatic fever. About 25% of all patients with rheumatic heart disease have isolated mitral stenosis.<sup>1</sup> The ratio of women to men presenting with isolated mitral stenosis is 2:1.<sup>2</sup> About 40% have combined mitral stenosis and mitral regurgitation.<sup>3</sup> It results in characteristic changes of the mitral valve with the diagnostic features being thickening at the leaflet edges, fusion of the commissures and chordal shortening and fusion.<sup>4</sup>

As compared to the developed countries, the prevalence of rheumatic heart disease is quite high in India. A number of studies have attempted to document incidence of



Rheumatic Fever (RF) and prevalence of Rheumatic Heart Disease (RHD) in India through a variety of methods.<sup>5-8</sup> In India, the prevalence of RF/RHD among school children is 2-11 per 1000 with a mean of 6 per 1000.<sup>5</sup>

Determining the severity of mitral stenosis is important for both prognostic and therapeutic reasons.<sup>9</sup>

Two-dimensional (2D) Doppler echocardiography is presently the gold standard method for assessment of severity of mitral stenosis. The Mitral Valve Area (MVA) can be measured by planimetry, pressure half time, continuity equation and proximal isovelocity surface area methods.<sup>10,11</sup>

In this work, we study the novel index proposed by Seow et al in 2006. This is a mitral leaflet separation index, henceforth referred as MLS index, which is independent measure assessment of severity of mitral stenosis.

**MATERIALS AND METHODS**

The study is prospective study to evaluate the severity of mitral stenosis in relation to clinical, electrocardiographical, radiological and a new index mitral leaflet separation index by two-dimensional echocardiography. The data was analysed by applying linear regression method. During the study period, 50 consecutive cases of mitral stenosis without significant other valvular lesion presenting to the Medicine OPD were studied.

Patients those were having isolated mitral stenosis included in the study and those having with multiple valvular diseases, congenital mitral stenosis, mitral stenosis with significant mitral regurgitation and mitral stenosis due to acquired aetiology were excluded.

This study aimed at identifying the severity of mitral stenosis with the help of clinical, radiological, electrocardiographic features and correlates them with the new index Mitral Leaflet Separation Index (MLS) with the help of two-dimensional echocardiography.

In each patient, detailed history and clinical examination was taken. A 12-lead ECG was done and to evaluate possible aggravating factors and/or alternative diagnoses, chest x-ray, complete blood count and other relevant biochemical profile was done.

Severe MS was defined as a MVA of 1 cm<sup>2</sup> or less by planimetry or pressure half-time method and/or a mean transmitral gradient of greater than 10 mmHg. Moderate MS was defined as a MVA between 1 cm<sup>2</sup> and 1.5 cm<sup>2</sup> by planimetry or pressure half-time method with a mean transmitral gradient of 5 to 10 mmHg. Mild MS was defined as a MVA of greater than 1.5 cm<sup>2</sup> by planimetry or pressure half-time and/or a transmitral gradient of less than 5 mmHg.<sup>12</sup>

The maximal separation of the mitral valve leaflet tips was measured (from inner edge to inner edge) in diastole in the parasternal long-axis and apical 4-chamber views. These two parameters were averaged to yield the MLS index. A mean of this was taken as MLS index.

For patients in atrial fibrillation, 5 measurements were obtained in PLAX and in apical four chamber view. A mean of this was considered as MLS index. All measurements were

made by a single operator blinded to the mitral valve area and transmitral gradient.

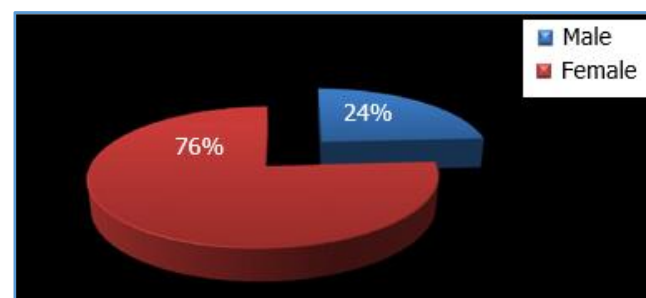
Mitral leaflet separation index was compared with mitral valve area by planimetry and pressure half time. In taking the dimensions, the recommendations of the American Society of Echocardiography were followed.<sup>13</sup>

**RESULTS**

**Gender Characteristics-** The patients enrolled into this study in our centre comprised of 50 consecutive patients. Out of these, 38 were female and 12 were male patients. The ratio of female-to-male in study is about 3:1.

Sex	Patients	Percentage
Male	12	24%
Female	38	76%
<b>Total</b>	<b>50</b>	<b>100%</b>

*Table 1. Gender Characteristics of the Study Population*



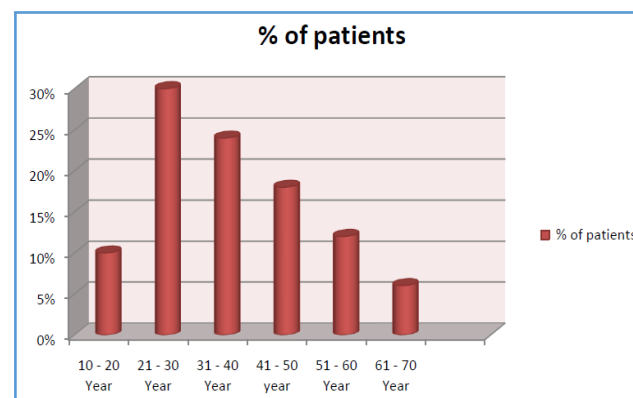
**Figure 1. Gender Characteristics of the Study Population**

**Age Distribution**

The age distribution of patients in this study was varying, but large group was below 30 years of age. The average age of a study subject was 37.44 years. There were 3 patients over age 60 years.

Age Group	Patients
10-20 years	5
21-30 years	15
31-40 years	12
41-50 years	9
51-60 years	6
61-70 years	3
71-80 years	0
<b>Total</b>	<b>50</b>

*Table 2. Distribution of Patients in Various Age Groups*

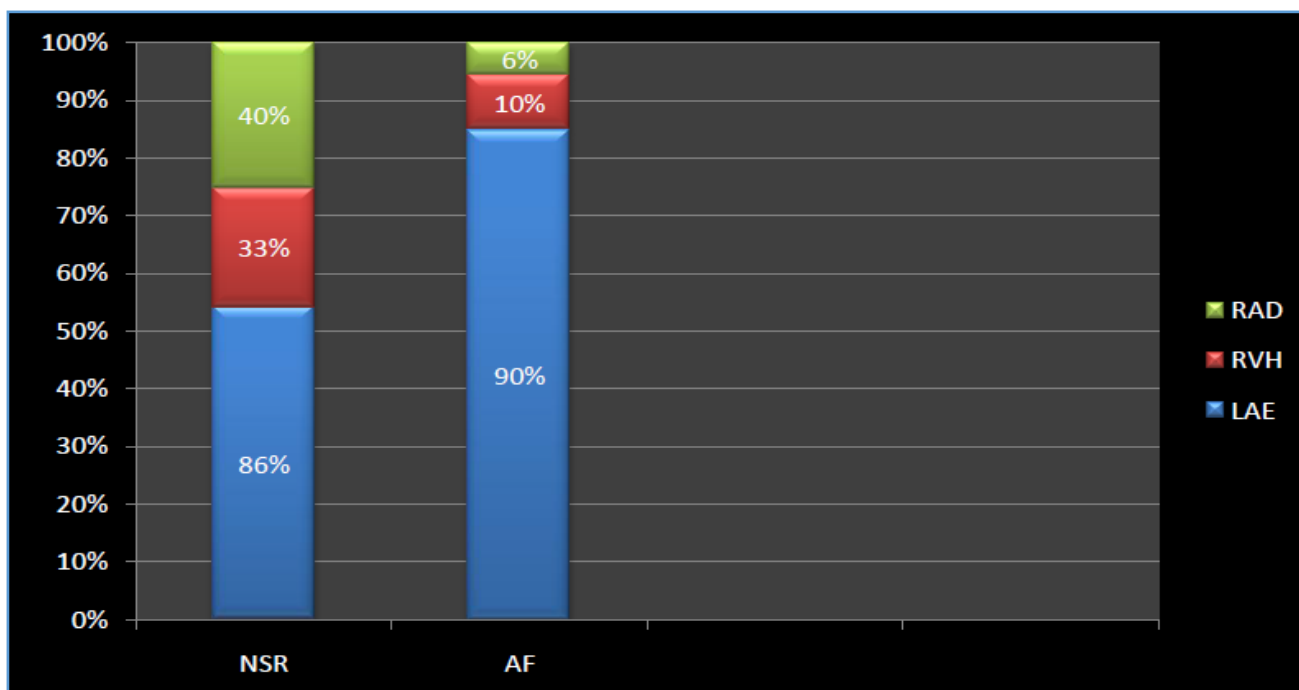


**Figure 2. Age Specific Prevalence of Patients**

**Electrocardiographic (ECG) Evaluation-** A standard 12-lead ECG was obtained for all patients enrolled in this study and were scrutinised for evidence of left atrial enlargement and right ventricular hypertrophy.<sup>14</sup> On the electrocardiogram, 86% patients of normal sinus rhythm had left atrial enlargement<sup>15</sup> and 90% of patients with AF had left atrial enlargement. 39 (78%) patients had normal sinus rhythm, 10 (20%) had AF. Right ventricular hypertrophy by voltage criteria was found in 33% of patients from the study group. One patient from study group was presented with intermittent WPW syndrome.

ECG	Patients	Left Atrial Enlargement	Right Ventricular Hypertrophy	Right Axis Deviation
Normal sinus rhythm	39	86%	33%	40%
Atrial fibrillation	10	90%	10%	6%

**Table 3. ECG Features in Study Group**



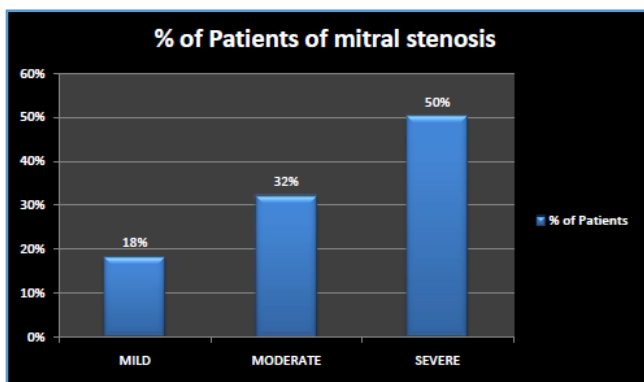
**Figure 3. Electrocardiographic Parameters Studied in Patients**

**Echocardiographic Evaluation-** All the patients selected for this study underwent echocardiographic evaluation by 2D echocardiography and colour Doppler. Mitral valve area was calculated by planimetry. There were 9 (18%) mild mitral stenosis, 16 (32%) patients of study were moderate mitral stenosis and 25 (50%) were severe. The above data of the severity of the mitral stenosis was correlated with clinical features, chest x-ray and ECG features. It shows increasing trend of severity in each group as severity of mitral stenosis increased.

This data then compared with mitral valve area, which was calculated by pressure half time. There were 28% of patients belonged to mild mitral stenosis group. Twenty two (44%) of patients belonged to severe group.

**Echocardiographic Abnormalities Seen among the Three Groups of Patients with Comparison by Two Methods-**

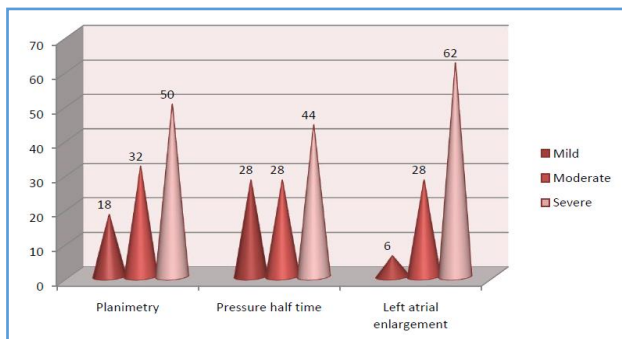
Three patients (6%) from study group had mild left atrium dilatation, while 14 (28%) patients had moderate left atrium dilatation. Severely-dilated left atrium was seen in 62% of patients. This suggests the severity of disease increased as pressure increases.



**Figure 4. Mitral Valve Area by Planimetry**

Echocardiography	Mild	Moderate	Severe
MVA by planimetry	18%	32%	50%
MVA by pressure half time	28%	28%	44%
Left atrial enlargement	6%	28%	62%

**Table 4. Echocardiography**

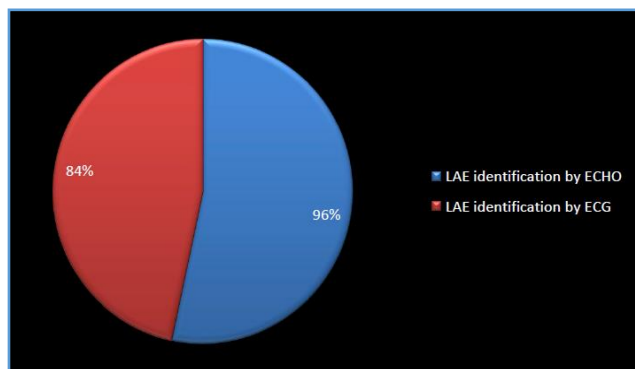


**Figure 5. Echocardiographic Abnormalities Seen among the Three Groups of Patients**

**Comparison of Difference in Percentage in Identifying Left Atrial Enlargement-** Left atrial enlargement was calculated by echocardiography and electrocardiogram was compared in the study. There were total 96% patients have left atrial enlargement on echocardiography, while 84% patients had left atrial enlargement on electrocardiography.

	Total Patients	LAE
LAE identification by echo	50	48 (96%)
LAE identification by ECG	50	42 (84%)

**Table 5. Comparison of Showing Left Atrial Enlargement on Echo and ECG**

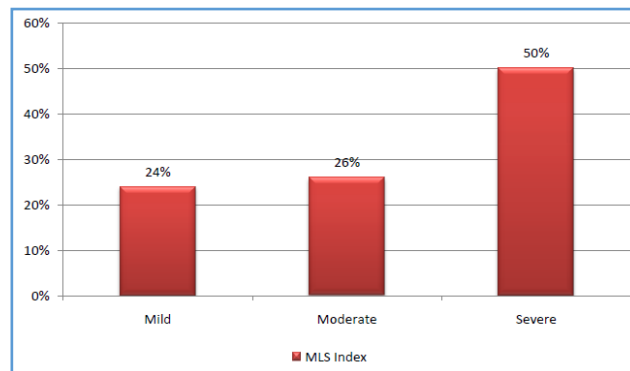


**Figure 6. Pie Chart Comparison Showing Left Atrial Enlargement on Echo and ECG**

**Mitral Leaflet Separation Index-** As stated by Seow et al,<sup>16</sup> the cut-off value of 0.81 cm or less is identified as severe MS with 92.3% sensitivity and 100% specificity, while a cut-off value of 1.11 cm or more identified as mild MS with 85.7% sensitivity and 100% specificity. Hence, the categorically-differentiated MLS index as follows- mild 0.95 cm to 1.25 cm, moderate 0.85 cm to 0.94 cm and severe 0.40 cm to 0.84 cm. So, in our study, the patients were categorised in relation to normal sinus rhythm and atrial fibrillation.

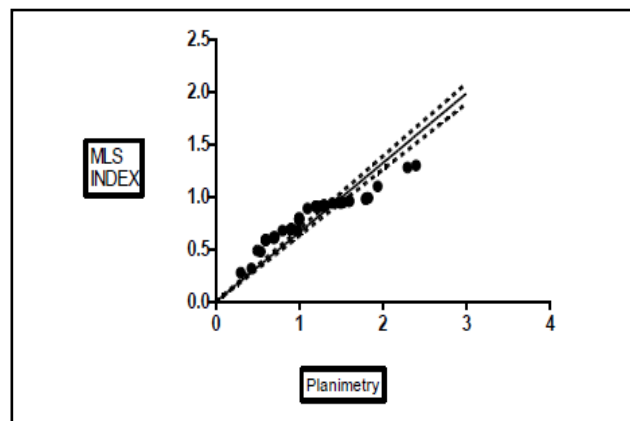
The MLS index was estimated by measuring the maximal separation of tip of the mitral leaflet in end diastole in Parasternal Long Axis (PLAX) view and apical 4-chamber view (A4C view).<sup>16</sup> There were 39 patients of sinus rhythm in which 3 measurements were obtained in PLAX view and in A4C view. 10 patients of AF were there in which 5 measurements were taken in PLAX view and in A4C view.

There were 12 patients (24%) of mild mitral stenosis as per MLS index. Moderate mitral stenosis was found in 13 patients (26%), whereas 25 patients (50%) belongs to severe group.



**Figure 7. Mitral Leaflet Separation Index (MLS)**

Linear regression analysis was used to correlate with MLS index against MVA assessed by planimetry. The MLS index for mild, moderate and severe MS were analysed using analysis of variance to determine if the index could differentiate categories of MS.



**Figure 8. Linear Regression Graph of MLS with MVA by Planimetry**

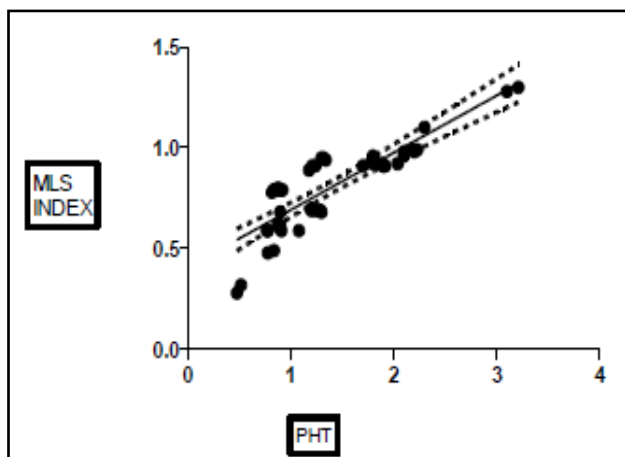
Parameters	Value	Error	From	To
Slope	0.4168	0.01866	0.3792	0.4544
Y intercepts	0.3268	0.02321	0.2800	0.3735
X intercept	-0.7839			

**Table 6. NLS Index with MVA by Planimetry**

Correlation coefficient (r) = 0.9551 r squared = 0.9122. Standard deviation of residuals from line (Sy.x) = 0.06183.

The P value is <0.0001 considered extremely significant.

In the following linear regression graph, mitral valve area by pressure half time was used to correlate with mitral leaflet separation index.



**Figure 9. Linear Regression Graph of MLS Index with MVA by Pressure Half Time**

Number of points = 50.

Parameters	Value	Error	From	To
Slope	0.2838	0.02410	0.2352	0.3323
Y intercepts	0.4078	0.03706	0.3332	0.4824
X intercept	-1.437			

**Table 7. MLS Index with MVA by Pressure Half Time**

Correlation coefficient (r) = 0.8618; r squared = 0.7428. Standard deviation of residuals from line (Sy.x) = 0.1058. The P value is <0.0001 considered extremely significant.

**DISCUSSION**

The prevalence of Rheumatic Heart Disease (RHD) is now recognised to be very high in Indian subcontinent particularly among children and young adults.<sup>5</sup>

**Gender Characteristics of the Study Population-** In the present study, only 12 patients (24) were males and 38 patients (76%) were females. The ratio of male-to-female was 1:3, which correlate well with the history of mitral stenosis.<sup>17</sup> As per stated by Wood et al, the significant cases of mitral stenosis were female. 5 patients (10%) were with pregnancy and diagnosed to have mitral stenosis when consulted for dyspnoea on exertion. Two patients underwent normal delivery with a normal and healthy baby.

These findings in the present study correlate well with findings of Ramakrishna et al<sup>9</sup> who has demonstrated higher prevalence of mitral stenosis in females than males. In this study, the average male patient percentage was less about 10% as compared to other studies. The predominant of female patient was seen in our study.

**Age Characteristics-** The age of participants in the study ranged from 10 years to 80 years. The average age of study subject was 37.44 years. In this, large prevalence was seen in 21-30 years age group patients, which was 30%. This data correlate well with the study of valvular heart disease in Indian subcontinent.<sup>18</sup> Five patients (10%) were below 20 years of age. They had been diagnosed earlier to have mitral stenosis with significant severity and hence referred for early cardiac evaluation. There were only 3 patients (6%) who

were above 60 years of age. Braunwald et al<sup>19</sup> also detailed that the average age of patients in India is early as compared to the western population. Agarwal A K et al studied a large population in north India and came to conclusion that there was prevalence rate of 6.4 per 1000 of general rural population. So that, it was observed that the average age was less in the study group as compared to other studies.

In this study, dyspnoea and palpitation was the major clinical feature in severe as well as moderate MS (40% and 30%) and (44% and 26%) respectively as also depicted by P.K Sen et al.<sup>20</sup> The incidence of pleural effusion was higher than Ramakrishna et al (18% vs. 12%), respectively.<sup>9</sup>

In severe MS, the common finding on chest x-ray was Kerley B lines, pulmonary oedema and enlargement of pulmonary artery (44%, 32%, 30%), respectively. The evidence of this pulmonary oedema was associated well with the clinical features of orthopnea in 40% of patients. Another finding such as cardiomegaly were present 24% of patient with moderate-to-severe MS. According to Sen et al, the incidence of pleural effusion in MS is higher than our study (23% vs. 18%), respectively.<sup>20</sup> The chest x-ray features of the study group were correlated significantly with the severity of the disease and suggest that still chest x-ray is primary diagnostic tool to diagnose mitral stenosis.

The incidence of atrial fibrillation were 10 (20%), of which 70% patients had left atrial enlargement. Among these patients, 9 had severe mitral stenosis and 6 of them were above 50 years of age. The prevalence of atrial fibrillation increased with the increase in the age of patients in our series was similar to the observations made by others.<sup>9</sup> The incidence of RVH and RAD is also comparable with P.K. Sen et al<sup>20</sup> and Ramakrishna et al<sup>9</sup> (44% vs. 31% and 26%) and (46% vs. 38% and 41%), respectively.

Among all subjects, the incidence of severe MS was 50%, while moderate and mild MS was 32% and 18%, respectively. We also found that the incidence were much higher in females than male subjects. Left atrial enlargement was present among 96% of patients irrespective of the severity of MS as also shown by Seow et al<sup>21</sup> and Jacob Jose et al.<sup>22</sup>

Seow et al calculated MS by planimetry as well as by pressure half time.<sup>21</sup> Both the methods are equally safe for calculation of mitral valve area. The planimetry and pressure half-time method correlates in various studies shown the relevant significance in this study also.

The concept of mitral leaflet separation index was first described by Fisher et al,<sup>23</sup> but in 2006, Seow et al<sup>21</sup> demonstrated the procedure. In Mitral Leaflet Separation (MLS) index, maximal separation of the mitral valve leaflet tips was measured from inner edge to inner edge in diastole in parasternal long axis and apical 4 chamber views. In our study, there were 12 patients (24%) categorised in the mild mitral stenosis as per cut off value of mitral leaflet separation index. Moderate mitral stenosis was seen in 13 patients (26%) and severe mitral stenosis was calculated in 25 patients (50%) out of 50 patients. This data then correlated using linear regression analysis against MVA by planimetry. Correlation coefficient (r) was 0.9551 (P<0.001).

The correlation was made by pressure half time between mitral leaflet separation index with mitral valve area. There were 14 patients (28%) in mild mitral stenosis group. Moderate mitral stenosis was calculated in 14 patients and severe mitral stenosis consists of 44% patients from the study group. The correlation coefficient (r) was 0.8618 ( $P < 0.001$ ). Similar study was also conducted by Jacob Jose V et al<sup>22</sup> among 150 patients and was found to be effective to diagnose MS severity.

### CONCLUSION

The MLS index is a newer additional modality for the diagnosis of severity of mitral valve disease. It is feasible in the majority of the patients with mitral stenosis and demonstrates significant correlation with mitral valve area by planimetry and pressure half time method. It is also significantly different for different grades of mitral stenosis severity, so as to grade mild, moderate and severe. The main advantage of the mitral leaflet separation index is in its simplicity and less tedious measurement in comparison with planimetry. Further studies can be undertaken in a larger group to evaluate the specificity and sensitivity of MLS index.

### REFERENCES

- [1] Sagie A, Freitas N, Padial LR, et al. Doppler echocardiographic assessment of long-term progression of mitral stenosis in 103 patients: valve area and right heart disease. *J Am Coll Cardiol* 1996;28(2):472-479.
- [2] Bonow RO, Carabello BA, Kanu C, et al. ACC/AHA 2006 guidelines for the management of patients with valvular heart disease: A report of the American College of Cardiology/American Heart Association Task Force on Practice Guidelines (writing committee to revise the 1998 Guidelines for the Management of Patients with Valvular Heart Disease): Developed in collaboration with the Society of Cardiovascular Anesthesiologists: endorsed by the Society for Cardiovascular Angiography and Interventions and the Society of Thoracic Surgeons. *Circulation* 2006;114(5):e84-e231.
- [3] Perloff JK, Roberts WC. The mitral valve apparatus. Functional anatomy of mitral regurgitation. *Circulation* 1972;46(2):227-239.
- [4] Rahimtoola SH, Durairaj A, Mehra A, et al. Current evaluation and management of patients with mitral stenosis. *Circulation* 2002;106(10):1183-1188.
- [5] Padmavati S. Rheumatic fever and rheumatic heart disease in developing countries. *Bull WHO* 1978;56(4):543-550.
- [6] Agarwal AK, Yunus M, Ahmad J, et al. Rheumatic heart disease in India. *J R Soc Health* 1995;115(5):303-304, 309.
- [7] Sainani GS, Sainani AR. Rheumatic fever-How relevant in India today? *JAPI* 2006;54:42-47.
- [8] Mathur KS, Wahal PK. Epidemiology of rheumatic heart disease-a study of 29,922 school children. *Indian Heart Journal* 1982;34(6):367-371.
- [9] Ramakrishna CD, Khadar SA, George R, et al. The age-specific clinical and anatomical profile of mitral stenosis. *Singapore Med J* 2009;50(7):680-685.
- [10] Rifkin RD, Harper K, Tighe D. Comparison of proximal isovelocity surface area method with pressure half-time and planimetry in evaluation of mitral stenosis. *J Am Coll Cardiol* 1995;26(2):458-465.
- [11] Glover MU, Warren SE, Vieweg WV, et al. M-mode and two-dimensional echocardiographic correlation with findings at catheterization and surgery in patients with mitral stenosis. *Am Heart J* 1983;105(1):98-102.
- [12] Mishra A, Mishra C, Mohanty RR, et al. Study on the diagnostic accuracy of left atrial enlargement by resting electrocardiography and its echocardiographic correlation. *Indian J Physiol Pharmacol* 2008;52(1):31-42.
- [13] Feigenbaum H. Evolution of echocardiography. *Circulation* 1996;93:1321-1327.
- [14] Vasan RS, Shrivastava S, Vijayakumar M, et al. Echocardiographic evaluation of patients with acute rheumatic fever and rheumatic carditis. *Circulation* 1996;94(1):73-82.
- [15] Holen J, Aaslid R, Landmark K, et al. Determination of pressure gradient in mitral stenosis with a non-invasive ultrasound Doppler technique. *Acta Med Scand* 1976;199(6):455-460.
- [16] Acierno LJ, Worrell LT. Inge Edler: father of echocardiography. *Clin Cardiol* 2002;25:197-199.
- [17] Wood P. An appreciation of mitral stenosis. I. Clinical features. *Br Med J* 1954;1(4870):1051-1063.
- [18] Meenakshisundaram R, Thirumalaikolundusubramanian P. Valvular heart disease in Indian subcontinent: social issues. *Indian Journal of Community Medicine* 2009;34(1):57-58.
- [19] Braunwald E. Valvular heart disease. In: Braunwald E. edr. *Heart disease: a textbook of cardiovascular medicine*. 5<sup>th</sup> edn. Philadelphia, PA: WB Saunders 1997:1008-1012.
- [20] Sen PK, Pandey SR, Parulkar GB, et al. Mitral stenosis in young. *Dis Chest* 1966;49(4):384-392.
- [21] Seow SC, Koh LP, Yeo TC. Hemodynamic significance of mitral stenosis: use of a simple, novel index by 2 dimensional echocardiography. *Journal of the American Society of Echocardiography* 2006;19(1):102-106.
- [22] Vimal Raj BS, George P, Jose VJ. Mitral leaflet separation index - a simple novel index to assess the severity of mitral stenosis. *Indian Heart Journal* 2008;60(6):563-566.
- [23] Fisher ML, Parisi AF, Plotnick GD, et al. Assessment of severity of mitral stenosis by echocardiographic leaflet separation. *Arch Intern Med* 1979;139(4):402-406.