

SPECTRUM OF RARE CARCINOMAS IN BREAST A SINGLE INSTITUTE EXPERIENCEVijasree Mandava¹, Rajani Mutyala²**HOW TO CITE THIS ARTICLE:**

Vijasree Mandava, Rajani Mutyala. "Spectrum of Rare Carcinomas in Breast a Single Institute Experience". Journal of Evidence based Medicine and Healthcare; Volume 2, Issue 41, October 12, 2015; Page: 7008-7011, DOI: 10.18410/jebmh/2015/956

ABSTRACT: AIM: To evaluate the clinico pathological features of Metaplastic carcinomas. **METHODS:** Data of 11 patients with metaplastic breast carcinoma were retrospectively reviewed in a 3 years period. **RESULTS:** The patient's ages ranged from 28 years to 70 years (median 49years). The tumours were 4 to 10cm (median 7cm) in size. Patients underwent modified radical mastectomy and one patient underwent lumpectomy. One patient had axillary lymph node metastasis. TNM staging, tumour size and axillary nodal status were significant prognostic factors of survival. **CONCLUSIONS:** All the three subtypes of Metaplastic carcinoma are known to behave aggressively and should be differentiated from the low grade fibromatosis-like Metaplastic carcinoma. Which does not metastasise.

KEYWORDS: Carcino Sarcoma, Metaplastic Carcinoma.

INTRODUCTION: Metaplastic carcinomas of the breast are rare and interesting, yet confusing neoplasms. It has been reported that these tumors are most likely to occur in women older than 50 years. Metaplastic carcinomas of the breast exhibit a variety of histopathological patterns - both epithelial and mesenchymal patterns and appears to be both epithelial and mesenchymal in origin.⁽¹⁾ The reported incidence is 0.2% of all breast cancers. It includes various categories such as Sarcomatoid carcinoma/Carcinosarcoma, spindle cell carcinoma, Carcinoma with osteoclast like giant cells, Squamous cell, carcinoma and others

MATERIALS AND METHODS: During the period of 3 years from 2012 to 2014 eleven cases of Metaplastic carcinoma of the breast were reported in our institute. All the cases were formalin fixed routinely processed, haematoxylin and eosin stained. All the histological slides were reviewed and the diagnosis was confirmed. Each tumour was assessed for three components. Adenocarcinoma component, which morphologically showed glandular, or tubule formation or the presence of intracellular or extracellular mucin secretion.

- Squamous component: When cells showed characteristic polygonal appearance with a moderate amount of eosinophilic cytoplasm with identifiable intercellular bridges with or without keratin pearl formation.
- Sarcomatoid or spindle cell areas with the cells forming poorly cohesive sheets or with spindle cell morphology
- Biphasic with the tumour expressing the carcinoma component (Either adenocarcinoma or scc) and sarcomatoid or spindle cell component.
- Monophasic, with the tumour being formed exclusively by Sarcomatoid or spindle cell component.

ORIGINAL ARTICLE

RESULTS: All are females. A total of 11 Metaplastic carcinomas were included. Five cases had biphasic phenotype showing mixed Epithelial and Sarcomatoid or spindle cell components. Four cases had adenocarcinoma and the remaining one case showed SCC Epithelial component. Two cases showed a monophasic pattern composed entirely of sarcomatoid or spindle cells. Two cases showing epithelial phenotype only as squamous cell carcinoma. Age of the patients ranged from 28 years to 70 years (median 49 years). Two patients were younger than 50 years. Two were perimenopausal and seven were postmenopausal. All patients presented with a mass in the breast. Three tumours are larger than 5 cm. All tumours were not fixed to chest wall. Five tumours were located on the right breast and four tumours on the left breast. The tumour size between 4 and 10 cms and one patient had axillary lymphnode metastasis.

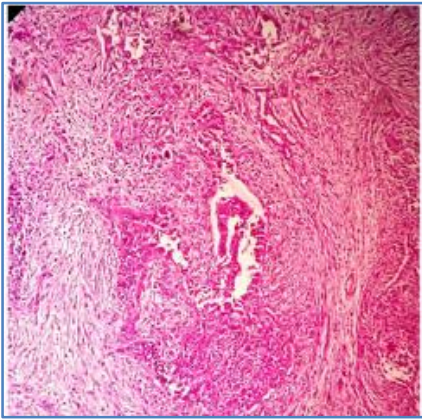


Fig. 1: Carcinosarcoma of the breast (Tumor with mixed epithelial and sarcomatoid components)

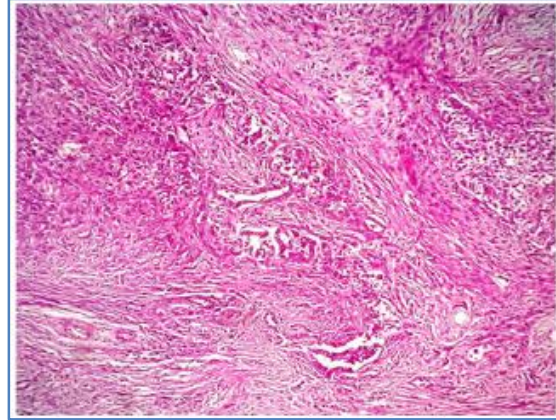


Fig. 2: Monophasic sarcomatoid metaplastic breast carcinoma with tumor cells showing pleomorphic nuclei and brisk mitotic activity

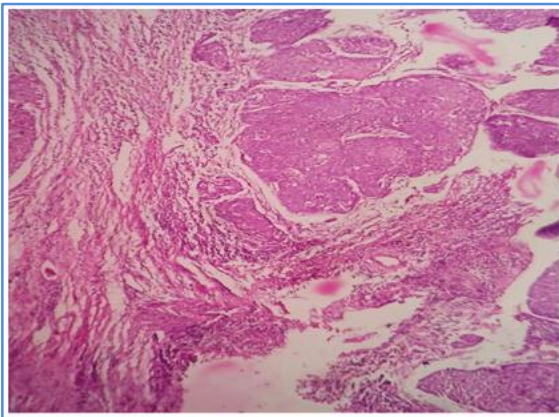


Fig. 3: Squamous Component of metaplastic Carcinoma

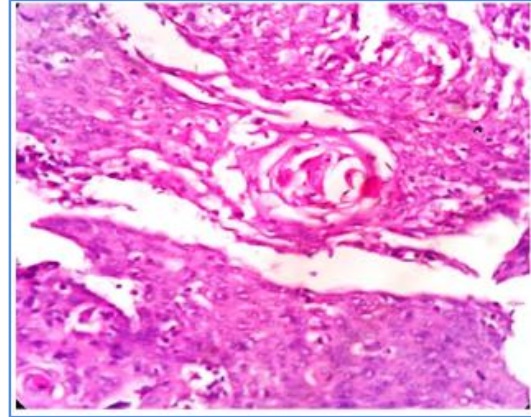


Fig. 4: High power view showing keratin Pearl

ORIGINAL ARTICLE

DISCUSSION: Metaplastic carcinoma is a rare malignancy of the breast, characterized by its high grade nature. Most Metaplastic carcinomas are sporadic, but slight propensity for Metaplastic spindle cell carcinomas to arise from pre-existing lesions, including Papillomas, Complex sclerosing lesions and nipple adenomas.^(2,3) Metaplastic or spindle cell carcinoma arising from such lesions can show a varying degree of malignancy, ranging from low to high grade. This type of lesion should also be differentiated from the so called reactive spindle cell tumour which is believed to be benign and may also complicate pre-existing lesions such as Papillomas or Complex sclerosing lesions.⁽⁴⁾

Carcinosarcoma is a subgroup of Metaplastic carcinoma. Carcinosarcoma describes a malignant tumour that is a mixture of carcinoma and sarcoma. Breast Carcinosarcomas may themselves present in a variety of mixtures such as homogenously adenosquamous or heterogeneously Epithelial (adenocarcinoma) and mesenchymal (matrix, spindle cell and sarcomatous)

The prognosis of patients with Metaplastic breast carcinoma depends on the stage of disease similar to that seen in Invasive carcinoma of breast.⁽⁵⁾ Tumour size is another prognostic factor. Patient with a tumour not larger than 5 cm had a better survival rate. The incidence of Axillary lymphnode metastasis is low in Metaplastic carcinoma.^(6,7,8,9)

These finding suggest that, unlike Invasive carcinoma of breast. Axillary nodal metastasis in the patients with Metaplastic carcinoma do not correlate with prognosis. Axillary lymphnodal metastasis is one of the prognostic factors of Metaplastic carcinoma of the breast.

SUMMARY: Metaplastic carcinomas should be included in the differential diagnosis of breast cancers. The prognosis of the patients with Metaplastic breast carcinoma may be quite good. The patients with longer duration of symptoms, advanced TNM stage, larger tumour size and axillary nodal metastases have less favourable prognosis. Although the type of surgical treatment and the role of chemotherapy and radiation therapy in the treatment of Metaplastic carcinomas need further studies, following the guidelines for treatment of Invasive carcinoma is justifiable.

REFERENCES:

1. GM Tse, PHTo, TC Putti, PCW Leri, B. Chaiwon, BKB Law; Metaplastic carcinoma of breast: A clinicopathological review J Clinicopatholol. Oct 2006; 59 (10): 1079-1083.
2. Gobbit, simpson JF, Jensen RA, etal Metaplastic Spindle cell breast tumours arising with in papillomas, complex sclerosing lesions and nipple adenomas. Modpathol 2003, 16873-901. 901(Pubmed).
3. Denley II, Pinder SE. Tan PLI, ctal Metaplastic carcinoma of the breast arising within complex sclerosing lesion: a report of five cases, I listopathology 2000. 36203-209.209(Pubmed).
4. Gobbi H, Tse G, page DI., etal Reactive sindle cell nodules of the breast after core biopsy and fine needle aspiration. AM J clin pathol 2000. 113288-294.294(Pubmed).
5. Clark GM: Prognostic and predictive factors, In Harris JR, Lippman ME, Morrow M Hellman S: "Diseases of the breast" Philadelphia: Lippincott Raven publishers, 1996; 461-485.

ORIGINAL ARTICLE

6. Oberman HA: Metaplastic carcinoma of breast. A clinicopathologic study of 29 patients. Am J surg Pathol 1987; 11:918-929.
7. Kautman MW: Marti JR, Gallanagar Hs et al: Carcinoma of the breast with pseudosarcomatous Metaplasia, cancer 53; 1984; 1908-1917.
8. PiHs WC, Rojas VA, Gaffey MJ, et al,: carcinoma with Metaplasia and sacromas of the breast; Am J T clin pathol 1991; 95:623-632.
9. Patterson Sk. Twore K JA, Roubidox MA, etal: Metaplastic carcinoma of the breast: Mammographic appearance with pathological correlation. AJR 1997; 169: 709-71.

AUTHORS:

1. Vijasree Mandava
2. Rajani Mutyala

PARTICULARS OF CONTRIBUTORS:

1. Professor, Department of Pathology, Guntur Medical College.
2. Associate Professor, Department of Pathology, Guntur Medical College.

NAME ADDRESS EMAIL ID OF THE CORRESPONDING AUTHOR:

Dr. Rajani Mutyala,
C/o. Meher Hospital,
26-20-5, Swamy Street,
Gandhinagar, Vijayawada, Andhra Pradesh.
E-mail: drrajanim70@gmail.com

Date of Submission: 25/09/2015.
Date of Peer Review: 26/09/2015.
Date of Acceptance: 29/09/2015.
Date of Publishing: 09/10/2015.