

CASE REPORT

SETON - AS A GOLD STANDARD TREATMENT FOR HIGH FISTULA IN ANO

A. Kishore Babu¹, M. Bhaghavan Naik², M. Rohit Babu³, M. Madhulikia⁴

HOW TO CITE THIS ARTICLE:

A. Kishore Babu, M. Bhaghavan Naik, M. Rohit Babu, M. Madhulikia. "Seton-as a gold standard treatment for high fistula in Ano". Journal of Evidence based Medicine and Healthcare; Volume 2, Issue 11, March 16, 2015; Page: 1687-1693.

ABSTRACT: Objective to determine the effectiveness of seton tie as treatment modality in a high anal fistula in contrary to diversion colostomy which also can be used for treating a high anal fistula.

KEYWORDS: Fistula in ano, Seton.

INTRODUCTION: HISTORY: Hippocrates, in about 430 BCE, made reference to surgical therapy for fistulous disease and he was the first person to advocate the use of a seton (from the Latin seta, a bristle).^[1] In 1376, the English surgeon John Arderne (1307-1390) wrote Treatises of Fistula in Ano; Haemorrhoids, which described fistulotomy and seton use. This is the Kshar-Sutra method mentioned by Sushruta in ancient Indian surgical practice. Many drugs have been advised by Sushruta and other Ayurvedic texts for the preparation of Kshara sutra (the medicated thread).

BACKGROUND: Fistula-in-ano is one of the commonly encountered surgical problems with prevalence of 1.2 to 2.8/10,000.^[2] Due to the lack of a single appropriate technique for the treatment of fistula-in-ano, treatment must be navigated by the surgeon's experience and judgment. The surgeon has to keep in mind the tradeoff between the extent of sphincter division, postoperative healing rate, and functional loss. Seton has been used to manage anal fistula from hundreds of years; however, in the literature, setons were commonly used only for high or complex anal fistula in order to avoid fecal incontinence and recurrence.

METHODS: This is a prospective study of 15 patients with high anal fistula who attend our OPD for whom seton treatment was done and followed over a period of 1-2 years (period of study 2008-2014).

TECHNIQUE: In the operation room, the patients were evaluated in the lithotomy position. A rigid sigmoidoscopy and proctoscopy were done prior to any intervention. Methylene blue in a 3 mL syringe was used to stain the entire tract by injecting into the external opening using the hub of a 21G needle. The external opening was gently probed using a standard 3 mm blunt-tipped copper probe with an eye till the previously identified internal opening. Copper probe is used because it is highly malleable. After passing the copper probe the infrasphincteric part of fistulous tract is excised as done in low anal fistula. Then a seton (1-0 silk impregnated with Hydrogen peroxide and Povidone iodine) is tied to the eye of the copper probe and the probe is brought out through the anal canal, during the manoeuvre the seton is also dragged along the

CASE REPORT

course of the fistulous tract. Now the seton which was brought from external opening to outside through anal canal from internal opening, thus traversing the whole path of fistulous tract, is tied over a guaze pledget.

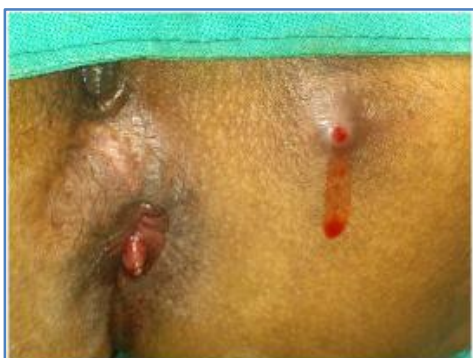

Fig. 1

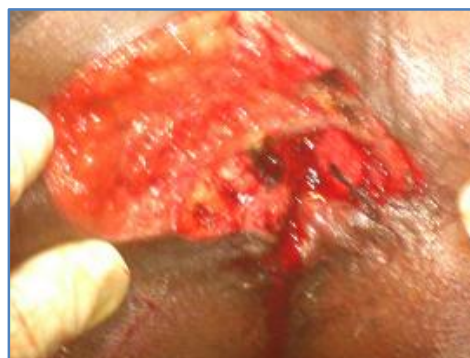

Fig. 2

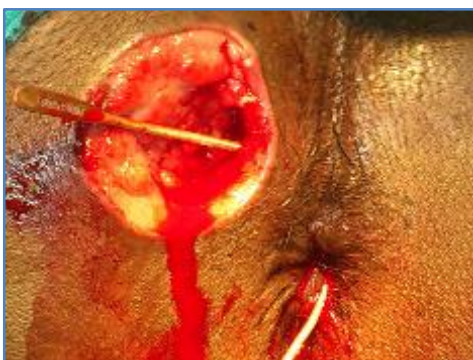

Fig. 3

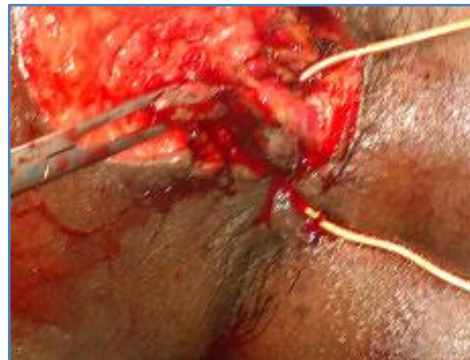

Fig. 4

Intra op photos demonstrating various steps 1. Clinical photo showing external opening of the fistula 2. Infra sphincteric part excision 3. Guiding the probe 4. Passing the seton through the fistulous tract.

Dry gauze dressing was used to cover the wound and retained in place using a sanitary napkin. Diclofenac was used as an analgesic. Care at home consisted of hot soaks (Sitz bath), oral antibiotics (quinolones, metronidazole) and dry gauze cover retained by fitting undergarments.

Patients were seen in the clinic after 72 hours to reinforce postoperative instructions and to evaluate wound. The patients were seen every other week and the fresh seton was changed once in a week using railroad technique and tied over a guaze pledget under LA, tightened further. In this manner the seton cuts and fibrose the fistulous tract starting from the internal opening down to the infrasphincteric part of the tract resulting in obliteration of the tract in a staged manner over a period of 6-8 weeks depending upon the level of internal opening above the sphincter complex. On each visit, patients were asked about the fecal incontinence according to Wexner's score.

CASE REPORT

Wexner's score for fecal incontinence:

Characteristic	Never	Rarely <1/month	Sometimes >1/month <1/week	Usually >1/week <7/day	Always ≥1/day
Flatus	0	1	2	3	4
Liquid stool	0	1	2	3	4
Solid stool	0	1	2	3	4
Wears pad	0	1	2	3	4
Alteration in lifestyle	0	1	2	3	4

Range (0–20); 0 = normal continence and 20 = maximum incontinence with maximum disturbance of life style.

RESULTS: This technique was performed on 15 patients of high fistula-in-ano with Multi staged seton between March 2008 and March 2014 were followed for 1- 2yrs for any recurrence out of them 2 patients developed slippage of setons for whom seton was placed again. None of the patients developed recurrence showing 100% effective in high anal fistula.

Fig. 5: Healed fistulous tract.

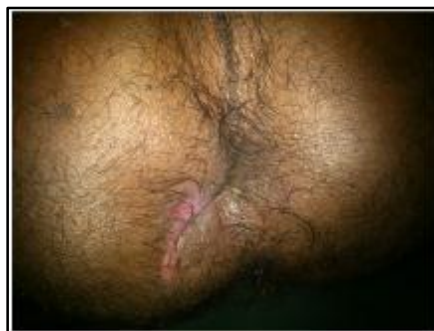

Fig. 5

DISCUSSION:

ETIOLOGY: The vast majority of fistulas-in-ano are nearly always caused by a previous anorectal abscess. Multiple series have shown that the formation of a fistula tract following anorectal abscess occurs in 7-40% of cases.^[3,4]

Other fistulas develop secondary to trauma (eg, rectal foreign bodies), Crohn disease, anal fissures, carcinoma, radiation therapy, actinomycoses, tuberculosis, and lymphogranuloma venereum secondary to chlamydial infection. In these cases the primary cause should be treated.

GOODSALL RULE: The rule states that fistulas with an external opening anterior to a plane passing transversely through the center of the anus will follow a straight radial course to the dentate line. Fistulas with their openings posterior to this line will follow a curved course to the posterior midline (see image below). Exceptions to this rule are external openings more than 3cm from the anal verge. These almost always originate as a primary or secondary tract from the

CASE REPORT

posterior midline, consistent with a previous horseshoe abscess.^[5,6] This rule doesn't help in assessment of the level of fistula based on the location of external opening.

Fig. 6: Goodsall rule.

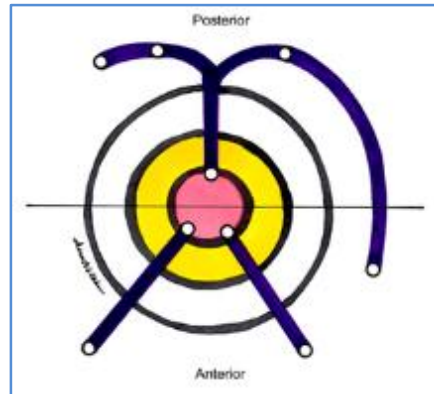


Fig. 6

PARKS CLASSIFICATION: The Parks, Gordon, and Hardcastle (known as the Parks Classification) is the most common classification used for fistulas-in-ano. This classification system, demonstrated in the image below, defines 4 types of fistula-in-ano that result from cryptoglandular infections: intersphincteric, transsphincteric, suprasphincteric, and extrasphincteric.^[7]

Fig. 7: Parks classification system.

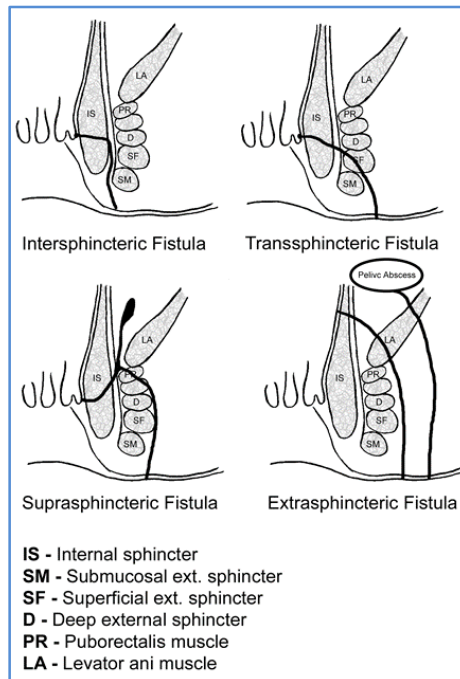


Fig. 7

CASE REPORT

PHYSICAL EXAMINATION: No specific laboratory studies are required in the diagnosis of fistula-in-ano (although the normal preoperative studies are performed, based on age and comorbidities). Instead, physical examination findings remain the mainstay of diagnosis. The examiner should observe the entire perineum, looking for an external opening that appears as an open sinus or elevation of granulation tissue. Spontaneous discharge of pus or blood via the external opening may be apparent or expressible on digital rectal examination.

Digital rectal examination may reveal a fibrous tract or cord beneath the skin. It also helps to delineate any further acute inflammation that is not yet drained. Lateral or posterior induration suggests deep postanal or ischioanal extension.

The examiner should determine the relationship between the anorectal ring and the position of the tract before the patient is relaxed by anesthesia. The sphincter tone and voluntary squeeze pressures should be assessed before any surgical intervention, to delineate whether preoperative manometry is indicated. Anoscopy is usually required to identify the internal opening. Proctoscopy is also indicated in the presence of rectal disease, such as Crohn disease or other associated conditions. Most patients cannot tolerate even gentle probing of the fistula tract in the office and this should be avoided.

IMAGING STUDIES: Radiologic studies are not performed for routine fistula evaluation. However, they can be helpful when the primary opening is difficult to identify or for recurrent or high anal fistula or complex fistulas. The efficacy of each modality is reviewed.

FISTULOGRAPHY: This technique involves injection of contrast via the external opening, which is followed by anteroposterior, lateral radiographic images to outline the course of the fistula tract. Its accuracy rate has been questioned and it ranges from 16-48%.^[8]

ENDOANAL/ENDORECTAL ULTRASONOGRAPHY: These studies involve passage of a 7- or 10MHz transducer into the anal canal to help define muscular anatomy differentiating intersphincteric from transsphincteric lesions.^[9]

MRI(MR FISTULOGRAM): Findings on magnetic resonance imaging (MRI) scans show 80-90% concordance with operative findings when a primary tract course and secondary extensions are observed. MRI is becoming the study of choice when evaluating complex fistulas and recurrent fistulas. It has been shown to reduce recurrence rates by providing information on otherwise unknown extensions.^[10,11]

BARIUM ENEMA/SMALL BOWEL SERIES: These studies may be useful for patients with multiple fistulas or recurrent disease to help rule out inflammatory bowel disease.

Various treatment modalities for fistula in ano are:

1. Fistulotomy.
2. Fistulectomy.

CASE REPORT

3. Seton Placement.
 - a) Single-stage seton (cutting).
 - b) Multi-stage seton (draining/fibrosing).
4. Mucosal Advancement Flap.
5. Plugs and Adhesives.
6. LIFT Procedure.
7. Diversion colostomy.

CONCLUSION: Seton tie is treatment of choice for high anal fistula with least recurrence rate compared to other treatment modalities and can be considered as the gold standard treatment in most of the high anal fistulas.

REFERENCES:

1. Hippocrates (400 B.C.E.).Wikipedia.
2. C. Zanotti, C. Martinez-Puente, I. Pascual, M. Pascual, D. Herreros, and D. García-Olmo, "An assessment of the incidence of fistula-in-ano in four countries of the European Union," *International Journal of Colorectal Disease*, vol. 22, no. 12, pp. 1459–1462, 2007.
3. Hancock BD. ABC of colorectal diseases. Anal fissures and fistulas. *BMJ*. Apr 4 1992; 304(6831):904-7.
4. Hamalainen KP, Sainio AP. Incidence of fistulas after drainage of acute anorectal abscesses. *Dis Colon Rectum*. Nov 1998; 41(11): 1357-61; discussion 1361-2.
5. Rosen L. Anorectal abscess-fistulae. *Surg Clin North Am*. Dec 1994; 74(6): 1293-308.
6. Ross ST. Fistula in ano. *Surg Clin North Am*. Dec 1988; 68(6): 1417-26.
7. Parks AG, Gordon PH, Hardcastle JD. A classification of fistula-in-ano. *Br J Surg*. Jan 1976; 63(1): 1-12.
8. Weisman RI, Orsay CP, Pearl RK, Abcarian H. The role of fistulography in fistula-in-ano. Report of five cases. *Dis Colon Rectum*. Feb 1991; 34(2): 181-4.
9. Nevler A, Beer-Gabel M, Lebedyev A, Soffer A, Carter D, Zbar AP. Transperineal Ultrasonography (Tp-Us) In Perianal Crohn's Disease And Recurrent Cryptogenic Fistula-In-Ano. *Colorectal Dis*. Mar 12 2013;
10. Beckingham IJ, Spencer JA, Ward J, Dyke GW, Adams C, Ambrose NS. Prospective evaluation of dynamic contrast enhanced magnetic resonance imaging in the evaluation of fistula in ano. *Br J Surg*. Oct 1996; 83(10): 1396-8.
11. Buchanan GN, Halligan S, Williams AB, Cohen CR, Tarroni D, Phillips RK, et al. Magnetic resonance imaging for primary fistula in ano. *Br J Surg*. Jul 2003; 90(7): 877-81.

CASE REPORT

AUTHORS:

1. A. Kishore Babu
2. M. Bhaghavan Naik
3. M. Rohit Babu
4. M. Madhulikia

PARTICULARS OF CONTRIBUTORS:

1. Assistant Professor, Department of General Surgery, Andhra Medical College.
2. Associate Professor, Department of General Surgery, Andhra Medical College.
3. Post Graduate, Department of General Surgery, Andhra Medical College.
4. Post Graduate, Department of General Surgery, Andhra Medical College.

NAME ADDRESS EMAIL ID OF THE CORRESPONDING AUTHOR:

Dr. A. Kishore Babu,
Assistant Professor,
Department of General Surgery,
Andhra Medical College,
Visakhapatnam-500002.
E-mail: drkishorebabu31surgeon@gmail.com

Date of Submission: 07/03/2015.
Date of Peer Review: 08/03/2015.
Date of Acceptance: 12/03/2015.
Date of Publishing: 16/03/2015.