

**ROLE OF USG AND CT SCAN IN EVALUATION OF FEMALE PELVIC PATHOLOGY**

Drashty Rameshbhai Chauhan<sup>1</sup>, Jigna Thakorbbhai Pate<sup>2</sup>, Rupal Bhimabhai Vadhiya<sup>3</sup>, Bhavya Jayeshbhai Chauhan<sup>4</sup>

<sup>1</sup>Assistant Professor, Department of Radiology, Gujarat Cancer and Research Institute, Gujarat, India.

<sup>2</sup>Resident, Department of Radiology, Gujarat Cancer and Research Institute, Gujarat, India.

<sup>3</sup>Resident, Department of Radiology, Gujarat Cancer and Research Institute, Gujarat, India.

<sup>4</sup>Resident, Department of Radiology, Gujarat Cancer and Research Institute, Gujarat, India.

**ABSTRACT****BACKGROUND**

Ultrasound is the imaging modality of choice for the female pelvis. It can determine the organ or site of abnormality and provide a diagnosis or short differential diagnosis. Doppler sonography helps to assess normal and pathologic blood flow. Present study was done at our tertiary care center to study the role of USG and computed tomography (CT) scan in evaluation of female pelvic pathology and to assess the merits and demerits of USG and computed tomography (CT) scan over each other in characterizing pelvic pathology.

**METHODS**

100 patients were selected for study. All patients with female pelvic pathology were included in my study. Computed tomography (CT) and USG characteristics of different lesions were noted and recorded.

**RESULTS**

Most common age of presentation of endometrial pathology was between 50 to 70 years, cervical pathology between 40 to 49 years and ovarian pathology between 50 to 59 years. Out of 100 patients, 45 patients were having cervical cancer. 30 patients were having ovarian cancer and 18 patients were having endometrial cancer. 2 cases of fibroid, 2 cases of GTN and 3 cases of simple cyst were also noted.

**CONCLUSIONS**

Ultrasonography is usually the first imaging modality in evaluation of female patients suspected to have pelvic pathology. Computed tomography is the superior diagnostic imaging modality compared to USG prior to treatment. It improved detection and characterization of tumour which contribute to better diagnostic accuracy.

**HOW TO CITE THIS ARTICLE:** Chauhan DR, Patel JT, Vadhiya RB, et al. Role of USG and CT scan in evaluation of female pelvic pathology. J. Evid. Based Med. Healthc. 2019; 6(17), 1347-1356. DOI: 10.18410/jebmh/2019/277

**BACKGROUND**

Radiologists routinely evaluate a wide range of pelvic pathology and other pelvic lesions during routine practice. These pelvic pathologies most commonly arise from the uterus, cervix, ovaries, and fallopian tubes. In addition, pelvic pathology may arise from the adjacent soft tissues, and metastases. The site of origin, imaging characteristics, and clinical history may all help to narrow the differential diagnosis.

Ultrasound is the imaging modality of choice for the female pelvis. It can determine the organ or site of abnormality and provide a diagnosis or short differential diagnosis in the vast majority of patients. Doppler sonography helps assess normal and pathologic blood flow. Doppler ultrasound can also distinguish vascular structures

from nonvascular structures, such as dilated fallopian tubes or fluid-filled bowel loops. The trans abdominal approach visualizes the entire pelvis and gives a global overview. Its main limitations involve the examination of patients unable to fill the bladder, obese patients, or patients with a retroverted uterus, in whom the fundus may be located beyond the focal zone of the transducer. The trans abdominal technique also is less effective for characterization of adnexal masses. High-resolution imaging of transvaginal ultrasound provides high diagnostic accuracy for pelvic pathology. Because of the proximity of the transducer to the uterus and adnexa, transvaginal sonography allows the use of higher-frequency transducers, producing much better resolution, which provides better image quality and anatomic detail. However, because of the higher frequencies, the field of view (FOV) is limited, which is the major disadvantage of the transvaginal technique. Large masses may fill or extend out of the FOV, making orientation difficult, and superiorly or laterally placed ovaries or masses may not be visualized. Transvaginal sonography better distinguishes adnexal masses from bowel loops and provides greater detail of the internal characteristics of a pelvic mass because of its improved resolution. Thus, transvaginal and trans abdominal techniques complement each other. Sonography also play important role in guiding the interventional procedures. It is most common form of image guided biopsy, offering

*Financial or Other, Competing Interest: None.  
Submission 05-04-2019, Peer Review 08-04-2019,  
Acceptance 25-04-2019, Published 29-04-2019.*

*Corresponding Author:*

*Dr. Drashty Chauhan,*

*C-3, Sterling City,*

*'Nakshtra', Bopal,*

*Ahmedabad- 380058,*

*Gujarat, India.*

*E-mail: drashtychauhan87@gmail.com*

*DOI: 10.18410/jebmh/2019/277*



convenience and real time dynamic observation with echogenic markers on cannulae allowing for precise placement. The American College of Radiology has provided guide-lines for when ultrasound is an appropriate imaging tool for the evaluation of the female pelvis.<sup>1</sup> Computed tomography (CT) exposes patients to ionizing radiation, which can be problematic, especially in young people and females with suspected pregnancy.<sup>2</sup>

Undoubtedly, most ovarian lesions, endometrial pathology and uterine lesions are best detected with ultrasound. Computed tomography (CT) imaging offers better diagnostic capabilities for large pelvic masses, tubo-ovarian abscesses, postoperative and postpartum complications. In some cases, Computed Tomography (CT) is employed to achieve optimal differential diagnoses to determine the clinical pathway to follow.

Hence the present study was done at our tertiary care center to study the role of USG and Computed tomography (CT) scan in evaluation of female pelvic pathology and to assess the merits and demerits of USG and Computed tomography (CT) scan over each other in characterizing pelvic pathology.

**Aims and Objectives**

- To study role of USG and Computed tomography (CT) scan in evaluation of female pelvic pathology.
- To know merits and demerits of USG and Computed tomography (CT) scan over one another in characterizing pelvic pathology.
- To study the incidence of female pelvic pathologies according of age and etiological factors.
- To guide surgeon/clinical oncologist in treatment planning & to determine prognosis.
- To evaluate residual or recurrent lesions in treated patients.

**METHODS**

**Source of Data**

Data was collected from Gujarat Cancer and Research Institute Radiology dept. where patients are referred from different parts of Gujarat and other states also.

**Study Place**

Department of radiology, Gujarat Cancer and Research Institute.

**Study Duration**

July 2015-Nov 2017.

**Study Type**

Prospective study.

**Sample Size**

100 Patients.

All patients with female pelvic pathology were included in my study. Consent was taken prior to conducting the investigations in all patients.

Except for emergency, all patients were seen by appointment. They were advised to come on empty stomach for at least four to six hours.

Relevant h/o illness & significant clinical finding of any patient were record-ed. Previous investigations were reviewed. Most of patients taken for examination without any premedication. In case of uncooperative patient, sedatives were used under supervision of anaesthetists.

Computed tomography (CT) and USG characteristics of different lesions were noted and recorded. The histopathological diagnosis was followed up and recorded.

The results of this study were analysed and compared with other available studies in literature.

**Inclusion Criteria**

All patients diagnosed and suspicious of female pelvic pathology.

Patients who have already received some treatment in the form of surgical or chemotherapy or radiotherapy.

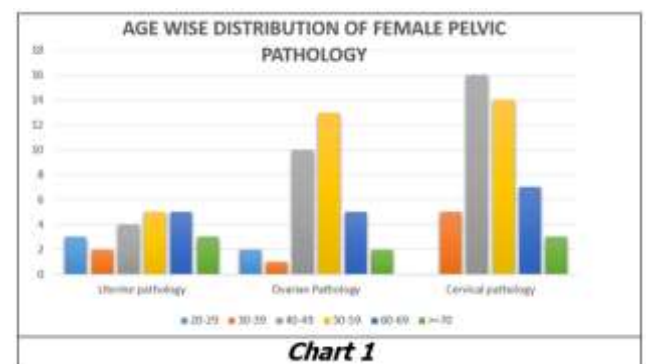
**Exclusion Criteria**

All patients with contrast allergy and contraindications to CT scan procedure were excluded from the study.

**RESULTS**

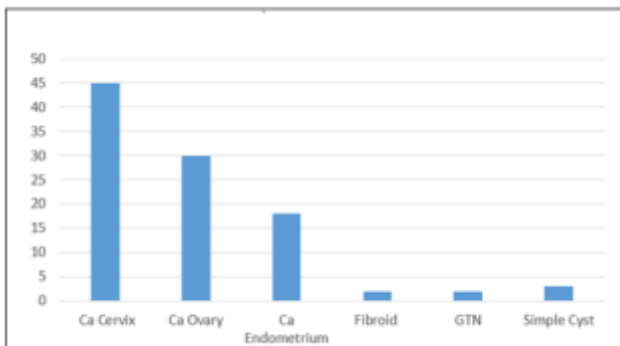
Descriptive Statistics	Endometrial Pathology	Ovarian Pathology	Cervical Pathology
Age (years)			
20-29	3	2	0
30-39	2	1	5
40-49	4	10	16
50-59	5	13	14
60-69	5	5	7
>=70	3	2	3
Total=100	22	33	45

**Table 1. Age Wise Distribution of Female Pelvic Pathology**

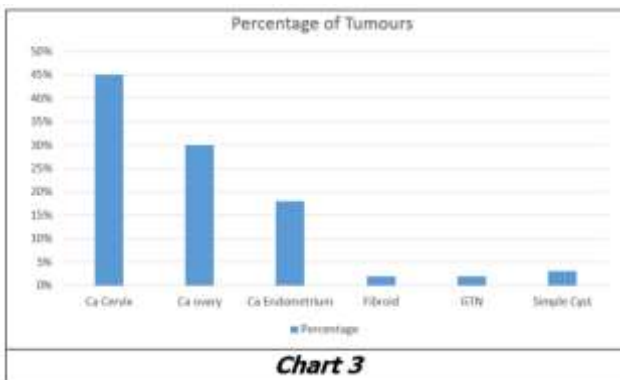


Diagnosis	Frequency	Percentage	
Ca Cervix	45	45	%
Ca Ovary	30	30	%
Ca Endometrium	18	18	%
Fibroid	2	2	%
GTN	2	2	%
Simple Cyst	3	3	%
Total	100	100	%

**Table 2. Distribution According to Diagnostic Findings**



**Chart 2**



**Chart 3**

	Ultrasound		CT	
	Number	Percent	Number	Percent
Benign	10	9.00%	8	8%
Malignant	89	89%	91	91%
Suspiciously Malignant	01	1.00%	01	1.00%

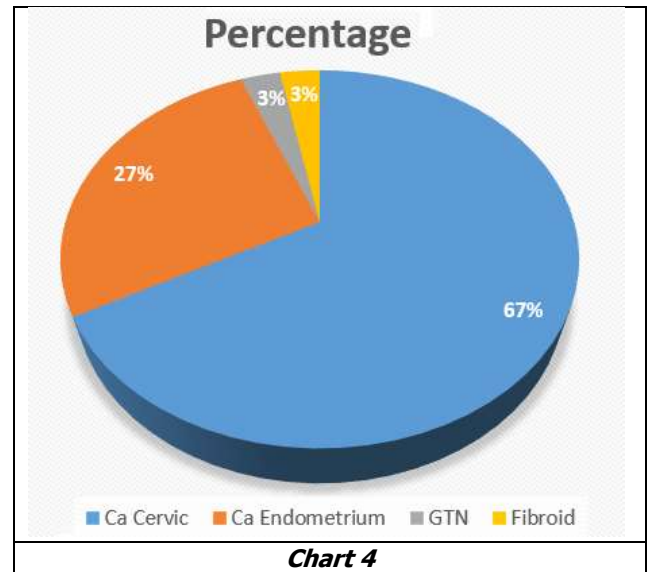
**Table 3. Comparison of Ultrasound and CT Results for Detection of Lesion**

Diagnosis by CT	Diagnosis by USG					
	Ca Cervix	Ca Endo-metrium	Ca Ovary	Fibroid	GTN	Simple Cyst
Ca cervix	45	0	0	0	0	0
Ca endo-metrium	1	16	0	0	0	0
Ca ovary	0	0	30	0	0	0
Fibroids	0	0	0	2	0	0
GTN	0	0	0	0	2	0
Simple Cyst	0	0	0	0	0	3
Chi-Square	342.4	P value	0			Significant

**Table 4. Association of Masses According to Diagnosis**

Uterine Pathology	Frequency	Percentage (%)
Ca cervix	45	67.13
Ca endometrium	18	26.87
GTN	2	3
Fibroids	2	3
Total	67	100

**Table 5. Distribution of Uterine Pathology**



**Chart 4**

Echogenicity	Frequency	Column N%
Hyperechoic	15	83.33
Hypoechoic	2	11.11
Thickening	1	5.55
Total	18	100.00
Myometrial Invasion	Frequency	Column N%
Less than < 50%	5	27.78
More than > 50%	13	72.22
Total	18	100.00
Serosal Invasion	Frequency	Column N%
Absent	16	88.89
Present	2	11.11
Total	18	100.00
Lymphadenopathy	Frequency	Column N%
Present	4	22.22
Absent	14	77.78
Total	18	100.00
Peritoneal Implants	Frequency	Column N%
Present	0	0.00
Absent	18	100.00
Total	18	100.00

**Table 6. USG Findings in Endometrial Cancer**

Myometrial Invasion	Frequency	Column N%
Less than < 50%	5	0.40
More than > 50%	13	0.60
Total	18	1.00
Serosal Invasion	Frequency	Column N%
Absent	16	88.89
Present	2	11.11
Total	18	100.00
Lymphadenopathy	Frequency	Column N%
Present	7	38.89
Absent	11	61.11
Total	18	100.00
Peritoneal Implants	Frequency	Column N%
Present	0	0.00
Absent	18	100.00
Total	18	100.00

**Table 7. CT Findings in Endometrial Cancer**

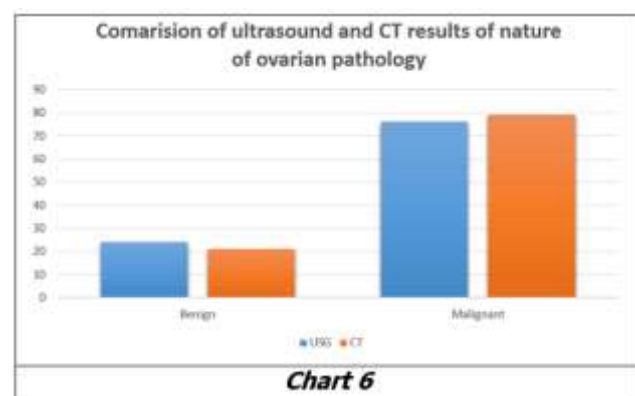
Nature of Pathology	Frequency	Column N%
Benign	8	24
Malignant	25	76
Total	33	100
Type of Lesion	Frequency	Column N%
Solid	4	12.12
Cystic	6	18.18
Solid-Cystic	23	69.70
Total	33	100
USG Finding	Present	Absent
Vascularity	17 (51%)	16 (49%)
Ascites / Free fluid	12 (36%)	21 (64%)
Calcification / Fat	2 (6%)	31 (94%)
Internal Septa / Mural Nodule	20 (60%)	13 (40%)
Bowel / Mesentery Involvement	1 (3%)	32 (97%)
Omentum Involvement	4 (12.12%)	29 (87.88%)
Peritoneal Implants	6 (18.18%)	27 (81.82%)
Lymphadenopathy	Frequency	Column N%
Present	6	18
Absent	27	82
Total	33	100

**Table 8. USG Findings in Adnexal Pathology**

Nature of Pathology	Frequency	Column N%
Benign	7	21.21
Malignant	26	78.79
Total	33	100
Type of Lesion	Frequency	Column N%
Solid	4	12.12
Cystic	6	18.18
Solid-Cystic	23	69.70
Total	33	100

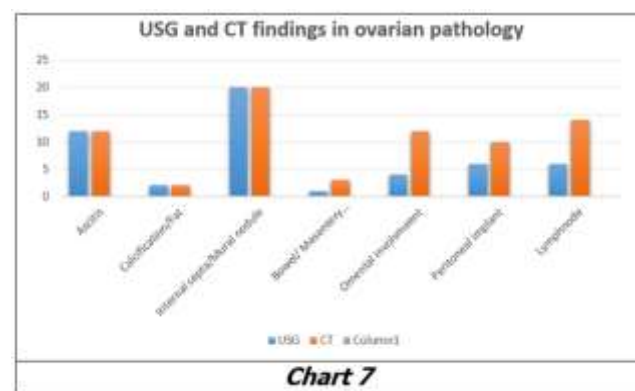
CT finding	Present	Absent
Ascites / Free fluid	12 (36%)	21 (64%)
Calcification / Fat	2 (6%)	31 (94%)
Internal Septa / Mural Nodule	20 (60%)	13 (40%)
Bowel / Mesentery Involvement	3 (9%)	30 (91%)
Omentum Involvement	12 (36.36%)	21 (63.64%)
Peritoneal Implants	10 (30%)	23 (70%)
Lymphadenopathy	Frequency	Column N%
Present	14	42
Absent	19	58
Total	33	100

**Table 9. CT Findings in Ovarian Pathology**



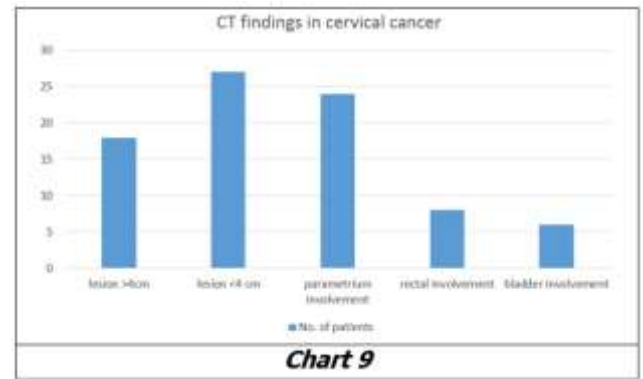
	Ultrasound		CT	
	Number	Percentage	Number	Percentage
Bowel/Mesentery Involvement	1	(3%)	3	(9%)
Omentum Involvement	4	(12.12%)	12	(36.36%)
Peritoneal Implant	6	(18.18%)	10	(30%)

**Table 10. Comparison of Ultrasound and CT Results of Omentum, Bowel/Mesentery and Peritoneal Implant Involvement by Ovarian Cancer**

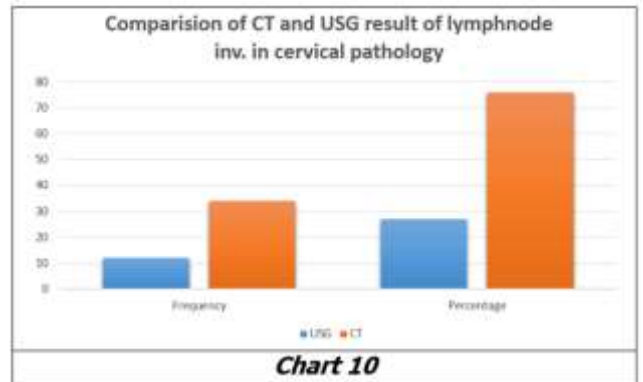


Size of Lesion	Frequency	Column N%
Less than 4 cm	18	40.00
More than 4 cm	27	60.00
Total	45	100.00
Lymphadenopathy	Frequency	Column N%
Present	12	27
Absent	33	73
Total	45	100
USG Finding	Involved	Uninvolved
Parametrium	24 (53.33%)	21 (46.67%)
Urinary bladder	6 (13.33%)	39 (86.67%)
Rectum	4 (8.90%)	41 (91.10%)

**Table 11. USG Findings in Cervical Cancer**



Size of lesion	Frequency	Column N %
Less than 4 cm	18	40.00
More than 4 cm	27	60.00
Total	45	100.00
Lymphadenopathy	Frequency	Column N %
Present	34	76
Absent	11	24
Total	45	100
CT finding	Involved	Uninvolved
Parametrium	24 (53.33 %)	21 (46.67 %)
Urinary bladder	6 (13.33 %)	39 (86.67 %)
Rectum	8 (17.78 %)	37 (82.20 %)

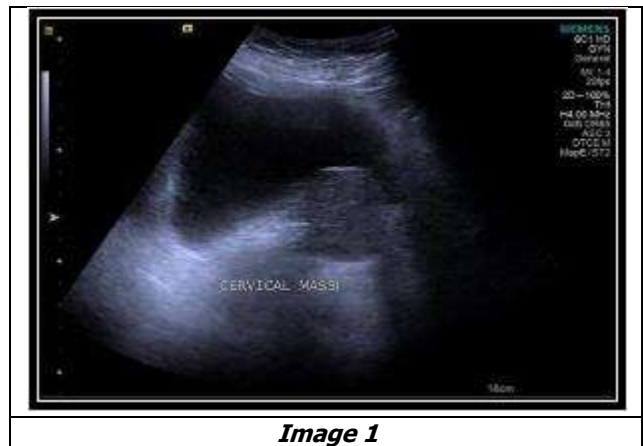


**Table 12. CT Findings in Cervical Cancer**

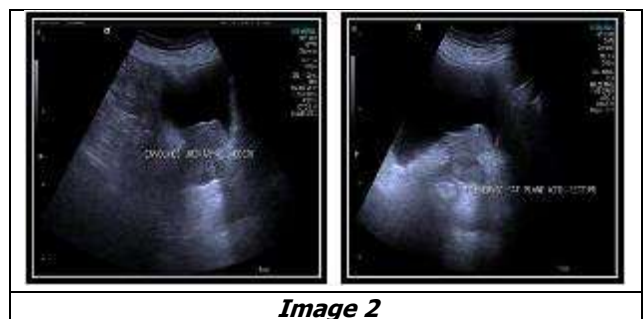
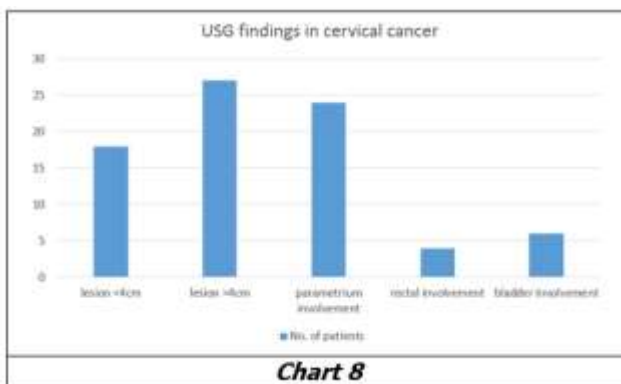
**Cervical Cancer**

	Ultrasound		CT	
	Number	Percentage	Number	Percentage
Rectum wall involvement	4	8.90	8	17.78
Lymphadenopathy	12	27	34	76

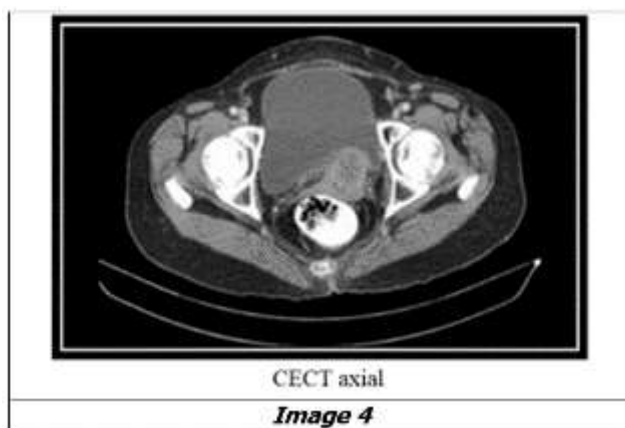
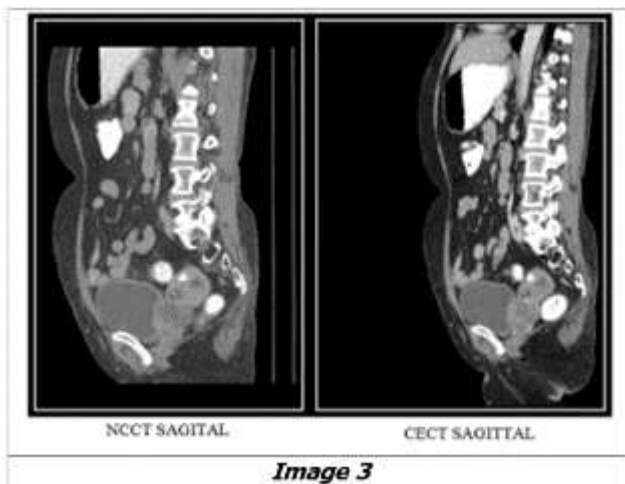
**Table 13. Comparison of Ultrasound and CT Results of Rectal Wall and Lymph Node Involvement by Cervical Pathology**



On USG, heterogeneously enhancing cervical mass with bilateral parametrium involvement.

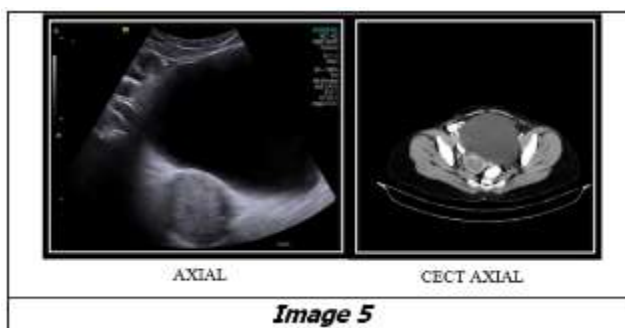


Cervical mass shows preserved fat plane with rectum and involves posterior wall of urinary bladder on USG.

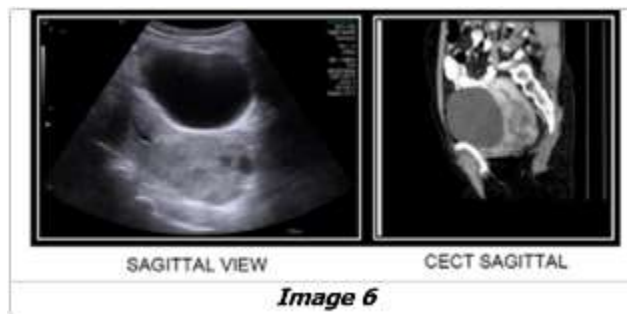


CECT shows heterogeneously enhancing cervical mass with preserved fat plane with rectum and involves posterior wall of urinary bladder with calcified fibroid in anterior wall of uterus. Lesion appears heterogeneous and shows non enhancing necrotic area.

**Cervical Cancer**

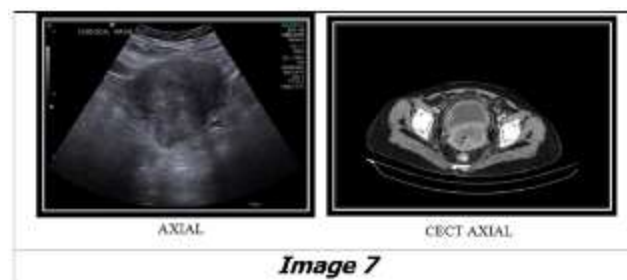


USG and CT axial images shows cervical mass with B/L parametrium involvement.

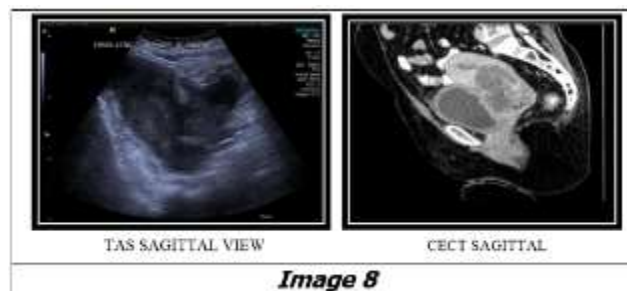

USG and CT sagittal images show cervical mass and preserved fat plane with urinary bladder and rectum with thin strip of endometrial collection.

**Cervical Cancer**

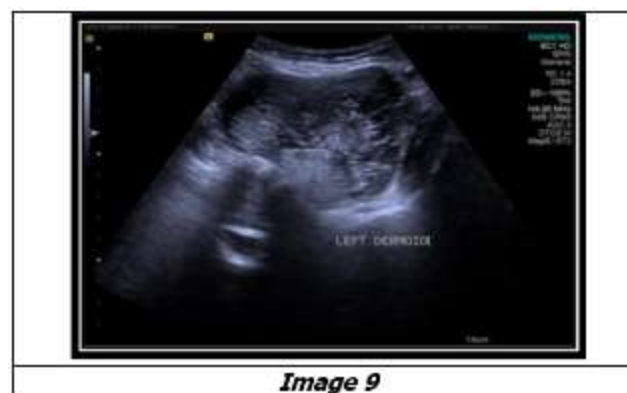

On USG AND CT AXIAL images, heterogeneously enhancing cervical mass with bilateral parametrium involvement.

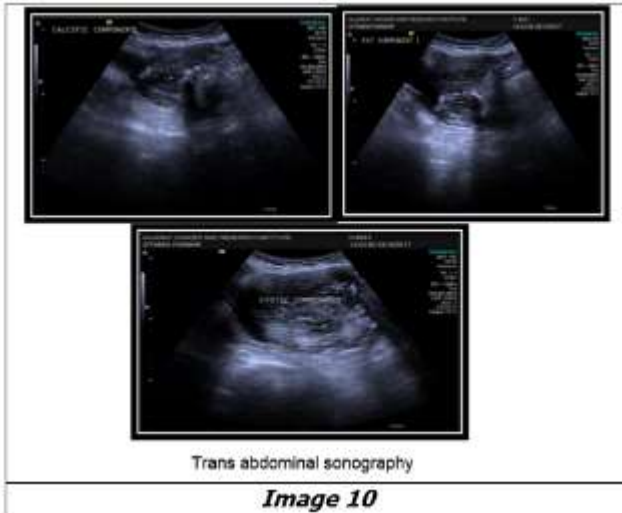

USG and CT sagittal images show cervical mass involving lower body uterus, upper part of vagina, posterior wall of urinary bladder and preserved fat plane with and rectum.

**Dermoid**

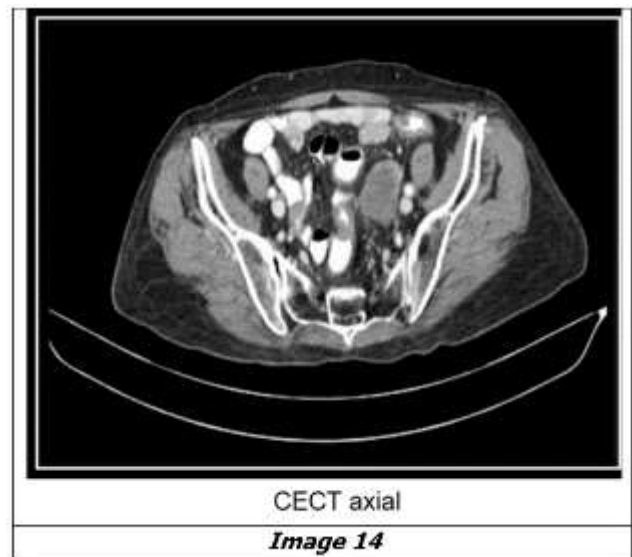
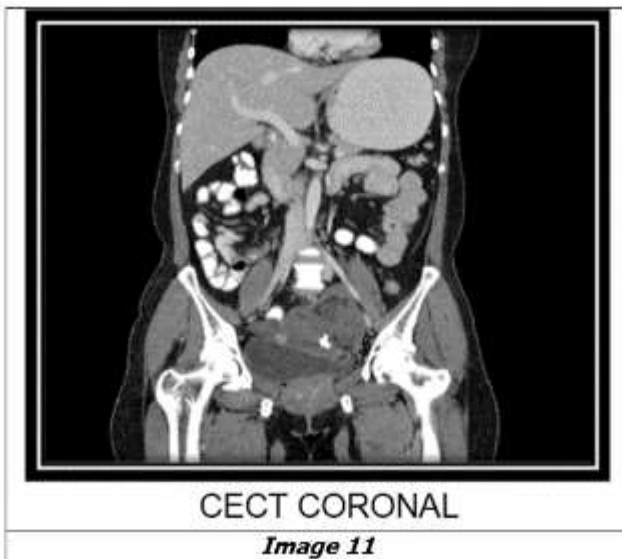
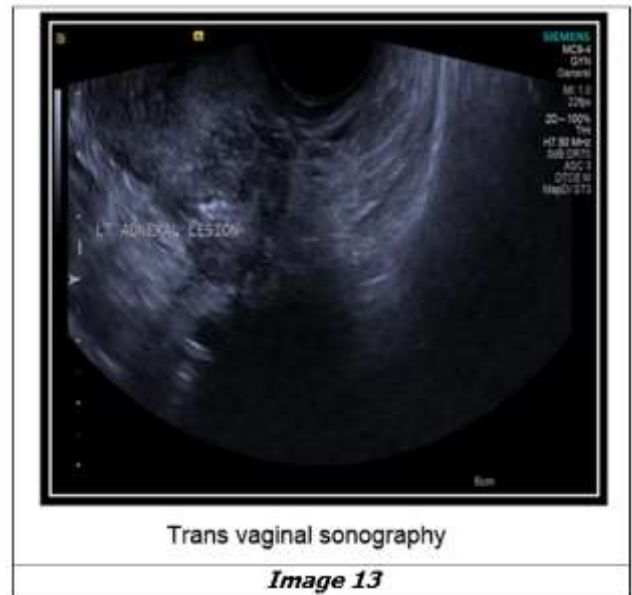

**Trans Abdominal Sonography**

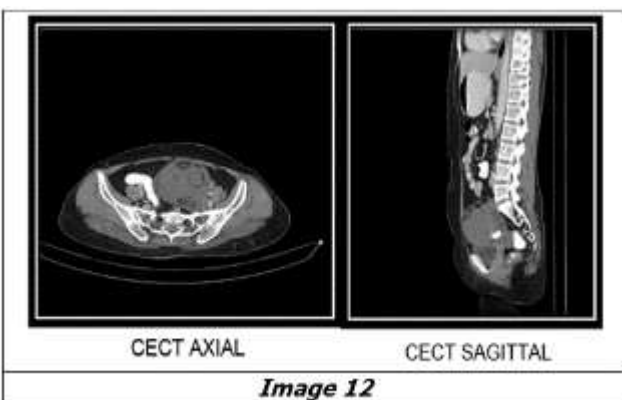


Trans abdominal axial ultrasound demonstrate dermoid with echogenic component with area of sound enhancement in left adnexal region.

**CA Ovary Serous Papillary Adeno Carcinoma**



Trans vaginal sonography & CECT axial images shows solid lesion in left adnexal region.



CECT scan shows in coronal, axial and sagittal view post hysterectomy status and cystic tumour in left adnexal region with fat and calcification.

**DISCUSSION**

The present study included 100 cases of pelvic masses in females which were carried out at Gujarat Cancer and research institute, Ahmedabad following observation made according to age, site, nature, USG and CT appearance of masses and study data were analysed.

Most common age of presentation of endometrial pathology between 50 to 70 years.

Most common age of presentation of cervical pathology between 40 to 49 years followed by 50-59 years.

Our findings correlate with Liu Y et al<sup>3</sup> and Firoozabadi et al<sup>4</sup> study which showed youngest 18 years and most elderly 77 yr. Majority of patients included were above 40 years in Liu Y et al<sup>3</sup> study.

Most common age of presentation of ovarian pathology between 50 to 59 year followed by 40-49 years.

My findings correlate with study by Moideen N et al<sup>5</sup> which showed most common age of presentation were 50 to 59 years with mean age  $\pm$  standard deviation was calculated which  $47.5 \pm 15.5$  years. Majority of patients included were above 40 years. Only 9 patients were in the less than 40 years group.

Out of 100 patients 45 patients were having cervical cancer. 30 patients were having ovarian cancer and 18 patients having endometrial cancer. 2 cases of fibroid, 2 cases of GTN and 3 cases of simple cyst were also noted. So, 45% patients were having cervical cancer, 30% patients were having ovarian cancer, 18% patients having endometrial cancer, 2% were having fibroid, 2% were having GTN and 3% were having simple cyst.

Our findings correlate with Liu Y et al<sup>3</sup> study which showed uterine fibroid and ca cervix compromise vast majority followed by benign ovarian tumour, endometrial cancer, and ovarian tumour than uterine sarcoma.

In our study USG was able to detect benign lesion in 10 out of 100 patients and CT was able to detect benign lesion in 8 out of 100 patients.

In our study USG was able to detect malignant lesion in 89 out of 100 patients and CT was able to detect malignant lesion in 91 out of 100 patients.

One case was suspected to have suspiciously malignant in CT and USG.

So, in my study USG has sensitivity of 89% in detecting malignancy and CT has sensitivity of 91% in detecting malignancy.

Our findings correlate with Firoozabadi et al<sup>4</sup> study which showed 51.9% sensitivity for USG and 79.2% sensitivity for CT in detecting malignancy in female pelvic pathology.

It was shown that CT scan images were more consistent with pathological findings in predicting appropriate surgical procedures than sonographic examinations.

There were 45% diagnosed cases of Ca cervix according to both USG and CT. Ca endometrium was diagnosed by USG in 17% cases and it was rightly diagnosed by CT in 18% cases. Ca ovary was seen in 30% cases according to USG and CT both. 3% simple cyst, 2% fibroids and GTN were correctly diagnosed in USG and CT.

Out of 67 patients, most common diagnostic finding observed in uterine pathology was carcinoma cervix in 45 patients followed by Carcinoma endometrium in 18 patients, GTN in 2 patients and Fibroids in 2 cases.

In our study out of 18 patients, myometrial invasion <50% in endometrial cancer were found in 5 patients by USG and CT.

In our study out of 18 patients, myometrial invasion >50% in endometrial cancer were found in 13 patients by USG and CT.

In our study out of 18 patients serosal invasion in endometrial cancer was found in 2 patients by USG and CT.

In our study detection of myometrial and serosal invasion by endometrial cancer by USG and CT appeared to be same.

Our result correlate with Kim SH et al<sup>6</sup> study which showed sensitivity of myometrial invasion by USG and CT appeared to be same.

Out of 18 patients, in 4 patients, lymphadenopathy was found in USG, while in 7, it was found in CT scan. It was missed in 3 patients on USG; therefore, CT is better than USG for lymph node staging. Sensitivity of CT and USG for detection of lymphadenopathy were 71.4% and 42.8% respectively. CT is more sensitive for detection of lymphadenopathy. It is superior than USG for lymph node staging.

In our study USG was able to detect benign lesion in 8 out of 33 patients and CT was able to detect benign lesion in 7 out of 25 patients in ovarian pathology.

In our study USG was able to detect malignant lesion in 25 out of 33 patients and CT was able to detect malignant lesion in 24 out of 33 patients in ovarian pathology.

One malignant case missed on USG and considered as benign.

So, in my study USG has sensitivity of 89% for detecting malignancy and CT has sensitivity of 91% for detecting malignancy in ovarian pathology.

Our findings correlate with Buy JN, Ghossain MA, Scioc C et al<sup>7</sup> study which showed 86% sensitivity for USG and 87% sensitivity for CT in detecting malignancy in epithelial tumours of the ovary.

Our findings correlate with Moideen et al<sup>5</sup> study which showed 90.2% sensitivity for USG and 95.1% sensitivity for CT in detection of ovarian malignancy.

Out of 33 patients of ovarian pathology, in 1 patient there was bowel/mesentery involvement noted on USG while in CT bowel/mesentery involvement noted in 3 patients. 2 patients missed on USG.

Out of 33 patients of ovarian pathology, in 4 patients there is omentum involvement noted on USG while in CT omentum involvement noted in 12 patients. 8 patients missed on USG.

Out of 33 patients of ovarian pathology, in 6 patients there is peritoneal implants pre-sent on USG while in CT peritoneal implant present in 10 patients. 2 patients missed on USG.

Sensitivity of USG and CT for detection of omentum, bowel/mesentery and peritoneal implant were 33.33%, 34% and 60%, 100%, 100% and 100% respectively. CT is more sensitive for detection of omentum, bowel/mesentery and peritoneal implant.

Our results correlate with S. Schmidt et al<sup>8</sup> study which reported sensitivity of MDCT in diagnosis peritoneal carcinomatosis was 90.2%.

Our results correlate with Moideen N et al<sup>5</sup> study which reported Overall accuracy of CT in staging ovarian tumours was 95% compared to USG which was only 82%.

Out of 33 patients in 6 patients, lymphadenopathy was found in USG while in 14 patients, lymphadenopathy were found in CT scan. 8 patients were missed on USG.



Sensitivity of USG and CT for diagnosis of lymphadenopathy were 42.8%, and 100% respectively. CT is better than USG for lymph node staging.

Our results correlate with Moideen N et al<sup>5</sup> study which reported sensitivity for diagnosis of lymphadenopathy was 88% noted.

Out of 45 patient of carcinoma cervix, in 4 patient there is rectal wall involvement noted on USG while in in CT rectal wall involvement noted in 8 patients. 4 patients missed on USG.

Sensitivity of USG and CT for diagnosis of rectal wall involvement was 50%, and 100% respectively. CT is better than USG for lymph node staging.

Our findings correlate with study by T.V. Prasad et al<sup>9</sup> which showed 100% sensitivity in assessment of invasion of rectum by cervical cancer.

Out of 45 patients in 12 patients, lymphadenopathy was found in USG while in 34 patients, lymphadenopathy was found in CT scan. 22 patients were missed on USG therefore CT is better than USG for lymph node staging.

Sensitivity of USG and CT for detection of lymph nodes were 27 % and 76 % respectively. CT is more sensitive for detection of lymphadenopathy.

Our findings correlate with study by Yang WT et al<sup>10</sup> which showed 64.7% sensitivity in the diagnosis of lymph node metastasis by cervical cancer.

Our findings correlate with study by Mamsen et al<sup>11</sup> which showed 23% sensitivity in the diagnosis of lymph node metastasis by cervical cancer.

We conclude that ultrasonography is not reliable in the preoperative detection of lymph node metastases. Moreover, ultrasound examination presents no advantage over CT scan in detection of lymph node metastasis by cervical cancer.

### Role of PET-CT in Female Pelvic Pathologies

The edition of FDG PET to CT improves the accuracy in pre-operative staging of ovarian to 87% compared with 53% with CT alone. PET CT provides an accurate assessment of the extend of disease particularly in areas difficult to assess for metastasis by CT and MRUI such as mediastinum and supraclavicular region. The co-registered functional and anatomic information from PET CT is particularly helpful in pelvis.

To predict treatment response, to sequential FDG PET scan are required, 1) Baseline scan before treatment, 2) After initiation of chemotherapy. The change in level of tumour metabolic activity after one or two cycles of chemotherapy can then be compared with treatment response after completion of treatment course. In advance stage ovarian cancer, a significant correlation was found between the metabolic response after the 1st and 3rd cycles of chemotherapy and overall survival using FDG PET.

### Role of MRI in Female Pelvic Pathologies

MRI is very helpful in work up of female pelvis lesions, their location, origin and relationship to adjacent organ, peritoneal or extra peritoneal involvement, lymph nodes and lateral pelvic wall involvement.

The application of MRI in pelvic masses was beyond lesion detection to detect extension of mass assessment of disease staging.

Establishing correct diagnosis and accurate staging is important to plan the treatment of patient.

MRI is an excellent investigation to evaluate female pelvic masses due to its high special resolution, excellent tissue contrast and multiplanar imaging capability.

Certain key imaging feature of pathologies on MRI are helpful in the specific diagnosis or narrow down the differential diagnosis.

### CONCLUSION

Ultrasonography is usually the first imaging modality in evaluation of female patients suspected to have pelvic pathology. USG has significantly lower sensitivity than Computed Tomography (CT) in depicting intraperitoneal, omental, or mesenteric metastases, pelvic or abnormal lymphadenopathy, and in addition USG is inferior to Computed Tomography (CT) in assessing adjacent organ invasion. Computed tomography is superior diagnostic imaging modality than USG prior to treatment which improved detection and characterization of tumour due to better diagnostic accuracy and consequently reduction of invasive procedure which lead to significant reduction of mortality and morbidity from tumour.

### REFERENCES

- [1] ACR Practice Guideline for the performance of pelvic ultrasound in females. Reston, VA: American College of Radiology 2006.
- [2] Valentini AL, Gui B, Basilico R, et al Magnetic resonance imaging in women with pelvic pain from gynaecological causes: a pictorial review. *Radio Med* 2012;117(4):575-592.
- [3] Liu Y, Zhang H, Li X, et al. Combined application of ultrasound and CT increased diagnostic value in female patients with pelvic masses. *Computational and Mathematical Methods in Medicine* 2016;2016:1-5.
- [4] Firoozabadi RD, Zarchi MK, Mansurian HR, et al. Evaluation of diagnostic value of CT scan, physical examination and ultrasound based on pathological findings in patients with pelvic masses. *Asian Pac J Cancer Prev* 2011;12(7):1745-1747.
- [5] Moideen N, Hebbar SS, Rai L, et al. Comparison of CA-125, conventional ultrasound and CT imaging in diagnosis and staging of ovarian cancer correlated with surgico-pathological findings. *Int J Reprod Contracept Obstet Gynecol* 2014;3(4):924-930.
- [6] Kim SH, Kim HD, Song YS, et al. Detection of deep myometrial invasion in endometrial carcinoma: comparison of transvaginal ultrasound, CT, and MRI. *J Comput Assist Tomogr* 1995;19(5):766-772.
- [7] Buy JN, Ghossain MA, Sciò C, et al. Epithelial tumours of the ovary: CT findings and correlation with US. *Radiology* 1991;178(3):811-818.
- [8] Schmidt S, Meuli R, Prior J, et al Peritoneal carcinomatosis due to ovarian cancer: comparison

between MDCT, MRI and 18F-FDG PET/CT. European Congress of Radiology 2012.

- [9] Prasad TV, Thulkar S, Hari S, et al. Role of computed tomography (CT) scan in staging of cervical carcinoma. Indian J Med Res 2014;139(5):714-719.
- [10] Yang WT, Lam WW, Yu MY, et al. Comparison of dynamic helical CT and dynamic MR imaging in the

evaluation of pelvic lymph nodes in cervical carcinoma. AJR Am J Roentgenol 2000;175(3):759-766.

- [11] Durfee SM, Frates MC. Sonographic spectrum of the corpus luteum in early pregnancy: grayscale, color, and pulsed Doppler appearance. J Clin Ultrasound 1999;27(2):55-59.