

ROLE OF FIBROPTIC BRONCHOSCOPY IN THE DIAGNOSIS OF SPUTUM SMEAR-NEGATIVE PULMONARY TUBERCULOSIS IN TERTIARY CARE

Muthukumar Shunmugam¹, Joseph Pratheeban², Suresh Kumar³

¹Assistant Professor, Department of Thoracic Medicine, Kanyakumari Government Medical College, Kanyakumari.

²Assistant Professor, Department of Thoracic Medicine, Kanyakumari Government Medical College, Kanyakumari.

³Resident, Department of General Medicine, Kanyakumari Government Medical College, Kanyakumari.

ABSTRACT

BACKGROUND

India has the highest burden of Tuberculosis in the world. Reaching a correct diagnosis is a challenge for the physicians treating the patients who present with negative sputum smears due to lack of sputum production, low bacterial load and insufficient sample or who present with no expectoration. On the other hand, empirical antituberculosis treatment produces risk of drug resistance and economic burden to society. Aim of our study is to assess the diagnostic yield of flexible fibreoptic bronchoscopy in patients suspected to have pulmonary tuberculosis whose sputum smears were negative in our hospital.

METHODOLOGY

In this study, we enrolled 60 patients of sputum negative for AFB and suspected to have pulmonary tuberculosis by Chest Radiology and clinical examination, subjected to flexible fibreoptic video bronchoscopy and selective bronchial washings were done in all patients.

RESULTS

Bronchoscopy lavage smears were positive for M. tuberculosis in 17 patients (28.33 %), 13 patients were found to have primary lung malignancy.

CONCLUSION

Fibreoptic bronchoscopy has a rapid and reliable role in the diagnosis of patients suspected to have tuberculosis who have negative smears and those who cannot produce sputum and other diagnosis like malignancy to be ruled out.

KEYWORDS

Flexible Fibreoptic Bronchoscopy, Bronchial Wash, Smear-Negative Sputum, Bronchoalveolar Lavage (BAL).

HOW TO CITE THIS ARTICLE: Shunmugam M, Pratheeban J, Kumar S. Role of fibreoptic bronchoscopy in the diagnosis of sputum smear-negative pulmonary tuberculosis in tertiary care. J. Evid. Based Med. Healthc. 2016; 3(73), 3957-3960.

DOI: 10.18410/jebmh/2016/846

INTRODUCTION: Tuberculosis continues to be a major health problem in worldwide and causes approximately 2 million deaths per year, 98% of which occur in low income countries.^[1] India has the highest TB burden of any country in the world.^[2,3] Microbiological diagnosis is the gold standard for the effective treatment of pulmonary tuberculosis. For obtaining the correct sputum sample, patient education is imperative. However, even if the correct sample is expectorated, the bacillary population has to be at least 10000 per millilitre, to get the smear positive for acid fast bacilli (AFB).^[4] Moreover, it depends on the previous treatment, default behaviour, and effective cough. Again 31% of the new cases may be smear-negative for AFB.^[5] Difficulties arise when a patient who is suspected of active

tuberculosis, both clinically and radiologically, does not produce sputum.

Harris et al found that 40-60% of patients with active pulmonary tuberculosis suspected clinically or radiologically may fail to produce sputum, or when it is available AFB may be negative.^[6] This poses problem to the clinicians who often have to embark on empirical antituberculosis treatment if clinical suspicion is high, at the same time subjecting patient to potentially toxic drugs and the inconveniences of prolonged therapy. Diseases like bronchogenic carcinoma and diffuse parenchymal, interstitial lung diseases are sometimes missed because cases are put within the grey area of tuberculosis suspects by empirical management. On the other hand if not treated, 64% of sputum-negative suspects would need chemotherapy within 12 months. Sputum-negative pulmonary tuberculosis still remains a common problem, more so in immunocompromised patients. Fibreoptic bronchoscopy offers an effective of investigative tool in such cases, whereby bronchial secretion and washing can be collected from the most likely abnormal site under direct vision. This study was carried out to know the usefulness of bronchoscopy in sputum smear-negative pulmonary

Financial or Other, Competing Interest: None.
Submission 12-08-2016, Peer Review 22-08-2016,
Acceptance 30-08-2016, Published 10-09-2016.

Corresponding Author:

Dr. Suresh Kumar,

Room. No. 44, Resident Quarters,
Kanyakumari Government Medical College,
Kanyakumari-629201, Tamilnadu.

E-mail: suresh_kumardr@yahoo.co.in

DOI: 10.18410/jebmh/2016/846



tuberculosis patient diagnosed on clinically and radiological grounds.^[7,8]

METHODOLOGY: The study was conducted in Kanyakumari Government Medical College Hospital during the period of January 2015-June 2016. This is a hospital based prospective cross sectional study. The study protocol was approved by the institution's ethical committee. Sixty patients aged above 18 years old who were suspected of having pulmonary tuberculosis based on clinical and radiological appearances were prospectively studied. All subjects had at least 2 sputum smear examinations which were negative for acid fast bacilli according to the RNTCP. The bronchoscopy was performed transnasally using flexible fiberoptic video bronchoscope (Olympus adult type) by pulmonologist under local anaesthesia. All patients received lignocaine 10% spray to the nose and throat and lignocaine 2% solution to the vocal cords, trachea and bronchi. Between 40 to 120 mg lignocaine was used for the anaesthesia of bronchial trees. Premedication with Inj. Glycopyrrolate 1 mL intramuscularly was given to all the in-patients half an hour before the procedure. A thorough examination of bronchial tree was carried out and bronchial aspirate (BA), bronchoalveolar lavage (BAL), bronchial brushing, transbronchial lung biopsy (TBLB) and post-bronchoscopy sputum (PBS) were collected. The specimen obtained was placed on slides for Ziehl-Neelsen stain. Bronchial biopsy was performed on abnormal looking mucosa and stained with Eosin-haematoxylin and Ziehl-Neelsen stains.

OBSERVATION AND RESULTS: Among the 60 patients, 36 (60%) were males (Fig: 1). The average age was 47 years (Fig: 2). Out of the 60 patients, radiological pattern was studied, 27 patients had air space opacities, 13 patients had cavity, 11 patients had hilar opacity, 5 had cavity with fluid level and nodular opacity was seen in 4 patients (Fig: 3). From the study, it was shown that only 17 patients (28.3%) out of 60 patients had tuberculosis. 28 patients (46.7%) were confirmed with diagnoses other than tuberculosis. The diagnoses were community-acquired pneumonia (CAP) in 14 patients (23.3%), bronchial carcinoma in 13 (21.66) allergic bronchopulmonary aspergillosis in one patient (1.6%) (Fig: 4). On FOB, 3 cases had absolutely no abnormality; in 57 cases one or more abnormality was made (Table: 1). Histopathological examination of the material obtained by Fiberoptic bronchoscopy confirmed the diagnosis of malignancy in 13 cases; finding of pus leads to the diagnosis of community-acquired pneumonia in 14 cases. Bronchoscopic lavage fluid examined by AFB smear showed 17 cases were positive for AFB. Gram-stain and culture was positive in 14 cases, 5 of which grew Pseudomonas, 6 Klebsiella, 3 Staphylococcus and Aspergillus fumigatus in one patient.

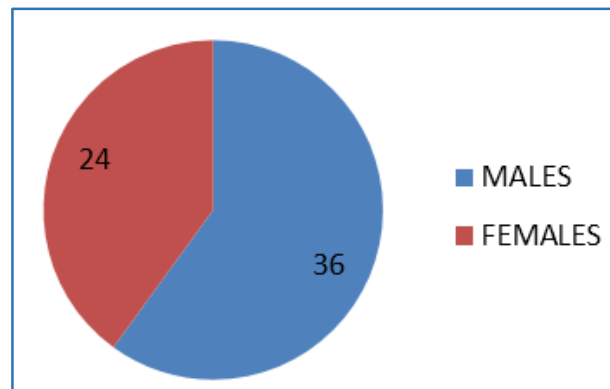


Fig. 1: Sex Wise Distribution of Cases

Sl. No	Bronchoscopic Finding	No. of Cases
1	Normal	3
2	Growth	13
3	Inflamed Mucosa	28
4	Bleeding	2
5	Pus discharge	14

Table 1: Bronchoscopic Findings

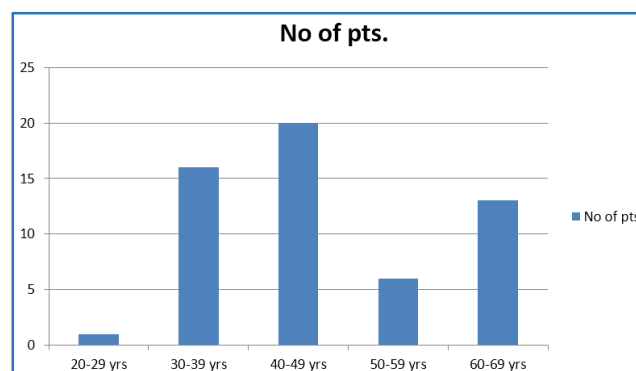


Fig. 2: Age Wise Distribution of Patients

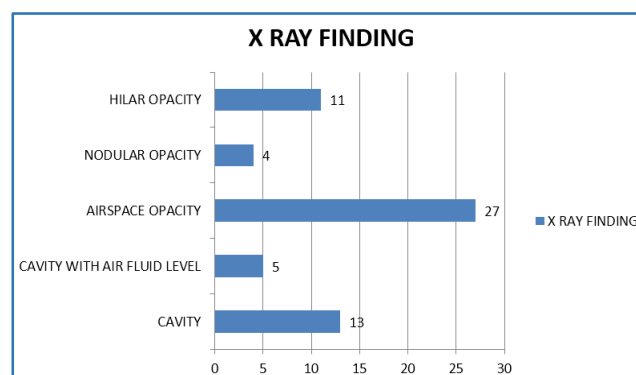


Fig. 3: Chest X-ray Finding of Patients Subjected to FOB (n=60)

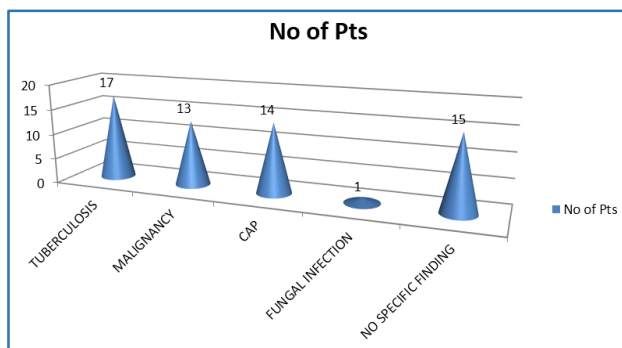


Fig. 4: Diagnostic yield of Bronchoscopy specimen (n=60)

DISCUSSION: When there is suspicion of active tuberculosis, patients whose direct examination of sputum is inconclusive represent a diagnostic and therapeutic challenge. Our study confirms this observation since other infectious, neoplastic diseases were diagnosed in these patients (28.3%) who were originally thought to be suffering from pulmonary tuberculosis. Rao.^[9] has demonstrated the usefulness of bronchoscopy among smear-negative patients in India. Of 55 sputum smear-negative patients, 15 (27.3%) had AFB-positive bronchial washings (Cultures were not performed), and bronchial carcinoma was diagnosed in 5 patients. In our study, it was found that bronchoscopic lavage smears were positive for *M. tuberculosis* in 17 (28.3%) patients. Similar results were seen in a study conducted by Yuksekol et al^[10] in which Bronchoscopic lavage smears were positive for *M. tuberculosis* in 13 (23%) patients. Bronchoscopic procedures provided overall diagnostic yields in 62.7% (23/43) of the patients. A study conducted by Charoenratanakul et al^[11] shows that bronchoscopic procedures provided overall diagnostic yields in 47.5% (19/40) of the patients. The diagnostic yield of overall bronchoscopic procedures for tuberculosis in this study was 35.7% (15/42) of patients. It consisted of positive BAL smear in 23.8% (10/42) of patients. Non-tuberculosis conditions were diagnosed by the bronchoscopic method in 27 patients (64.2%).

In the present study, bronchoscopy was useful not only for the diagnosis of tuberculosis but also for the identification of other pathologies, especially neoplasia (13 cases), whose delayed diagnosis may exclude the possibility of a surgical cure. Some authors whose objectives were similar to those of our study have also reported diagnosing neoplasia after performing bronchoscopy.^[12] Other infectious diseases such as CAP (14 cases) and aspergillosis (1 case) were also diagnosed through bronchoscopy during this study. The limitation in this study was that no investigative method other than bronchoscopy was used for detection of tuberculosis. Therefore, no comparative study was possible. The sensitivity of bronchoscopy for tuberculosis and the determination of the diagnosis of other pathologies (Neoplasia, Infectious Diseases or Diseases Mediated by the Hypersensitivity Mechanism) reinforce data in the literature indicating this type of examination when there is suspicion of tuberculosis but no confirmation in the sputum microscopy.

This study though cannot be generalised as it was conducted in a tertiary care hospital setup. High prevalence settings for TB are often resource-limited and thus a constraint for the use of bronchoscopy. There would be a need for further research on the feasibility and cost-effectiveness of bronchoscopy for TB diagnosis in resource-limited settings before it can be recommended as a useful tool. Involving medical colleges as partners and implementing Public Private Partnership are ways in which big hospitals can cater to the needs of the patients. In such setups, flexible bronchoscopy through the RNTCP can be one approach to prevent needless governmental expenditures on TB diagnosis and loss of disability-adjusted life years (DALY) in patients.

CONCLUSION: Although spread of Tuberculosis infection following bronchoscopy has occasionally been reported, Flexible fibreoptic bronchoscopy has an important role and provides excellent material in the rapid diagnosis of patients suspected to have tuberculosis, whose sputum smears are negative or who cannot produce sputum. This study suggests that in tertiary care hospitals of areas with high TB prevalence, bronchoscopic procedures should be performed in those cases in which other diagnoses such as malignancy, foreign body, etc. must be ruled out.

REFERENCES

1. Maher D, Raviglione M. Global epidemiology of tuberculosis. *Clin Chest Med* 2005;26(2):167-182.
2. Planning and financing. Global tuberculosis control; surveillance. WHO Geneva: WHO Report 2007.
3. TB: Burden of the disease in India. RNTCP status report TB India. Central TB division, Directorate General of Health Services 2008.
4. Katoch VM. Newar diagnostic technique for tuberculosis. *Indian J Med Res* 2004;120:418-428.
5. Guidelines on programmatic management of drug resistant TB (PMDT) in India. Central TB division. Revised national tuberculosis control programme. New Delhi: Central TB Division, directorate general of health services. Ministry of Health and Family Welfare 2012.
6. Harries AD, Mphasa NB, Mundy C, et al. Screening tuberculosis suspected using two sputum smear. *Int J Tuberc Lung Dis* 2000;4(1):36-40.
7. Danek SJ, Bower JS. Diagnosis of pulmonary tuberculosis by flexible fiberoptic bronchoscopy. *Am Rev Respir Dis* 1979;119(4):677-679.
8. Wallace J, Deutsch A, Harrell J, et al. Bronchoscopy and transbronchial biopsy in evaluation of patients with suspected active tuberculosis. *Am J Med* 1981;70(6):1189-1194.
9. Rao S. Significance of bronchial washings smears negativity in suspect pulmonary tuberculosis. *Trop Doct* 1993;23(4):170-171.

10. Yüksekol I, Bal S, Ozkan M, et al. The value of fiberoptic bronchoscopy in diagnosis of smear negative pulmonary tuberculosis. *Tuberk Toraks* 2003;51(4):405-409.
11. Charoenratanakul S, Dejsomritrutai W, Chaiprasert A. Diagnostic role of fiberoptic bronchoscopy in suspected smear negative pulmonary tuberculosis. *Respir Med* 1995;89(9):621-623.
12. Caymmi ALS, Silveira MAS, Montal G, et al. Role of the fiberoptic bronchoscopy in the diagnosis of patients with suspected pulmonary. *J Bras Pneumol* 2004;30(1):39-45.