

## RETROSPECTIVE STUDY ON OUTCOME OF SURGICAL MANAGEMENT OF ACETABULAR FRACTURE

Saravana Kumar Kadirvelu<sup>1</sup>, Bharath Narayanaswamy<sup>2</sup>, Aravindhan Kalamegam<sup>3</sup>

<sup>1</sup>Senior Resident, Department of Orthopaedics, Aarupadai Veedu Medical College, Puducherry.

<sup>2</sup>Assistant Professor, Department of Orthopaedics, Aarupadai Veedu Medical College, Puducherry.

<sup>3</sup>Assistant Professor, Department of Orthopaedics, Aarupadai Veedu Medical College, Puducherry.

### ABSTRACT

#### BACKGROUND

Fractures of the acetabulum occur primarily in young adults as a result of high-velocity trauma and in old age even with trivial trauma. Anatomic reduction and stable fixation of the fracture such that the femoral head is concentrically reduced under an adequate portion of the weight bearing dome of the acetabulum is the treatment goal in these difficult fractures.

The aim of the study is:

1. To study the outcome after reconstruction of fracture of acetabulum.
2. To study the postoperative complications and failures.

#### MATERIALS AND METHODS

The present study was carried out from March 2015 to September 2016 at Orthopaedics Department, Aarupadai Veedu Medical College and Hospital. During this period, 25 patients of acetabular fracture (20 males and 5 females) were managed in our hospital surgically. The indication for surgery in acetabulum fracture was decided according to displacement of fracture and it is decided by measuring the roof arc measurement developed by Matta. If the fracture has been displaced medially or anteriorly or posteriorly to 45° or 25° or 70°, then the fracture should be taken for surgery. All our patients were operated under general anaesthesia with plate and screws (reconstruction or dynamic compression). Some patients were treated with interfragmentary screws.

#### RESULTS

Our results were evaluated on the basis of both clinical and radiologic criteria as well as according to fracture type.<sup>1,2,3</sup> Radiologic evaluation showed 76% of excellent and good results and 24% of fair or poor results, while the functional outcome assessment according to d'Aubigne postal scoring and Harris hip score in acetabulum fracture, excellent functional outcome in 13 patients with posterior column acetabulum fracture and fair or poor result in 5 patients. In anterior column acetabulum fracture, 7 patients had excellent functional outcome (44%). Similar results have been reported by Letournel<sup>2</sup> and Matta.<sup>4,3,5</sup> If results were associated with the fracture type, it was clear that simple fractures gave a better outcome than complex fracture as expected, because in simple fractures, anatomic reduction is achieved more often.

#### CONCLUSION

We believe that surgical treatment of acetabular fracture leads to a satisfactory outcome provided the operation is carried out within first few days following the initial injury and anatomic reduction of the fracture is achieved.

#### KEYWORDS

Acetabular Fracture, Femoral Head, Posterior Column Fracture, Anterior Column Fracture.

**HOW TO CITE THIS ARTICLE:** Saravana Kumar K, Bharath N, Aravindhan K. Retrospective study on outcome of surgical management of acetabular fracture. J. Evid. Based Med. Healthc. 2016; 3(91), 4964-4973. DOI: 10.18410/jebmh/2016/1045

#### BACKGROUND

Fractures of acetabulum are relatively uncommon, but because they involve major weight bearing joint in the lower extremity, they assume great clinical importance. Fractures of the acetabulum occur primarily in young adults as a result of high-velocity trauma and in old age even with trivial trauma. Displacement of the fracture fragments leads to

articular incongruity of the hip joint that results in abnormal pressure distribution on the articular cartilage surface.

This can lead to rapid breakdown of the cartilage surface resulting in disabling arthritis of hip joint. Anatomic reduction and stable fixation of the fracture such that the femoral head is concentrically reduced under an adequate portion of the weight bearing dome of the acetabulum is the treatment goal in these difficult fractures.

#### AIMS AND OBJECTIVES

1. To study the outcome after reconstruction of fracture of acetabulum.
2. To study the postoperative complications and failures.

*Financial or Other, Competing Interest: None.*

*Submission 26-09-2016, Peer Review 10-10-2016,*

*Acceptance 17-10-2016, Published 11-11-2016.*

*Corresponding Author:*

*Dr. Saravana Kumar Kadirvelu,*

*No. 3, SLS Nagar, Coimbatore-641402.*

*E-mail: drsarava@gmail.com*

*DOI: 10.18410/jebmh/2016/1045*



## MATERIALS AND METHODS

The present study was carried out from March 2015 to September 2016 at Orthopaedics Department, Aarupadai Veedu Medical College and Hospital. During this period, 25 patients of acetabular fracture (20 males and 5 females) were managed in our hospital surgically.

### Inclusion Criteria

1. Age group from 18 years to 70 years of either sex.
2. Fracture duration less than 14 days after haemodynamic stabilisation.
3. Anterior column acetabular fracture with or without associated with posterior column fractures. Confirmed by clinical examination, x-ray, if required CT scan.
4. Failed internal fixation within 15 days.
5. Patient who gives informed consent and willing for follow-up.

### Exclusion Criteria

1. Compound fracture of pelvis.
2. Patient less than 18 years of old.
3. Patient unfit for surgery.
4. Pregnancy.
5. Associated comorbid conditions.
6. History of myocardial infarction less than 1 year.
7. Psychiatric illness.
8. Uncontrolled Diabetes Mellitus (DM).
9. Hypertension.
10. Pathological fracture.
11. Periprosthetic fracture.
12. Associated major visceral injury.

General information like name, age, sex, occupation and address were noted. Then, a detailed history should be taken regarding mode of injury, history of road traffic accident whether its direct injury or indirect injury with any associated injury, past medical illness and family history were also reoccurred.

### Movement

Range of movement will be painful.

The initial diagnosis of the acetabular fracture is made from the trauma AP pelvis x-ray. The two 45-degree oblique views (Judet views) are also obtained to aid in classification of the fracture and to identify fracture displacements, which may not be appreciable on the AP x-ray. The fracture were classified according to Judet and Letournel Classification with this 3D reconstructive CT to decide what type of fracture.

The affected side lower limb kept in Thomas splint with traction. Routine investigation like blood parameters like Hb, blood sugar, urea, S. creatine, BT, CT, blood grouping and Rh typing and HIV, HbsAg, HCV will be taken.

### Preoperative Preparation of the Patient

1. Patient kept in 6 hours before anaesthesia.
2. Informed consent has been obtained from the patient.

3. The pelvis, private part, affected side thigh were prepared.
4. Tranquilisers were given as advised by the anaesthetist.
5. A systemic antibiotics usually Inj. Cefoperazone and Sulbactam 1.5 g intravenously were administered 30 minutes before surgery to all patients.
6. All patients were operated under general anaesthesia.

### Postoperative Care

- Patients were kept nil per oral overnight.
- Intravenous fluids were given as needed.
- Antibiotics were continued for 12 days.
- Analgesics and tranquilisers were given according to the need of the patients.
- The operated limb was put in traction in Thomas splint.
- Check x-ray was taken to study the alignment of fracture and fixation.
- The wound was inspected on 2<sup>nd</sup> and 5<sup>th</sup> postoperative day.
- Suture removal was done on 14<sup>th</sup> postoperative day.
- Patient was discharged on 14<sup>th</sup> postoperative day.
- Rehabilitation of affected limb was started at 2<sup>nd</sup> pod with ankle pumping and quadriceps strengthening exercises to affected after 5<sup>th</sup> pod pelvic bridging exercises and toe touching gait training with lumbar support belt for anterior column patients and without LS belt for posterior column fracture for gait training for posterior column fracture if the patient was hefty can wait for 2 weeks.

### Follow up

- Regular follow up for every 4 weeks was done.
- Local examination of affected acetabulum was done, wound checking, any pain over fracture site and gait and range of movement on affected limb.
- X-ray was taken in appropriate time when they come for follow up.
- Rehabilitation of the affected extremity was done according to the stage of fracture union and time duration from day of surgery.
- Patient were followed up till radiological union.
- The functional outcome were assessed by modified Merle d'Aubigne scale and Harris hip score.

## RESULTS AND OBSERVATION

The study consists of 25 patients of fracture of acetabulum, which were treated surgically with plate and screw fixation for both column fracture. In that, most of the cases are posterior column with wall fracture of acetabulum between March 2015 to September 2016.

All the patients were available for follow up and they were followed every 6 weeks. Results were analysed clinically and radiologically.

### Site of Fracture

Judet and Letournel classification of fracture.

Type	No.	%
Posterior column	18	72
Anterior column	7	28
Both column	1	(was not operated)

### Results (Clinical - d'Aubigne- Postal Scoring System)

Pain	Movement	Walking	Grade
Continuous	Ankylosis-in bed place	Impossible	0
Persistent nightly	Ankylosis-movement	With crutches	1
	<40%-poor clinically		
Persistent in	Movement 50°-60°	With crutches	2
Walking	Flexion <40°		
Permissible pain in	Movement 60°-70°	With canes	3
Walking	Flexion 40°-60°		
Moderate in Walking	Movement 70°-80°	Good with cane	4
	Flexion 80°-90°		
Light Periodical	Movement 80°-90°	Free without cane	5
	Flexion 85°-90°, Abduction 25°		
Absent	Movement 80°-90°	Physiologic	6
Flexion 90°			

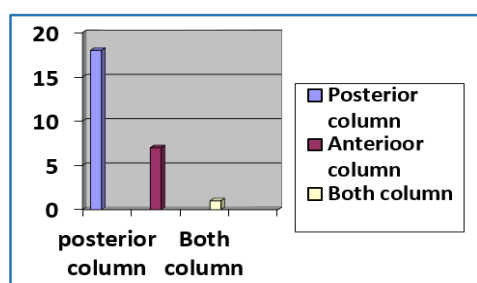
In this present study, there were 18 patients in this (80%) of posterior column fracture with posterior wall and 7 patients (20%) were anterior column fracture with anterior wall. There is one both column fracture, but it was not operated.

From March 2015 to September 2016, 25 acetabular fractures (20 males and 5 females) were managed in our hospital surgically. Patient with both column was not fixed. The age range was from 22-65 years among that male average age is 37 and female average age was 50 and over all mean age 41. Most of the patients were injured due to RTA.

**TABLE 1. JUDET-LETOURNEL CLASSIFICATION OF FRACTURES**

Type	No.	%
Posterior column	18	70
Anterior column	7	27
Both column	1	3

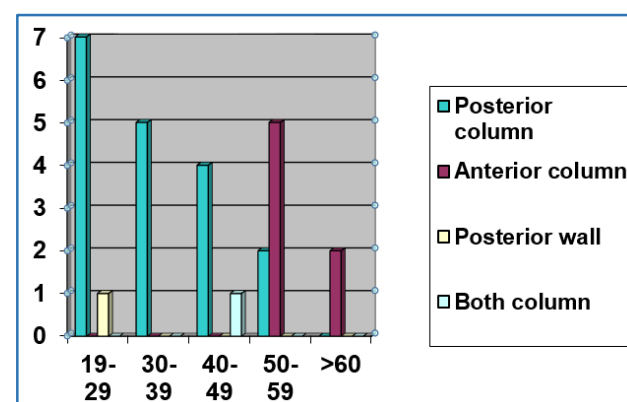
*Table 1. Judet-Letournel Classification of Fractures*



**TABLE 2. AGE INCIDENCE**

Age in Years	Number of Anterior Column Fracture	%	Number of Posterior Column Fracture	%
19-29			7	28
30-39			5	20
40-49	1 (Both Column)		4	16
50-59	5	20	2	8
>60	2	8		
<b>Total</b>	<b>7</b>	<b>28</b>	<b>18</b>	<b>72</b>

*Table 2. Age Incidence*



Majority of patients with posterior column acetabular fracture, i.e. 7 patients (28%) were in age group of 19-29. The youngest patient was 20 years old and the oldest patient was 59 years. The average patient in male was 37 years and female average age is 50 years.

Most patients 5 cases with anterior column acetabular fracture was between 50-59 years. The youngest was 40 years and oldest patient was 52 years with overall average age 41 years.

**TABLE 3. SEX INCIDENCE**

Sex	No. of Posterior Column Acetabulum Fracture	%	No. of Anterior Column Acetabulum Fracture	%
Male	10	40	2	8
Female	8	32	5	20
<b>Total</b>	<b>18</b>	<b>72</b>	<b>7</b>	<b>28</b>

*Table 3. Sex Incidence*

In posterior column acetabulum fracture, majority of males 10 patients (40%) and females were 8 (32%).

In anterior column acetabulum fracture, majority were females 5 and males were 2 patients.

**TABLE 4. SIDE AFFECTED**

Side	No. of Posterior Column and Wall Acetabular Fracture	%	No. of. Anterior Column and Wall Acetabular Fracture	%
Right	10	40	2	8
Left	8	32	5	20
Total	18	72	7	28

**Table 4. Side Affected**

In this study for posterior column with posterior wall fractures, there were patients (40%) of right-sided and patients (32%) of left-sided fracture.

For anterior column and wall acetabular fracture, there were patients (8%) on left side and patients (20%) on the right side.

**TABLE 5. ASSOCIATED INJURIES**

Type	No. of Posterior Column Acetabulum with Posterior wall	%	No. of Anterior Column Acetabulum with Anterior wall	%
Dislocation Hip (Posterior or Central)	5	20	0	
Supracondylar Fracture Femur	1	4	0	
Renal Failure	2	8	0	
Superior and Inferior Pubic Rami	5	20	4	16
Sacral Fracture	1	4	1	4

**Table 5. Associated Injuries**

In posterior column with posterior wall acetabulum fracture (56%) had associated injuries. Among them, 5 patients (20%) had posterior dislocation of hip and 1 patient had central dislocation of hip (4%) and 1 patient had supracondylar fracture femur (4%) and 2 patients had renal failure and 5 patients with superior and inferior pubic rami fracture (20%) and 1 patient with sacral fracture (4%).

In anterior column and anterior wall acetabulum fracture (16%) had associated injuries. Among them, 4 patients had superior and inferior pubic rami fracture (16%) and 1 patient with sacral fracture (4%).

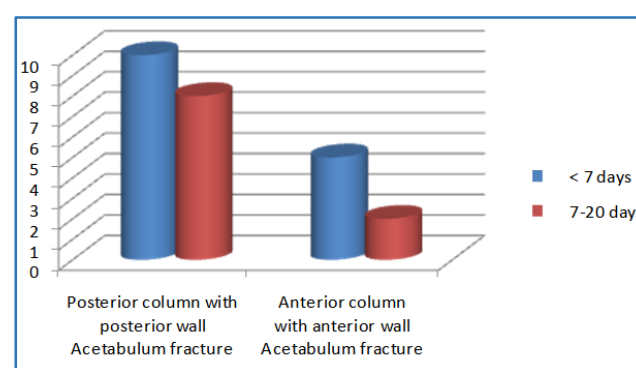
Most of hip dislocation patients were put in upper tibial pin traction and supracondylar fracture patients in volar Bryan splint before surgery and others in Thomas splint.

**TABLE 6. TIME INTERVAL FOR SURGERY**

All patients were operated as early as possible once the general condition of the patient were stable.

Time of Surgery	No. of. Posterior Column with Posterior Wall Acetabulum Fracture	%	No. of. Anterior Column with Anterior Wall Acetabulum Fracture	%
<7 days	10	40	5	20
7-20 days	8	32	2	8

**Table 6. Time Interval for Surgery**



In posterior column with posterior wall fracture 10 (40%) were operated in first week and 8 (32%) were operated in the second week.

In anterior column with anterior wall fracture 5 (20%) were operated in first week and 2 patients (8%) were operated within 2 weeks.

All patients were operated under general anaesthesia.

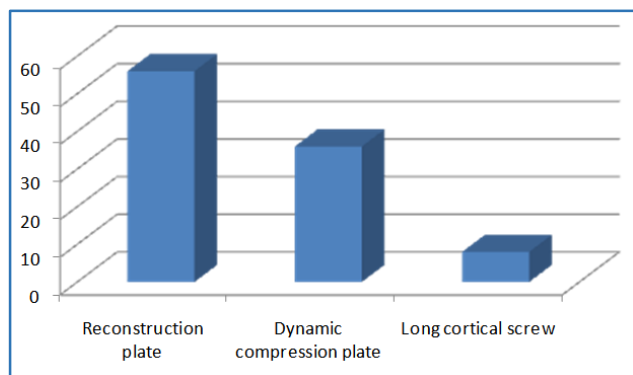
**TABLE 7. TYPES OF IMPLANT**

For both anterior column and wall and posterior column and wall.

This acetabulum fracture are fixed with plate and some with cortical screw and some with cancellous screw.

Type of Plate and Screws	Number of Patients	Percentage
Reconstruction Plate	14	56
Dynamic Compression Plate	9	36
Long Cortical Screw	2	8

**Table 7. Types of Implant**



In patients (14), reconstruction plate were used; in patients (9), dynamic compression plates were used; in patients, long cortical screws were used (2). Commonly, reconstruction plate has been used.

**TABLE 8. TYPES OF PLATE AND LENGTH**

The plates were intraoperatively bent to the contour and curvature of the acetabulum.

The length of the plate to be used was determined according to the extent of comminution at the fracture. The aim was to place at least four screws in the medial and lateral main fragments through both cortices of the bone.

Type of Plate	6 Hole	7 Hole	8 Hole	9 Hole
Reconstruction Plate	4	7	2	-
Dynamic Compression Plate	3	4	2	-
Interfragmentary Screws			-	
<b>Total</b>	<b>7</b>	<b>14</b>	<b>4</b>	<b>-</b>

**Table 8. Types of Plate and Length**

In 4 patients (16%), 6 hole reconstruction plates were used; in 7 patients (28%), 7 hole reconstruction plate used; in 2 patients (8%), 8 hole reconstruction plate used; in 3 patients (12%), 6 hole dynamic compression plate were used and in 4 patients (28%), 7 hole dynamic compression plate were used. In another 2 patients (8%), 8 hole dynamic compression plate were used.

Commonly, 7 hole plates were used, i.e. 13 cancellous screws were used for following size 22 to 18 mm.

### Procedure

For acetabulum fracture.

7 patients of anterior column with wall fracture patients were fixed with reconstruction plate. For 18 posterior column with posterior wall acetabulum fracture patients, 10 patients were fixed with reconstruction plate and 6 patients were fixed with DCP and two patients with compression screws dressing was changed at 2<sup>nd</sup> postoperative day and sutures were removed at 14<sup>th</sup> postoperative day on all patients.

Physiotherapy exercises were started from the 1<sup>st</sup> day of surgery and the patients was mobilised to sitting position with quadriceps training. Following surgical drain removal, patients were mobilised with non-weight bearing using walking frame for 1 month partial weight bearing for the following 3 weeks and full weight bearing from 2 months onwards. Hip abductor and quadriceps strength training was continued throughout these 2 months.

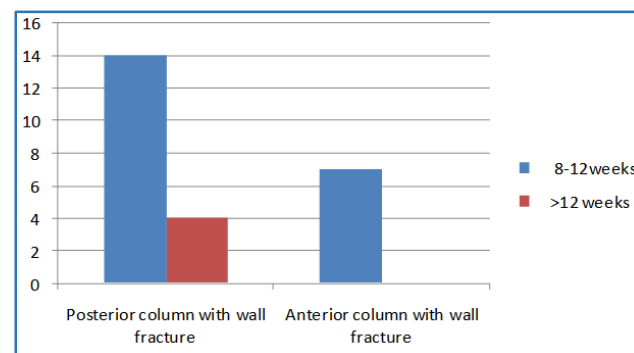
The patients were followed every 6 weeks

**TABLE 9. DURATION OF UNION**

The fracture was considered to be united when clinically there was no tenderness. Radiologically, the fracture line was not visible and full unprotected function of the limb was possible.

Duration of Union	No. of Posterior Column with Wall Fracture	%	No. of Anterior Column with Wall Fracture	%
8-12 weeks	14	56	7	28
>12 weeks	4	16	-	-

**Table 9. Duration of Union**



In posterior column and wall acetabular fracture, 14 patients (56%) united at the end of 16 weeks.

In 4 patients (16%) delayed union occurred. It was due to comminution and some delay in traction during preoperative processing, which was united at 20 weeks.

In anterior column, 7 patients united at the end of 16 weeks.

We allow the patient to weight bear as much as they can. We have not removed any implant, so for only one patient who went for osteonecrosis of femoral head, we did total hip replacement for which implant removal has been done.

### Complication

Immediate complication included uncontrollable bleeding in one patient through the suction drain, which lasted for 7 days. Sciatic or other nerve paresis was not recorded.

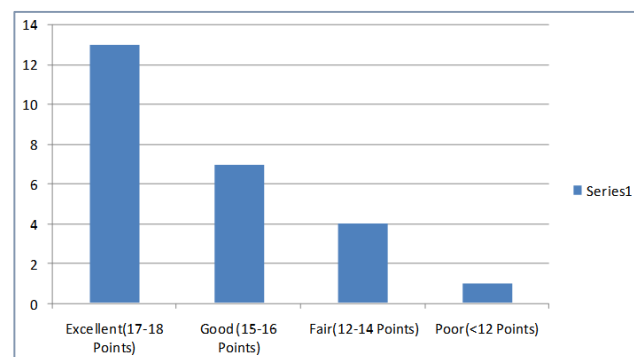
Late complications included femoral head osteonecrosis in one patient after 2 years. He has undergone total hip replacement.

**Table 10. Functional Outcome**

The functional outcome is assessed by d'Aubigne-postal scoring and Harris hip score.

**RESULTS (Clinical- d'Aubigne-Postal scoring System)**

Excellent (17-18 Points)	13
Good (15-16 Points)	7
Fair (12-14 Points)	4
Poor (<12 Points)	1
<b>Table 10. Functional Outcome</b>	

**Functional Outcome****RESULTS (Clinical Harris Hip Score System)**

Harris hip score, 12 patients were found excellent and 8 patients were found good and 3 patients come under fair and 2 patients comes under poor result.

The follow-up schedule was 3, 6 and 12 months postoperatively and subsequently at two years when the operative outcome had been finalised and final evaluation of fracture healing and functional outcome could be performed quite reliably. Postoperative follow up ranged from 6 months to 5 years with a mean of 3.2 years. Fracture fixation outcome was radiological evaluation with AP x-ray of the pelvis from the mean displacement in the basic projection and patients were functionally evaluated with the d'Aubigne-postal scoring system and Harris hip score (Table-10) with

parameters; the pain, the motion of the hip and the ability of walking.

Fracture reduction and fixation was checked with early postoperative x-ray, while at a later stage, x-rays helped in the evaluation of the presence of complications such as osteonecrosis, posttraumatic osteoarthritis and heterotopic ossification. Based on the radiological criteria used by Matta, the result was considered excellent when the hip joint had a normal appearance on plain x-ray; good, when a small degree of subchondral sclerosis, joint space narrowing and osteophytes were present; fair, when joint space was narrowed up to 50% and considerable osteophytes and subchondral sclerosis were present; and poor, when the joint space was narrowed by more than 50%. A degree of femoral head collapse as well as clear signs of osteoarthritis were present. Based on the above-mentioned radiological criteria, the result was excellent in 12 (60%); good in 8 (30%); fair in 3 (7.5%); poor in 2 (2.5%), (Table 10).

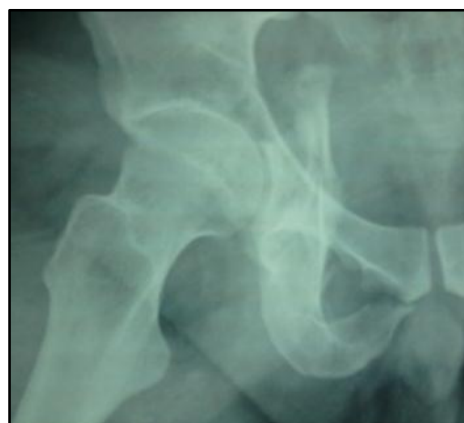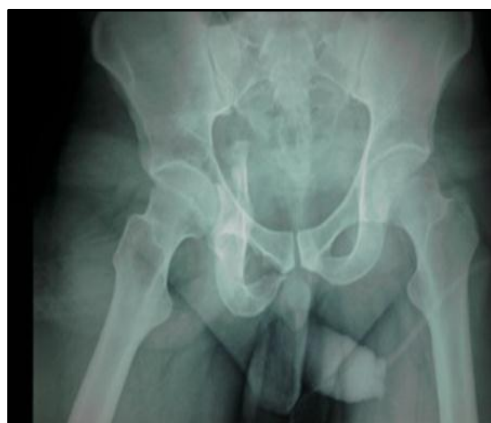Result were evaluated as regards the fracture type according to anatomy. In this procedure, it was evident that out of the 18 posterior column fracture 13 has excellent or good results and 5 has fair or poor results. Out of 7 anterior column fracture, 7 excellent result or good results.

Immediate complication included uncontrollable bleeding in one patient through the suction drain, which lasted for 7 days. Sciatic or other nerve paresis was not recorded.

Late complications included femoral head osteonecrosis in one patient after 2 years. He has undergone total hip replacement.

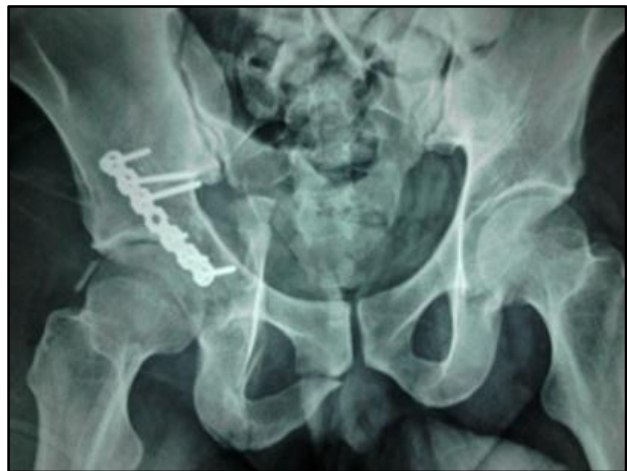**Results as per Judet-Letournel Grading of Fracture**

	Posterior Column	Anterior Column
Excellent+good	13	7
Fair+poor	5	-
<b>Total</b>	<b>18</b>	<b>7</b>

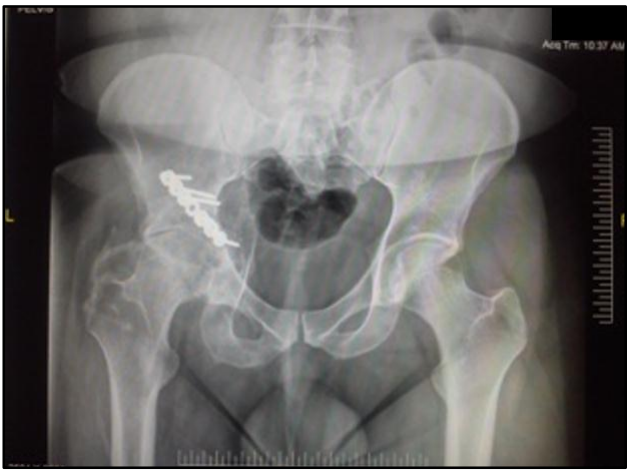**CLINICAL X-RAY AND PHOTOGRAPH****PREOPERATIVE**



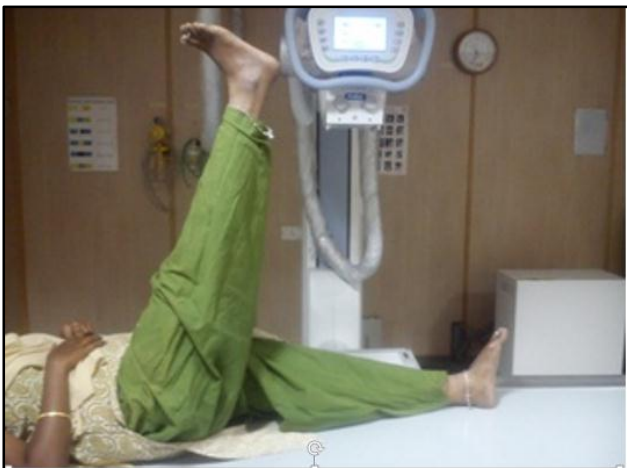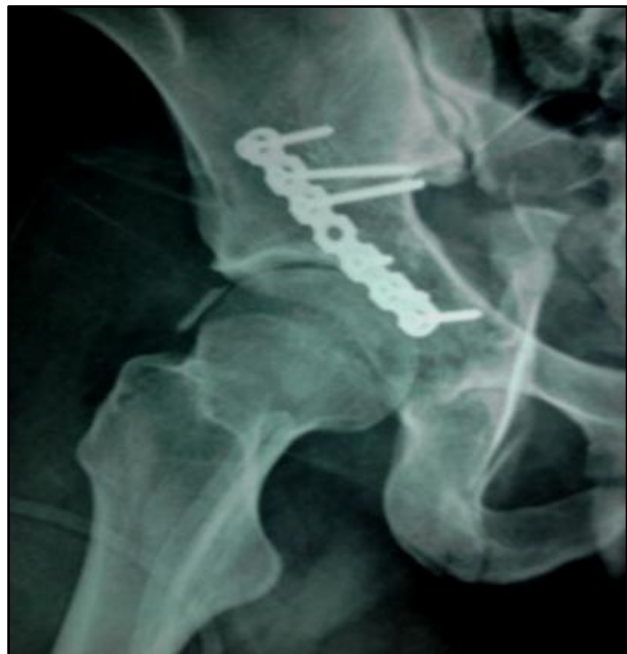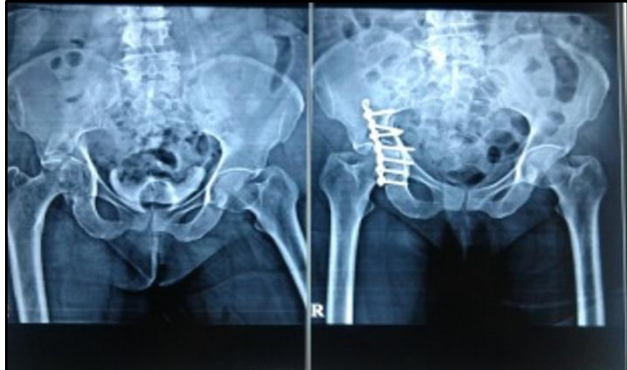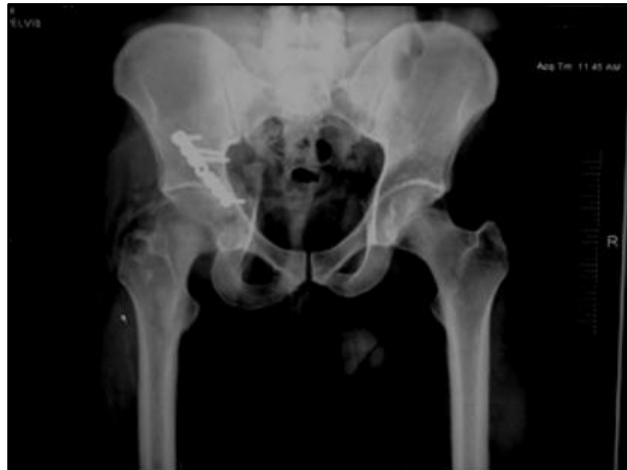**1<sup>st</sup> Postop**

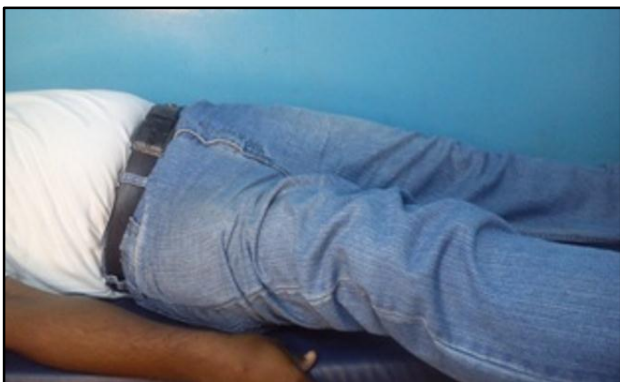
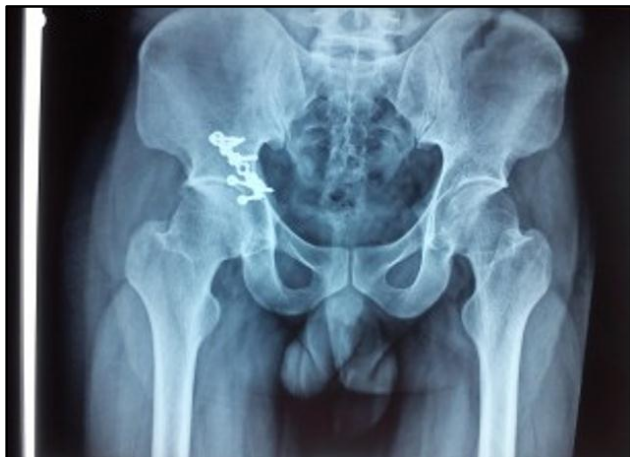
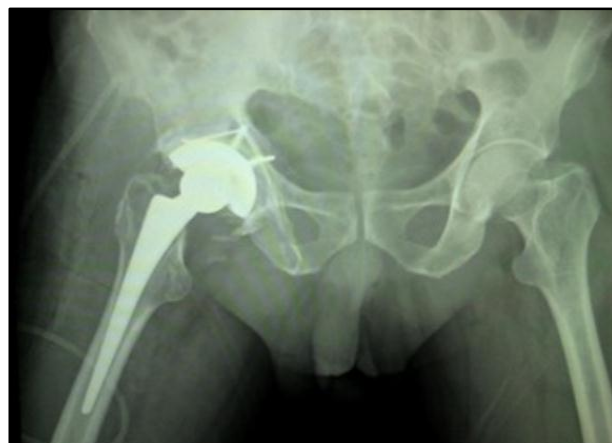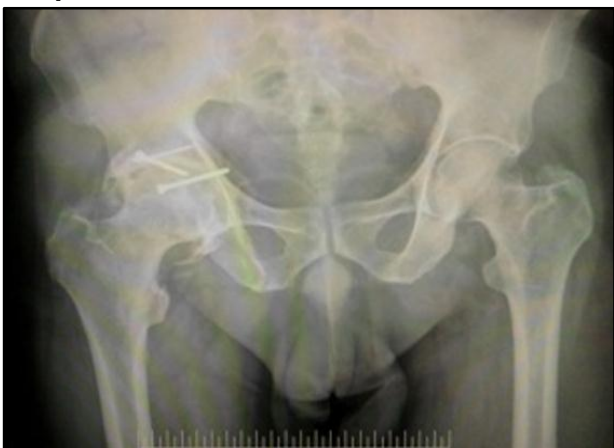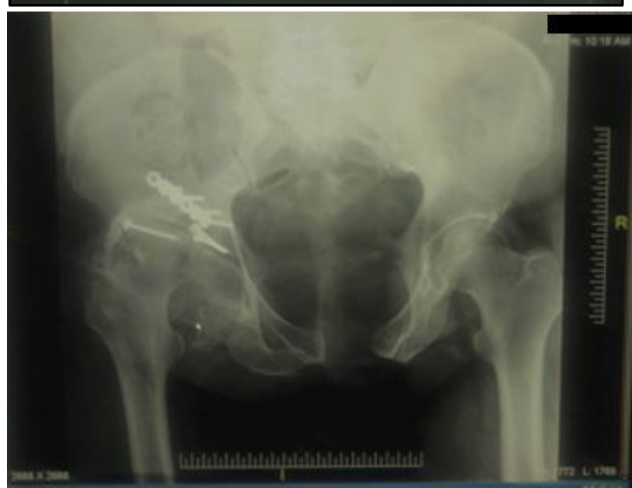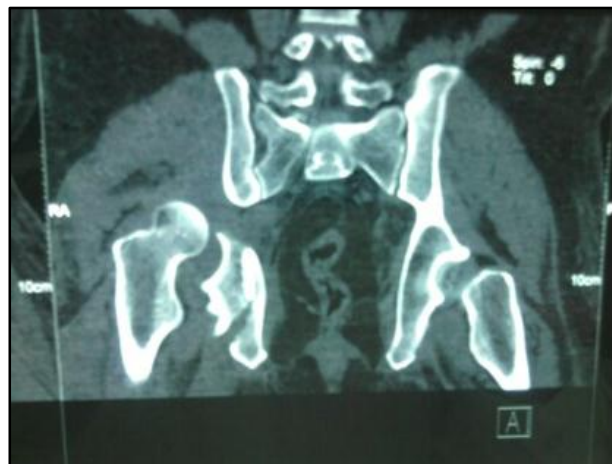**After One Year Follow up**



**6<sup>th</sup> Month Follow up**



**Full Union****Complication****Failed****DISCUSSION**

Surgical treatment of displaced acetabular fracture is beyond any doubt the treatment of choice, because it gives the better chances for anatomical reconstruction of the joint.<sup>6,7,1,8,2,9</sup> The goals of surgical treatment are the correction of significant deformity, prevention of late deformity and instability and restoration of pain-free function.<sup>10,7,1,3</sup> By far, the commonest complication of these fractures is posttraumatic osteoarthritis of the hip, which often leads to a total hip replacement.<sup>10,7,1</sup> Other less frequent complications are osteonecrosis of the femoral



head, osseous defects of the acetabulum, shortening of the affected limb and heterotopic ossification.<sup>11,10,6,7,1,12</sup>

The main criterion for surgical management is the degree of displacement of the acetabulum. In our series, the criterion used for surgical management was a fracture displacement of more than 5 mm as suggested by Matta<sup>1</sup> and Johnson et al.<sup>13</sup> Patients in our series were operated upon between the 1<sup>st</sup> and 8<sup>th</sup> day following the initial injury, with a mean of 4 days. Delay of operative management was usually the case in polytrauma patients with various other injuries that were in ICU for prolonged period of time. Most authors prefer to place the patient in a prone position for the approach of such fractures.<sup>6,1,2</sup> We feel that the approach and positioning we used allow for adequate exposure for the fixation of the posterior column of the acetabulum, which are the commonest fracture pattern. The goal of operative management, stable internal fixation with combination of interfragmentary screws and a reconstruction plate. Anatomic reduction was achieved in 13 (52%) of cases, which is considered to be very satisfactory.<sup>1,8,2,9</sup> The postoperative application of skeletal traction is a contentious issue and most authors nowadays suggest that it should not be used provided that the internal fixation achieved is rigid enough.<sup>7,1,8</sup> We have not used skeletal traction postoperatively in all our patients, which in turn would prolong their rehabilitation time and we feel that implantation of postoperative skeletal traction can be totally abolished in case where internal fixation is stable enough.

Our results were evaluated on the basis of both clinical and radiologic criteria as well as according to fracture type.<sup>1,2,3</sup> Radiologic evaluation showed 76% of excellent and good results and 24% of fair or poor results, while clinically evaluation showed 80% of excellent or good results and 20% of fair or poor results. An analogy between clinical and radiologic results was recorded in our cases, a fact supported by the literature as well.<sup>7,1,3</sup> The rate of excellent and good results in our series (80%) is considered very satisfactory. Similar results have been reported by Letournel<sup>2</sup> and Matta.<sup>4,3,5</sup> If results were associated with the fracture type, it was clear that simple fractures gave a better outcome than complex fracture as expected, because in simple fractures anatomic reduction is achieved more often.

Heterotopic ossification was not seen in our series of patients. The rates of heterotopic ossification reported by various authors in series of acetabular fractures surpass 50% in some series.<sup>4,3,9,14,9</sup> Matta<sup>4</sup> in a series of 262 patients where no prophylaxis against heterotopic ossification as high as 82%. We administered indomethacin to all of our patients and we believe it has drastically lowered the rate of heterotopic ossification. Indomethacin is believed to decrease the rate of this complication to about 30-40%.

Femoral head osteonecrosis was recorded in one patient (4%) who subsequently underwent a total hip replacement. Matta<sup>5</sup> reports a rate of femoral head osteonecrosis of 3%, while Moroni brings it up to 7%. Posttraumatic osteonecrosis is considered quite satisfactory in view of the fact that rates of 20-55% are reported in the literature.<sup>13,7,1,2,3,12</sup> The presence of posterior dislocation of the hip, a chondral lesion

of the femoral head or the acetabulum, failure to obtain anatomical reduction and complex as opposed to simple fracture are through to be the main predisposing factors or the advent of posttraumatic osteoarthritis and femoral head osteonecrosis.

## SUMMARY

- Twenty five patients with acetabular fracture was treated surgically. Among them, 18 patients of posterior column fracture were fixed with recon plate and screws, dynamic compression plate, some with interfragmentary screw and 7 patients with anterior column fracture, few with posterior wall fracture, plate and screws between January 2012 to June 2016 Aarupadai Veedu Medical college, Pondicherry.
- Patients above 18 years were included in this study and the patient's age ranged from 19 to 63 years. Posterior column fracture is common between 19 to 49 years and anterior column fracture is common 50 to 60 years in this study.
- Road traffic accident was the cause for this fracture in most of the patients.
- Male are more commonly affected.
- 30% of the patients had associated injury like dislocation of hip joint (posterior, central), sacral fracture, supracondylar fracture femur, inferior and superior pubic rami fracture and pubic diathesis fracture. Dislocation were reduced and supracondylar fracture were fixed.
- In 14 patients (85%), surgery was done within the first week.
- The indication for surgery in acetabulum fracture was decided according to displacement of fracture and it is decided by measuring the roof arc measurement developed by Matta.
- If the fracture has been displaced medially or anteriorly or posteriorly to 45° or 25° or 70°, then the fracture should be taken for surgery.
- All our patients were operated under general anaesthesia with plate and screws (reconstruction or dynamic compression).
- Some patients were treated with interfragmentary screws.
- Reconstruction plates were used in 13 patients and dynamic compression plates in 9 patients.
- Interfragmentary screws were used in 3 patients with K wire.
- All our patients were immobilised in Thomas splint for 5 days if it is displaced.
- Average duration of stay in hospital is 14 days.
- All the patient were mobilised with toe touching walking after two weeks.
- The duration of union in patients with posterior column acetabulum fracture ranges from 8 to 12 weeks (average of 11.28 weeks) in 14 patients. 4 patients went for delayed union, one fracture was failed.
- In anterior column, acetabulum fracture ranges from 8 to 12 weeks. All fractures were united.

- The functional outcome assessment according to d'Aubigne- postal scoring and Harris hip score in acetabulum fracture excellent functional outcome in 13 patients (with posterior column acetabulum fracture and fair or poor result in 5 patient).
- In anterior column acetabulum fracture, 7 patients had excellent functional outcome (44%).
- One patient developed osteonecrosis of femoral head and he ended up with total hip replacement.

## CONCLUSION

- Acetabular fractures are high-velocity trauma. It has been treated surgically when there is displacement of fracture according to roof arc measurement and Judet and Letournel's classification.
- Acetabulum has been fixed with open reduction and internal fixation with reconstruction plate and dynamic compression plate and some fracture are fixed with interfragmentary screws.
- Most of acetabular fracture will be associated with dislocation of hip. Open reduction is needed to reduce dislocated hip.
- In this study, primary open reduction and internal fixation with reconstruction plate and screws of acetabular fracture provides a more rigid fixation and the reconstructive plate can be countered according to the curvature because most of the vital structures are there near the fracture site. Reconstructive plate is used for 13 patients.
- In this study for 9 patients, dynamic compression plate has been used to fix the fracture.
- In this study for 3 patients, interfragmentary screw has been used to fix the fracture when the plate cannot be used to fix the fracture.
- All the fracture united and there was no nonunion.
- One patient developed osteonecrosis and underwent total hip replacement.
- 13 patients gave excellent and good result in posterior column fracture acetabulum and 7 patients of anterior column acetabulum fracture with excellent and good result, 4 gave fair result and one patient gave poor result.
- One failure has been reported.
- In conclusion, we believe that surgical treatment of acetabular fracture leads to a satisfactory outcome provided the operation is carried out within first few days following the initial injury and anatomic reduction of the fracture is achieved.

## REFERENCES

1. Judet R, Judet J, Letournel E. Fracture of the acetabulum: classification and surgical approaches for open reduction. *J Bone Joint Surg Am* 1964;46:1615-1646.
2. Letournel E. Acetabulum fractures: classification and management. *Clin Orthop Relat Res* 1980;151:81-106.
3. Moroni A, Caja VL, Sabato C, et al. Surgical treatment of both-column fractures by staged combined ilioinguinal and kocher-Langenbeck approaches. *Injury* 1995;26(4):219-224.
4. Matta MJ, Anderson LM, Epstein CH, et al. Fracture of the acetabulum. A retrospective analysis. *Clin orthop Relat Res* 1986;205:230-240.
5. Panatazopoulos T, Mousafir C. Surgical treatment of central acetabular fractures. *Clin Orthop and Rel Res* 1989;246:57-64.
6. Deo S, Tavares SP, Pandey RK, et al. Operative management of acetabular fracture in oxford. *Injury* 2001;32(7):581-586.
7. Goulet AJ, Bray TJ. Complex acetabular fractures. *Clin Orthop Relat Res* 1989;240:9-20.
8. Kaempffe FA, Bone LB, Border JR. Open reduction and internal fixation of acetabular fractures: heterotopic ossification and other complications of treatment. *J Orthop Trauma* 1991;5(4):439-445.
9. Panatazopoulos TH, Nicolopoulos SC, Moussafir C. Surgical treatment of acetabular posterior wall fracture. *Acta Orthop Hell* 1989;40:87-95.
10. Routt ML, Swiontkowski MF. Operative treatment of complex acetabular fractures. Combined anterior and posterior exposures during the same procedure. *J Bone and Joint Surg* 1990;72(6):897-904.
11. Bray TJ, Esser M, Fulkerson L. Osteotomy of the trochanter in open reduction and internal fixation of acetabulum fractures. *J Bone and Joint surgery* 1987;69(5):711-717.
12. Templeman DC, Olson S, Moed BR, et al. Surgical treatment of acetabular fractures. *Instructional Course Lectures* 1999;48:481-96.
13. Brooker A, Bowerman JW, Robinson RA, et al. Ectopic ossification following total hip replacement. Incidence and a method of classification. *J Bone Joint Surg Am* 1973;55(8):1629-1632.
14. Guyton JL, Perez EA. Fractures of acetabulum and pelvis. In: Canale ST, Beaty JH. *Campbell's operative orthopaedics*. 11<sup>th</sup> edn. Mosby Elsevier 2008:p. 3311.