

Reactive Hyperplastic Lesions of the Oral cavity

Sweta A, Vivek Narayan*

Department of Oral Medicine and Radiology, Saveetha University, Chennai, India.

ABSTRACT

Oral cavity is constantly being exposed to many stimuli which can irritate the oral mucosa leading to a variety of hyperplastic reactions. Reactive hyperplastic lesions (also called RHLs) are tumorlike hyperplasia produced in response to chronic irritation or trauma. These hyperplastic lesions simulate non-neoplastic proliferations. The aim of the study is to determine the prevalence of reactive hyperplastic lesions in the oral cavity. This is a retrospective study. All the data were taken from the patient archives of the dental institute. Patients with a wide age range were included. A total of 700 patients were included in the study. All the necessary information was collected and entered in Microsoft Excel spreadsheet and subsequently transferred to SPSS version 23.0 for statistical analysis. Chi square tests were employed to find the association between different variables and $p < 5\%$ was considered statistically significant. The study was done in an institutional setting. The prevalence of the reactive lesions were found to be 79.14%. A male predilection was seen for the reactive lesions. The 26 - 45 year age group was more prone for reactive hyperplastic oral lesions. Patients in their 2nd to 4th decades of life tend to neglect / ignore certain persistent irritants present in the oral cavity which leads to reactive lesions. Hence more patient awareness about the reactive hyperplastic lesions must be spread by the dental professionals so as to curtail the rising number of these lesions.

KEYWORDS

Reactive lesions, Hyperplastic lesions, Fibroma, Pyogenic granuloma, Pulp polyp, Novel study

Corresponding Author:

Vivek Narayan, Department of Oral Medicine and Radiology, Saveetha University, Chennai, India.

E-mail: viveknarayan@saveetha.com

How to Cite This Article:

Narayan V, Swetha A. Reactive Hyperplastic Lesions of the Oral cavity J Evid Based Med Healthc 2022;9(06):1-8.

Received date: 08-March-2022;
Manuscript No: JEBMH-21-50873;
Editor assigned date: 11-March-2022;
PreQC No. JEBMH-21-50873(PQ);
Reviewed date: 25-March-2022;
QC No. JEBMH-21-50873;
Revised date: 30-March-2022;
Manuscript No. JEBMH-21-50873;
Published date: 05-April-2022;
DOI: 10.18410/jebmh/2022/01.50873

Copyright © 2022 Swetha A, et al. This is an open access article distributed under Creative Commons Attribution License [Attribution 4.0 International (CC BY 4.0)]

INTRODUCTION

Oral cavity is constantly being exposed to many stimuli which can irritate the oral mucosa leading to a variety of hyperplastic reactions. Reactive hyperplastic lesions (also called RHLs) are summerlike hyperplasia produced in response to chronic irritation or trauma. These hyperplastic lesions simulate non-neoplastic proliferations.¹ The goal for the treatment of these conditions is the elimination of the stimulating agents followed by proper dental therapy. Reactive lesions are typically gives response to chronic inflammation caused by various forms of low grade chronic irritations to the oral mucosa such as dental plaque and calculus, sharp edges of grossly carious teeth, faulty dental restorations, chronic biting habits, ill-fitting dental / oral appliances and food impactions.^{2,3} These lesions have a very similar appearance to benign neoplastic proliferations. Different types of localized reactive lesions of oral cavity are Focal Fibrous Hyperplasia (FFH), pyogenic granuloma (PG), irrigational fibroma, Peripheral Giant Cell Granuloma (PGCG), Peripheral Ossifying Fibroma (POF), fibro-epithelial hyperplasia / polyp, inflammatory fibrous hyperplasia, and inflammatory gingival hyperplasia.⁴ Pyogenic granuloma is the second predominant lesion among the RLs. Various synonyms include pregnancy tumour, benign vascular tumour, and vascular epulis. Recently, it has been also called lobular capillary haemangioma owing to the presence of well-circumscribed and distinct lobular arrangement, with central large vessels and peripheral aggregates of well-formed capillaries. If PGs are left untreated over time, it undergoes fibrous maturation with ossification and develops into POF. The main etiological factors are the presence of plaque, calculus, and pregnancy.^{5,6} Traumatic fibroma can occur anywhere in the mouth, the most common location is the buckle mucosa along the bite line. It was found that gingiva is the most common site for fibroma with equal incidence in lower and upper jaws. The term "focal fibrous hyperplasia" implies localized progressive proliferation of oral mucosa in response to local irritation or local injury. FFH was the most common lesion occurring over a wide age range (9 – 70 years), with a peak incidence in the third to fourth decades.^{7,8} Clinically, the lesion may be round to ovoid, asymptomatic, smooth - surfaced, firm, sessile or pedunculated mass, the diameter of which may vary from 1 to 2 cm. Hard in consistency and pale pink in colour, the surface may be hyperkeratosis or ulcerated owing to repeated trauma. Histopathologically, the sections showed hyperplastic stratified squamous epithelium which

was partly hyperkeratosis and hyperorthokeratosis at some places. Thin, finger-like rete ridges extend into underlying connective tissue stromal which is fibro cellular. Solid nodular mass of dense hyalinised fibrous connective tissue arranged in haphazard fascicles was seen in one of the lesions. A mild-to-moderate chronic inflammatory cell infiltrate was seen at a few sites. Frictional keratosis represents increased keratin production in response to chronic mechanical irritation. The retro molar pad and edentulous alveolar ridge are the most common sites of involvement due to trauma from food being crushed against the mucosa during mastication.¹ A fractured tooth or rough restoration may lead to the development of frictional keratosis on the adjacent lateral tongue or buckle mucosa.^{9,10} Frictional keratosis appears as a discrete white plaque with a rough or corrugated surface and frequently has blending margins with the adjacent unaffected mucosa. These lesions do not undergo malignant change and should resolve after the source of irritation is eliminate.¹¹ Because frictional keratosis is a specific entity, it should not be described or categorized as a leukoplakia. Including frictional keratosis in studies of leukoplakia dilutes the prevalence of dysplasia and squamous cell carcinoma seen in true leukoplakia, a potentially malignant disorder. Epulis fissuratum or denture-induced hyperplasia is a reactive lesion of the oral cavity caused by low grade chronic trauma from denture.^{12,13} About 70 % of patients wear ill-fit dentures continuously all day long for more than 10 years. The lesion appears as an asymptomatic single fold or multiple folds of hyperplastic tissues in the alveolar vestibule along denture flanges with a smooth surface, soft to firm consistency, and a normal coloration. Pulp polyp or chronic hyperplastic pulpitis or pulpitis apart is an uncommon reactive lesion, which occurs when caries have destroyed the tooth crown.¹ It appears as a smooth, soft to firm, red to pink, pedunculated, or sessile mass occupying the entire carious cavity in the affected tooth resembling an enlarged gingival tissue. The size of the lesion varies from less than 1 cm in diameter to large masses.^{14,15} It is most frequently found in the deciduous and permanent first molars of children and young adults and is a rare phenomenon in middle-aged adults. It is usually asymptomatic, but discomfort can occur during mastication. Response to electrical and thermal stimuli may be normal. Our team has extensive knowledge and research experience that has translate into high quality publications.¹⁶⁻³⁵ The aim of the study is to

determine the prevalence of reactive hyperplastic lesions of the oral cavity.

MATERIALS AND METHODS

Study Design

This is a retrospective study conducted in a private dental institution. The patient case records were reviewed for the necessary information by a trained examiner. The advantage of conducting the study in an institutional set up provides a population with similar ethnicity. Among patients who have visited the dental clinic of the institution, the case records of 700 patients were reviewed. A wide age range is selected for the study. The institutional ethical committee provided approval for the study.

Inclusion criteria

1. Patients who have been diagnosed with reactive lesions
2. Patients from 20 years to 70 years of age

Exclusion criteria

1. Incomplete patient data
2. Duplicate patient data
3. Patients having reactive lesions coexisting with other non-reactive / hyperplastic mucosal lesions

Sampling

A total of 700 case records of patients were reviewed to find out the prevalence of reactive / hyperplastic lesions. Convenient sampling method was used to select the patients for the study. The data obtained from the case records were cross verified with photographs.

Data Collection

All the data after thorough checking for duplicates, incomplete entries and cross verification with photographs were entered in Microsoft excel spread sheet in order to organise the data. The variables obtained from the data included age, gender, different types of reactive lesions and the presence of reactive lesions.

Statistics

The statistical analysis of the obtained data was performed by the SPSS software version 23.0. The data from the excel spread sheet was transferred to SPSS software for analysis. Chi square tests were employed in order to find the association between different variables. The final results are presented in the form of graphs for further interpretation and discussion.

RESULTS AND DISCUSSION

Among the 700 patients, 554 patients had the presence of oral reactive hyperplastic lesions. The prevalence of oral reactive hyperplastic lesions is 79.14 %. This appears to be a significant value and could be due to the sample size. A higher sample size may have yielded a different value. According to Reddy. V et al.³ the prevalence of reactive lesions were found to be 12.8 % which is less when compared with the present study result. This difference in the result can be attributed to sample size and ethnicity.

The distribution of the presence of oral reactive lesions was studied among males and females (Figure 1). A slight male predilection is seen (41.86 %) when compared to females (33 %). There was a statistically significant association between the gender and the presence of oral reactive lesions ($p < 0.05$). In the study by Reddy V et al.³, it was found that there was a female predilection (125 females and 85 males) which is also in contrast with the present study. This also could be due to the sample size and ethnicity.

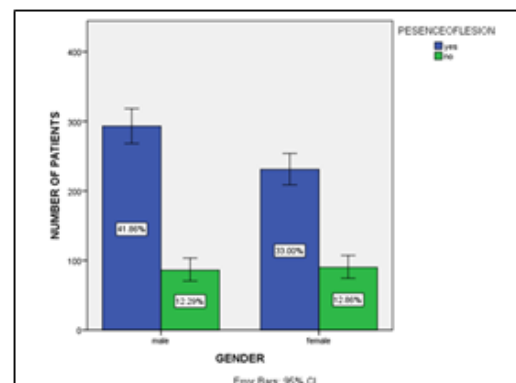


Figure 1. Bar Graph Depicts the Association between the gender and the Presence (blue) and Absence (green) of Reactive Oral Lesions. X axis represents the Gender and y axis represents the Total Number of Patients. Chi square Analysis Reveals that the Association between the Variables is Statistically Significant ($p < 0.05$). A Slight Male Predilection was seen for the Presence of Reactive Lesions Compared to Females.

The presence of reactive oral lesions was studied in different age groups (Figure 2). The age group 26 - 45 years had the maximum occurrence of oral reactive lesions (40.43 %) this was followed by the 46 - 65 age group (20.86 %), 10 - 25 age group (10.57 %) and finally by the 66 - 80 age group (3 %). There was a statistically significant association between the different age groups and presence of oral reactive lesions ($p < 0.05$). According to Hameideh Kadeh et al, lesions were more common in the 21 - 40 year age group.³⁶ This is in

accordance with the current study as the lesions were more common in the 26 - 45 age groups.

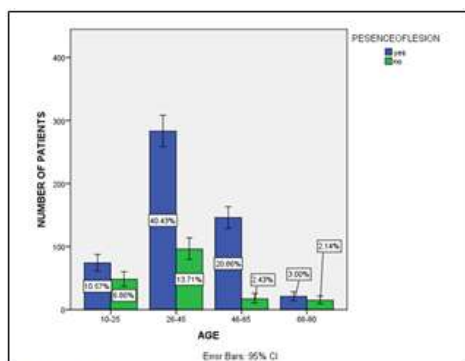


Figure 2. Bar Graph Depicts Association between the Age with presence (blue) and Absence (green) of Reactive Hyperplastic Lesions. X axis represents the age and Y axis represents the Total Number of Patients. From the Present Graph it can be Inferred that the Association between the Variables is Statistically Significant ($p < 0.05$) and Reactive Lesions was seen Maximum in the 26 - 45 age W Followed by 46 - 65 and 10 - 25 Age Groups.

The distribution of different types of oral reactive lesions was studied among males and females (Figure 3). It was found that the males had a high number of frictional keratosis (26.91 %) followed by fibroma (15.27 %) and pulp polyp (5.53 %). In females fibroma was found to be the highest (21.18 %) followed by pulp polyp (8.59 %) and frictional keratosis (7.44 %). Other lesions such as epulis fissuratum, gingival polyp, pyogenic granuloma and fibroepithelial polyp were found in small numbers in each gender. According to Hameideh Kadeh et al.³⁶ Peripheral reactive lesions are a common group of lesions that may be encountered during routine dental examinations. The most common lesions were pyogenic granuloma and irritation fibroma, respectively. These lesions were more frequent in women (60 %) than men (40 %).

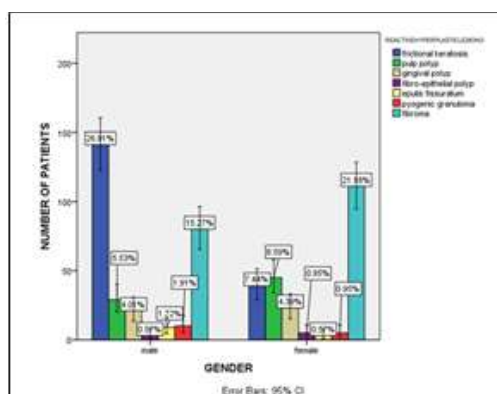


Figure 3. Bar Graph Depicts the Association between the Gender and the Types of Reactive Oral Lesions. X axis represents the Gender and y axis represents the Total Number of Patients. Chi Square Analysis reveals that the Association between the Variables is statistically significant ($p < 0.05$). Among Males Frictional Keratosis was the Highest and in Females it was Fibroma which occurred the Highest. The least occurring Lesion in Males is the Fibro epithelial Polyp and in Females it is Fibro epithelial and Pyogenic Granuloma.

The distribution of different types of oral reactive lesions among different age groups were studied (Figure 4). Fibroma was found to be the most common lesion (20.8 %) followed by frictional keratosis (16.41 %), followed by pulp polyp (8.02 %) and gingival polyp (8.02 %). These lesions are seen very commonly in the 26 - 45 years age group. The next most common age group to have oral reactive lesions is the 46 - 65 age groups. The association between the types of oral reactive lesions and the age groups was found to be statistically significant ($p < 0.05$). According to Sangle V et al.³⁷ reactive lesions were more commonly found in the 3rd and 4th decades of life which is similar to the present study where lesions are found in the 26 - 45 age group. This similarity in the result could be attributed to the similarities in the characteristics of the sample.

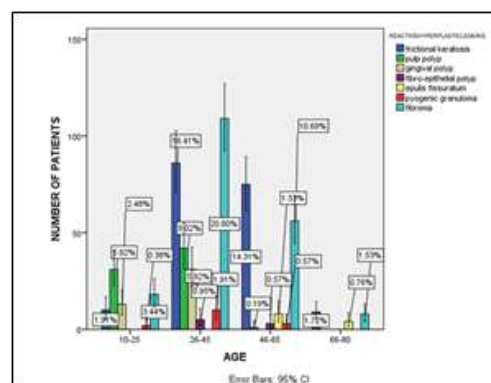


Figure 4. Bar Graph Depicts the Association between the Age and the Types of Reactive Oral Lesions. X axis represents the Age and the Y axis represents the Total Number of Patients. Chi Square Analysis reveals that the Association between the Variables is Statistically Significant ($p < 0.05$). The Highest Occuring Lesion is Fibroma and is Found Maximum in the 26 - 45 Age Group. This is followed by Frictional Keratosis and Pulp Polyp.

CONCLUSION

In the present study a slight male predilection was found and the middle aged people were commonly affected by the lesions and fibroma and frictional keratosis were found to be the commonest oral reactive hyperplastic lesions. It can be concluded that most patients neglect such oral lesions which are commonly due to persistent chronic irritation given from the teeth. More awareness about these lesions is needed in order to curtail the rising number of oral reactive hyperplastic lesions.

REFERENCES

- Buchner A, Shnaiderman-Shapiro A, Vered M. Relative frequency of localized reactive hyperplastic lesions of the gingiva: a retrospective study of 1675 cases from Israel. J Oral Pathol Med 2010;39:631-638.

2. Neville BW, Damm DD, Allen CM, et al. Soft Tissue Tumors. Color Atlas of Oral and Maxillofacial Diseases 2019;299–347.
3. Reddy V, Saxena S, Saxena S, et al. Reactive hyperplastic lesions of the oral cavity: A ten year observational study on North Indian Population. J Clin Exp Dent 2012;136–140.
4. Kamal R, Dahiya P, Puri A. Oral pyogenic granuloma: Various concepts of etiopathogenesis. J Oral Maxillofac Pathol 2012;16:79.
5. Sharma S, Chandra S, Gupta S, et al. Heterogeneous conceptualization of etiopathogenesis: Oral pyogenic granuloma. Natl j maxillofac surg 2019;10:3.
6. Khaitan T, Sinha R, Sarkar S, et al. Conservative approach in the management of oral pyogenic granuloma by sclerotherapy. J Indian Acad Dent Spec Res 2018;30:46.
7. Kashyap B, Reddy P, Nalini P. Reactive lesions of oral cavity: A survey of 100 cases in Eluru, West Godavari district. Contemp Clin Dent 2012;3:294.
8. Patil S, Somashekar S, Wadhawan R, et al. Prevalence of reactive hyperplastic lesions of the gingiva in the Western Indian population. J Orofac Sci 2014;6: 41.
9. Wal JE van der, Van der Wal JE. Frictional Keratosis. Encyclo of Soil Sci 2016;173–174.
10. Metwally A. Prevalence of Reactive lesions of the Oral Cavity in Educational Hospitals and Institutions in Cairo (Cross Sectional Study) v1. Protocols. io. Infect Agent Cancer 11(6).
11. Müller S. Frictional Keratosis, Contact Keratosis and Smokeless Tobacco Keratosis: Features of Reactive White Lesions of the Oral Mucosa. Head Neck Pathol 2019;13:16–24.
12. Woo S-B, Lin D. Morsicatio Mucosae Oris A Chronic Oral Frictional Keratosis, Not a Leukoplakia. J Oral Maxillofac Surg 2009;67:140–146.
13. Musayev JS, Gormez M, Hasanov AB, et al. general profile of the gingival lesions presented by epulis: an analysis of 90 cases. Oral Surg Oral Med Oral Pathol Oral Radiol 2021;132:e31.
14. Mozafari PM, Dalirsani Z, Delavarian Z, et al. Prevalence of oral mucosal lesions in institutionalized elderly people in Mashhad, Northeast Iran. Gerodontology. 2012;29:e930–934.
15. Migliorati C, Panagakos F. Diagnosis and Management of Oral Lesions and Conditions: A Resource Handbook for the Clinician. BoD – Books on Demand 2014;152.
16. Jayasree R, Kumar PS, Saravanan A, et al. Sequestration of toxic Pb(II) ions using ultrasonic modified agro waste: Adsorption mechanism and modelling study. Chemosphere 2021;285:131502.
17. Sivakumar A, Nalabothu P, Thanh HN, et al. A Comparison of Craniofacial Characteristics between Two Different Adult Populations with Class II Malocclusion-A Cross-Sectional Retrospective Study. Biology 2021;10(5).
18. Uma Maheswari TN, Nivedhitha MS, Ramani P. Expression profile of salivary micro RNA-21 and 31 in oral potentially malignant disorders. Braz Oral Res 2020;34:e002.
19. Avinash CKA, Tejasvi MLA, Maragathavalli G, et al. Impact of ERCC1 gene polymorphisms on response to cisplatin based therapy in oral squamous cell carcinoma (OSCC) patients. Indian J Pathol Microbiol 2020; 63:538.
20. Chaitanya NC, Muthukrishnan A, Rao KP, et al. Oral Mucositis Severity Assessment by Supplementation of High Dose Ascorbic Acid During Chemo and / or Radiotherapy of Oro-Pharyngeal Cancers--A Pilot Project. Indian J Pharm Educ 2018;52(3):532–539.
21. Gudipani RK, Alam MK, Patil SR, et al. Measurement of the Maximum Occlusal Bite Force and its Relation to the Caries Spectrum of First Permanent Molars in Early Permanent Dentition. J Clin Pediatr Dent 2020;44(6):423–8.
22. Chaturvedula BB, Muthukrishnan A, Bhuvanaraghan A, et al. Dens invaginatus: a review and orthodontic implications. Br Dent J 2021;230(6):345–50.
23. Patil SR, Maragathavalli G, Ramesh DNS, et al. Assessment of Maximum Bite Force in Pre-Treatment and Post Treatment Patients of Oral Submucous Fibrosis: A Prospective Clinical Study. J Hard Tissue Biol 2021;30:211–216.
24. Ezhilarasan D, Apoorva VS, Ashok Vardhan N. Syzygium cumini extract induced reactive oxygen species-mediated apoptosis in human oral squamous carcinoma cells. J Oral Pathol Med 2019;48(2):115–21.

25. Sharma P, Mehta M, Dhanjal DS, et al. Emerging trends in the novel drug delivery approaches for the treatment of lung cancer. *Chem Biol Interact* 2019;309:108720.
26. Perumalsamy H, Sankarapandian K, Veerappan K, et al. In silico and in vitro analysis of coumarin derivative induced anticancer effects by undergoing intrinsic pathway mediated apoptosis in human stomach cancer. *Phytomedicine* 2018;46:119–30.
27. Rajeshkumar S, Menon S, Venkat Kumar S, et al. Antibacterial and antioxidant potential of biosynthesized copper nanoparticles mediated through *Cissus arnotiana* plant extract. *J Photochem Photobiol B* 2019;197:111531.
28. Mehta M, Dhanjal DS, Paudel KR, et al. Cellular signalling pathways mediating the pathogenesis of chronic inflammatory respiratory diseases: an update. *Inflammopharmacology* 2020;28(4):795–817.
29. Rajakumari R, Volova T, Oluwafemi OS, et al. Nano formulated proanthocyanidins as an effective wound healing component. *Mater Sci Eng C Mater Biol Appl* 2020;106:110056.
30. PradeepKumar AR, Shemesh H, Nivedhitha MS, et al. Diagnosis of Vertical Root Fractures by Cone-beam Computed Tomography in Root-filled Teeth with Confirmation by Direct Visualization: A Systematic Review and Meta-Analysis. *J Endod* 2021;47(8):1198–214.
31. R H, Ramani P, Tilakaratne WM, et al. Critical appraisal of different triggering pathways for the pathobiology of pemphigus vulgaris-A review. *Oral Dis* 2021.
32. Ezhilarasan D, Lakshmi T, Subha M, et al. The ambiguous role of sirtuins in head and neck squamous cell carcinoma. *Oral Dis* 2021.
33. Sarode SC, Gondivkar S, Sarode GS, et al. Hybrid oral potentially malignant disorder: A neglected fact in oral submucous fibrosis. *Oral Oncol* 2021;105390.
34. Kavarthapu A, Gurumoorthy K. Linking chronic periodontitis and oral cancer: A review. *Oral Oncol* 2021;105375.
35. Preethi KA, Lakshmanan G, Sekar D. Antagomir technology in the treatment of different types of cancer. *Epigenomics* 2021;13(7):481–484.
36. Kadeh H, Saravani S, Tajik M. Reactive hyperplastic lesions of the oral cavity. *Iran J Otorhinolaryngol* 2015;27(79):137–144.
37. Sangle V, Pooja VK, Holani A, et al. Reactive hyperplastic lesions of the oral cavity: A retrospective survey study and literature review. *Indian J Dent Res* 2018;29:61.