

## RADIOFREQUENCY ABLATION OF VARICOSE VEINS LARGE SERIES FROM A SINGLE CENTRE

K. P. Haridas<sup>1</sup>, Visakh Prasad<sup>2</sup>

### HOW TO CITE THIS ARTICLE:

K. P. Haridas, Visakh Prasad. "Radiofrequency Ablation of Varicose Veins Large Series from a Single Centre". Journal of Evidence based Medicine and Healthcare; Volume 2, Issue 09, March 02, 2015; Page: 1148-1154.

**ABSTRACT: INTRODUCTION:** Even though radiofrequency ablation (RFA) is accepted as the first choice in treatment of varicose veins due to great sapheno femoral insufficiency, this treatment modality has not gained popularity in India. We present our experience with a large case series, involving more than a thousand RFAs. **METHODS:** Symptomatic varicose vein patients presenting to surgery OPD, who met the Doppler ultrasonography (USG) criteria for suitability for RFA, were offered RFA instead of open surgery. Radiofrequency ablation of varicose vein was done using the radiofrequency generator and segmental ablation catheter, under USG guidance. **RESULTS:** Patients who underwent RFA were followed up by check Doppler at 21 days and at 90 days. Out of a total of 1288 RFAs, technical success at 90 days was 99%. Factors affecting technical success were highlighted. Complications were minor and negligible. Modification of the technique to prevent some of the complications were carried out. **CONCLUSION:** This study, one of the largest series ever, has demonstrated that RFA is a safe and effective treatment and an alternate for surgery.

**KEYWORDS:** Radiofrequency ablation; Varicosevein; Saphenofemoral incompetence.

**INTRODUCTION:** Varicose vein is a common clinical problem, estimated to affect 15% of men and 25% of women globally.<sup>(1)</sup> Varicose veins has the maximum prevalence when compared to other symptomatic vascular diseases including coronary artery disease or stroke.<sup>(2)</sup> Although majority cases are asymptomatic, patients present for treating heaviness of legs, aching, itching, oedema and ulceration and sometimes for cosmetic reasons.<sup>(3)</sup> The traditional procedure of ligation and stripping of the involved vein, practiced for over 100 years, is associated with prolonged recovery, pain and morbidity with a significant recurrence rate.<sup>(4,5,6)</sup> To tackle these problems, minimally invasive techniques like radiofrequency ablation (RFA) and endovenous laser ablation (EVLA) have been developed in recent years, of which, RFA has become the most common approach to venous reflux disease worldwide.<sup>(7)</sup> This treatment modality however, has not gained popularity in India due to lack of awareness and experience among physicians and patients.

In RFA, a catheter is introduced in the dilated veins with an electrode extending from the tip. A generator delivers the radiofrequency energy necessary to keep the vein wall heated to 85-120°C.<sup>(8)</sup> The catheter contains a feedback mechanism that evaluates vein wall impedance and adjusts the energy delivered to keep the temperature at a set target. Heat causes collagen denaturation and shrinkage and complete obliteration of vessel wall.<sup>(9)</sup> The first catheter used for RFA was the VNUS closure system (VNUS Medical Technologies Inc., San Jose CA,USA) It requires a continuous pull back technique and is the catheter used in most published papers.<sup>(10)</sup>

# ORIGINAL ARTICLE

---

In 2006, VNUS introduced the Closure Fast segmental ablation catheter. The new catheter allows RFA of a 7cm segment of superficial vein in 20 seconds without continuous pull back. The advantage is a faster and more consistent ablation.<sup>(11)</sup>

**METHODS:** This is a retrospective review of prospectively collected data of a large case series involving more than thousand RFA by segmental ablation catheter, over a period of five years, in a single hospital in the South Indian city of Trivandrum.

Multidisciplinary team approach was adopted, which included surgeon, radiologist, anesthesiologist and nurse. Surgeon had forty years of experience in surgery, including minimal access surgery and radiologist had ten years' experience in duplex vascular imaging.

## **INCLUSION CRITERIA:**

- Symptomatic varicose vein patients presenting to surgery OPD.
- Doppler evidence of great saphenofemoral or short saphenopopliteal incompetence.
- Patients were offered either RFA or open surgery, and those who opted for RFA were included.

## **EXCLUSION CRITERIA:**

- Patients who did not opt for RFA.
- Presence of deep venous thrombosis (DVT).
- Narrow veins, ie, diameter < 3mm.
- Tortuosity, ie, veins not having straight course for at least 15 cm.
- Duplication or bifurcation of vein within 10cm from valve, unless each tributary is straight for 15cm and has a diameter of 3mm or more.

## **EQUIPMENT:**

- Radiofrequency generator (VNUS RFG Plus).
- VNUS Closure FAST segmental ablation catheter. 7F,60cm.(This is different from continuous pull back type, which was used previously, with advantages of greater consistency and increased speed of ablation).

## **DESCRIPTION OF TECHNIQUE:**

- 1. Pre-operative planning and consent:** This involves review of Doppler findings with special emphasis on presence of reflux, lumen diameter, length of straight segment and presence of bifurcation or tributaries. Presence of perforator in thigh was sought for, in which case, entry had to be below the perforator.
- 2. Anaesthesia:** Spinal (preferred) or monitored anaesthesia care or sedation with femoral block, if spinal was not possible.
- 3. Patient positioning:** Supine for saphenofemoral junction (SFJ) and semiprone for shortsaphenopopliteal junction (SPJ).Limb was elevated, vein was emptied and compression bandaged below entry level.

## ORIGINAL ARTICLE

---

- 4. Cannulation of vein to be treated:** Superficial vein cannulated with 7F sheath using Seldinger technique under USG guidance(Figure1).Entry was at lower thigh for SFJ.Below knee puncture was avoided in view of close relation of saphenous nerve.
- 5. Positioning of RF catheter using USG:** No closer than 2cm from valve, to prevent thrombus extension to deep vein(Figure2).
- 6. Perivenous tumescent fluid injection:** This was done whenever vein had a superficial course to prevent heat damage to perivenous tissue and to prevent skin burn.
- 7. RFA:** Vein is ablated in 7cm segments with extrinsic compression using pad. Triple treatment of the most proximal venous segment (near SFJ) and double treatment of subsequent venous segments. Veins were heated to 120°C at 12watts, maintained for 15 seconds, and catheter withdrawn, when temperature became <70°C. Continuous USG guidance was done to verify patency and compression. This cycle was continued till the entire planned segment was ablated.
- 8. Post op management:** Compression bandage was given. Single dose of low molecular weight heparin was given. Patient was mobilised within three hours and discharged the next day.
- 9. Follow up:** Above knee compression stockings was given for 3 weeks. Clinical and Doppler follow up was done at 21 days and at 90 days, to verify the occlusion of refluxing vein(Figure3) and to rule out deep venous thrombosis (DVT).

In cases of duplex GSV, dual entry RFA was done if both tributaries met the criteria for RFA, ie, adequate diameter and length of straight segment.

Outcome was determined based on occlusion of great saphenous vein on Doppler ultrasonography done at follow up at 21 days and at 90 days.

**RESULTS:** Total of 1288 radiofrequency ablations (1068 patients) were done in a five year period. 220(21%) were bilateral RFA (Table 1). 24 cases (2%) were short saphenous vein ablation and the rest great saphenous vein (Table 2). In 12 cases of duplex GSV, dual entry RFA was done as both tributaries met the criteria for RFA – ie, adequate diameter and length of straight segment. Venepuncture was difficult in one patient (0.1%) and RFA was abandoned.

Out of the 1288 radiofrequency ablations (1068 patients), 1215 results of early (21 days) post-operative check Doppler study were available (94% compliance). There were no recanalization in any of the ablated segments. At 90 days, 1034 patients turned out for check Doppler (80% compliance). There were 9 (1%) cases of recanalization (Table 3). In three (0.3%) of these patients, only one segment (7cm) could be ablated due to difficulty in venous access. Two cases (0.2%) had incompetent lower thigh perforators, which were inadequately covered during RFA, and showed reflux through these perforators to great saphenous vein. Of the remaining four cases of recanalization (0.4%), one was duplex GSV, in which, dual entry ablation was attempted, but one tributary showed recanalisation. In the remaining three (0.3%) cases, the exact cause of recanalisation, or whether a new tributary was formed, could not be determined.

# ORIGINAL ARTICLE

---

Two of the failed patients opted for open surgery. In one patient with mid-thigh perforator, repeat RFA was done, covering the perforator entry, and remained occluded at 90 days follow up.

One patient (0.1%) developed DVT, which was treated with heparin and warfarin, and patient recovered subsequently. 140 Patients (11%) had minor thrombophlebitis at 21 days follow up, all of which, improved subsequently (Table4). One patient (0.1%) suffered skin burn, due to very superficial course of GSV. In later cases, this was prevented by using cold compress, whenever vein to be treated was very superficial. One patient (0.1%) had paraesthesia, due to saphenous nerve involvement. In later cases, ablation was stopped above knee, and, this problem never occurred.

Perforator incompetence was present in pre-operative Doppler evaluation in 842 patients (81%). Concurrent perforator ligation or sclerotherapy was done in 235 of these patients (18%), mainly due to non-healing ulcers.

**DISCUSSION:** The present study is the largest in terms of number of radio frequency ablations, using the segmental ablation technique. Merchant et al<sup>(12)</sup> reported the largest series of patients undergoing RFA. They followed 1006 patients (1222 limbs) upto five years and reported occlusion rate of 87.2% at the end of the follow up period. In this series RFA was done using the continuous pull back technique. In this study, we combined dedicated pre-operative planning, multidisciplinary team approach and the best available technique (segmental ablation).The 99% technical success compares favourably with other studies, as well as with other treatment options like endovascular laser treatment and surgery.<sup>(13-15)</sup> Complications were minor and negligible and less compared to other studies.<sup>(16,17)</sup> This study has highlighted factors affecting technical success (too short straight segment, duplex GSV, and presence of lower thigh perforators which could not be covered adequately). Modification of the technique to prevent some complications (skin burns and paraesthesia) were also successfully carried out.

One of the limitations of the present study was lack of long term follow up.

Further studies are required in patients with great saphenous or short saphenous reflux and perforator incompetence to find out the effect of great saphenous vein(GSV)/short saphenous vein(SSV) ablation, with regard to perforators. This is necessary to determine optimal treatment for patients with GSV and perforator incompetence, i.e., whether concurrent or deferred treatment of perforators is recommended.

**CONCLUSION:** Radiofrequency ablation of varicose veins is a safe and effective treatment and an alternative to surgical procedures and should be offered as the primary treatment in varicose veins due to great saphenofemoral or short saphenopopliteal incompetence.

## REFERENCES:

1. Callam M J. Epidemiology of varicose veins.Br J Surg.Feb1994; 81(2): 167-73.
2. Brand FN, Dennenberg AL, Abbot RD, Kennel WB. The epidemiology of varicose veins: The Framingham study. Am J Prev Med 1998 Mar-Apr; 4(2): 96-101.

# ORIGINAL ARTICLE

3. O'Shaunessy M, Rahall E, Walsh TN et al. Surgery in the treatment of varicose veins. *Ir Med J* 1989; 82(2); 54-5.
4. Perkins JM. Standard varicose vein surgery. *Phlebology* 2009; 24 (Suppl 1): 34-41.
5. Lees TA, Beard JD, Ridler BM et al. A survey of the current management of varicose veins by members of the Vascular Surgical society. *Ann R CollSurgEngl* 1999; 81 (6): 407-17.
6. Jones L, Braithwaite BD, Selwyn D et al. Neovascularisation is the principal cause of varicose vein recurrence: results of a randomised trial of stripping the long saphenous vein. *Eur J VascEndovascSurg* 1996; 12(4): 442-5.
7. Bergan JJ. Endovenous saphenous vein obliteration. In: Whitmore AD, Bandik DF, Editors. *Advances in vascular surgery*, Vol 9. Chicago Mosby-Year Book; 2001.p 123-32.
8. George Geroulakos, Baver Sumpio, Editors. In: *Vascular surgery: Cases, Questions and Commentaries*. Third edition Springer Verlag London 2011.p 498.
9. Schmedt CG, Sroka R, Sleckmeier s, et al. Investigation on radiofrequency and laser (980nm) effects after endoluminal treatment of saphenous vein insufficiency in an ex-vivo model. *Vasc Endovasc Surg* 2004; 38: 167-174.
10. Health Quality Ontario. Endovascular radiofrequency ablation for varicose veins: an evidence based analysis. *Ont Health Technol Assess Ser* 2011; 11(1): 1-93. Epub 2011 Feb 1.
11. Gohel MS, Davies AH. Radiofrequency ablation for uncomplicated varicose veins. *Phlebology* 2009; 24(Suppl 1): 42-49.
12. Merchant RF, Pichot O. Closure study group. Long term outcomes of endovenous radiofrequency obliteration of saphenous reflux as a treatment for superficial venous insufficiency. *J VascSurg* 2005; 42(3): 502-509.
13. Helmy El Kaffas K, ElKashif O, ElBaz W. Great saphenous vein radiofrequency ablation versus standard stripping in the management of primary varicose veins- a randomized clinical trial. *Angiology*. Jan 2011; 62(1): 49-54.
14. Leopardi D, Haggart B L, Fitridge R A, Woodruff P W, Maddeson G J. Systematic review of treatments for varicose veins. *Ann Vasc Surg* Mar 2009; 23(2): 264-76.
15. Almeida J I, Kaufman J, Gockeritz O et al. Radiofrequency endovenous Closure FAST versus laser ablation for the treatment of great saphenous reflux: a multicenter single blinded randomized study (RECOVERY study). *J Vasc Interv Radiol* 2009; 20(60): 752-759.
16. Marsh P, Price B A, Holdstock J, Harrison C, Whiteley M S. Deep vein thrombosis (DVT) after venous thrombo ablation techniques: rates of endovenous heat induced thrombosis (EHIT) and classical DVT after radiofrequency and endovenous laser ablation in a single centre. *Eur J Vasc Endovasc Surg* 2010; 40(4): 521-527.
17. Proebstle T et al. Three year European follow up of endovenous radiofrequency powered segmental thermal ablation of great saphenous vein with or without treatment of calf varicosities. *JVS*; July 2011.

Side	Number (n-1068)
Unilateral	848 (79%)
Bilateral	220 (21%)

**Table 1: Study characteristics-1**

# ORIGINAL ARTICLE

Segment	Number (n-1288)
SFJ	1264 ((98%)
SPJ	24 (2%)

Table 2: Study characteristics-2

Technical success	Percentage
At 21 days	100%
At 90 days	99%

Table 3: Results

Side effect	Percentage
DVT	0.1%
Minor thrombophlebitis	11%
Skin burn	0.1%
Paraesthesia	0.1%

Table 4: Complications

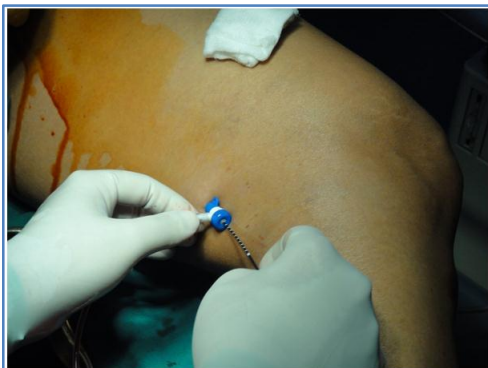


Fig. 1: Introducing RFA catheter into great saphenous vein

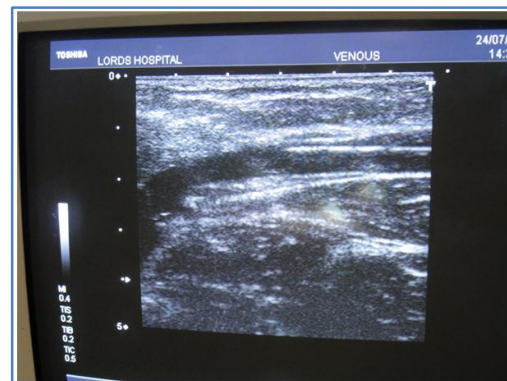
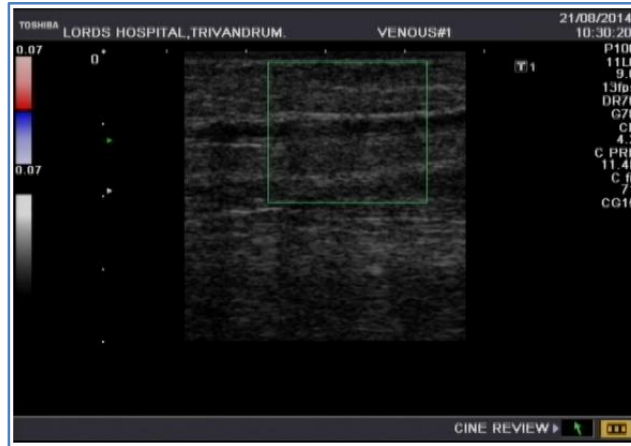


Fig. 2: Catheter tip positioned 2.5cm from saphenofemoral junction for RFA

# ORIGINAL ARTICLE



**Fig. 3: Post RFA check Doppler showing absence of flow in the occluded great saphenous vein**

## **AUTHORS:**

1. K. P. Haridas
2. Visakh Prasad

## **PARTICULARS OF CONTRIBUTORS:**

1. Consultant Surgeon, Department of Surgery, Lords Hospital, Trivandrum, India.
2. Assistant Professor, Department of Radio-diagnosis, Sree Gokulam Medical College, Trivendrum, India.

## **NAME ADDRESS EMAIL ID OF THE CORRESPONDING AUTHOR:**

Dr. Visakh Prasad,  
Vaisakham,  
SCT Nagar, Thuruvikkal,  
Trivandrum-695011, India.  
E-mail: visakhprasad@gmail.com

Date of Submission: 05/02/2015.  
Date of Peer Review: 06/02/2015.  
Date of Acceptance: 11/02/2015.  
Date of Publishing: 24/02/2015.