CASE REPORT

PROTEIN S DEFICIENCY WITH PORTAL VEIN THROMBOSIS: A CASE REPORT

Kekathi Vidyasagar[1], S. M. Saifullah Quraishi[2], Ravi Theja[3], Chandrashekar S[4]

HOW TO CITE THIS ARTICLE:
Kekathi Vidyasagar, S. M. Saifullah Quraishi, Ravi Theja, Chandrashekar S. "Protein S Deficiency with Portal Vein Thrombosis: A Case Report". Journal of Evidence based Medicine and Healthcare; Volume 1, Issue 11, November 17, 2014; Page: 1383-1386.

ABSTRACT: Portal vein thrombosis is a rare cause of portal hypertension associated mainly with cirrhosis, thrombophilia and malignancy. In young patient search of risk factor and underlying etiology can change the management and prognosis. Specific recommendations for anticoagulation are not well defined, this highlights the importance of weighting the individual risk and benefits in the treatment of patients with thrombophilia
KEYWORDS: Portal hypertension, thrombophilia, oesophageal varices, splenomegaly.

CASE REPORT: A 17 years old female presented with black tarry stools since three days. She also had similar complaints at age of seven years. On examination moderate spleenomegaly was present, patient ultrasound revealed spleenomegaly with portal hypertension. She was investigated through multiple blood test mainly full blood counts, inflammatory marker, INR, serum copper as well as cerulopalasmin level. An auto immune screen, viral screen, serum protein electrophoresis were negative. Coagulation profile suggested protein S deficiency. CT abdomen [figure-1] shows portal vein thrombosis with spleenic vein dilatation.

DISCUSSION: Portal vein thrombosis can be divided in two categories acute and chronic but most of the time the division is arbitrary because clinical feature of PVT are subtle. There is no definite time frame to call acute or chronic but some studies suggest that more than 60 days old PVT is considered as chronic PVT.[1] In this patient she is having portal hypertension suggestive of chronic PVT.

Acute PVT commonly presents with fever, abdominal pain, nausea, ascites but mostly severity depends on mesenteric venous thrombosis.[2] In 10% of PVT patient will have bowel ischemia because extension of thrombus in mesenteric vein.[3] If patient has absence of clinical radiological or endoscopy feature of portal hypertension, PVT is considered acute. In acute PVT incident of sepsis is more than chronic PVT.[4] Natural history of PVT is uncertain some patients have spontaneous resolution and in some patients it can lead to bowel infarction and portal hypertension. In PVT prognosis is poor with bowel infarction.

Chronic PVT commonly present with feature of portal hypertension like upper gastrointestinal bleed and hyperspleenism. A chance of bleeding in PVT with portal hypertension is less than patient with cirrhosis with portal hypertension; it may be because of prothrombotic state. Extrahepatic complications of biliary tree are recognize in 80% of patient with chronic PVT, it is because of portal cavernoma formation.[5,6] Hilar mass can be seen in imaging studies, which compromise of lash of collateral vessels and inflammatory tissue.[7] Hematobilia can occur spontaneously or after ERCP.[8] PVT treatment is done with two main intention 1) to reverse or

prevent progression of thrombosis 2) to treat complication of PVT mainly gastro intestinal varies bleed or billary complications. Thrombolytic are effective in acute PVT sooner the treatment is given better the outcome [recanalization and improvement in clinical parameter]. Effectiveness of thrombolysis decrease when it is used after 14 days.[9] Anticoagulants is safe in PVT to prevent progression of thrombosis it can be given after doing prophylactic varices banding or sclerotherapy.[10] In our patient local abdominal causes of thrombosis were absent. Thrombophilic profile confirms protein S deficiency. Now patient is receiving anticoagulant after variceal banding.

In PVT bile duct abnormality prevalence is high but intervention only indicated when there is billary obstruction. Surgical treatment of stricture [Hepatico-jejunostomy] is associated with high mobidity and mortality because of collateral around porta hepatis.[11] Decreasing portal pressure by surgical decompression or TIPSS decreases biliary stricture by decreasing choledochal varices.[12] Endoscopic therapy is treatment of choice in billary stricture but high incidence of bleeding reported in balloon inflation and stunt removal.[13]

CONCLUSION: Extrahepatic PVT understanding has improved in recent few years .Meticulous search of inherited and acquired thrombophilic cause can influence the management. Recent data has suggested that anticoagulant can be given safely after taking care of oesophageal varices, particularly in those at risk of thrombus extension, as mesenteric infarction is an important cause of death.

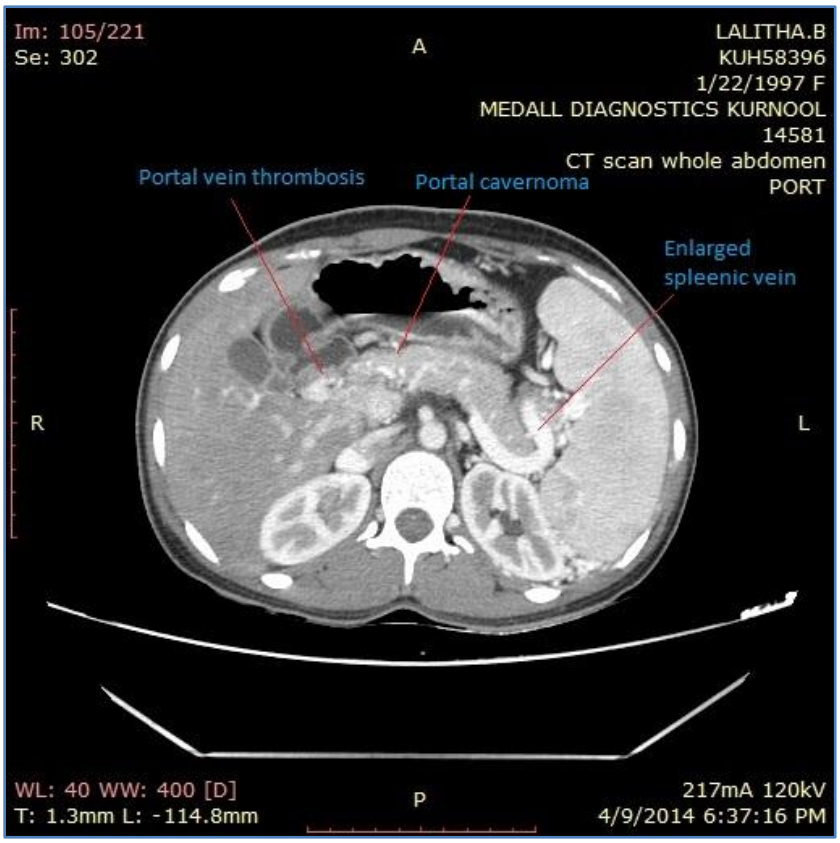

REFERENCES:

1. Malkowski P, Pawlak J, Michalowicz B, et al. Thrombolytic treatment of portal thrombosis. Hepatogastroenterology 2003; 50: 2098–100.
2. Gertsch P, Matthews J, Lerut J, Luder P, Blumgart LH. Acute thrombosis of the splanchnic veins. Arch Surg 1993; 128: 341–5.
3. Kairaluoma MI, Karkola P, Heikkinen D, Huttunen R, Mokka RE, Larmi TK. Mesenteric infarction. Am J Surg 1977; 133: 188–93.
4. Condat B, Pessione F, Helene Denninger M, Hillaire S, Valla D. Recent portal or mesenteric venous thrombosis: increased recognition and frequent recanalization on anticoagulant therapy. Hepatology 2000; 32: 466–70.
5. Khuroo MS, Yattoo GN, Zargar SA, et al. Biliary abnormalities associated with extrahepatic portal venous obstruction. Hepatology 1993; 17: 807–13.
6. Condat B, Vilgrain V, Asselah T, et al. Portal cavernoma associated cholangiopathy: a clinical and MR cholangiography coupled with MR portography imaging study. Hepatology 2003; 37: 1302–8.
7. Bechtelsheimer H, Conrad A. Morphology of cavernous transformation of the portal vein (author's translation). Leber Magen Darm 1980; 10: 99–106.
8. Mutignani M, Shah SK, Bruni A, Perri V, Costamagna G. Endoscopic treatment of extrahepatic bile duct strictures in patients with portal biliopathy carries a high risk of haemobilia: report of 3 cases. Dig Liver Dis 2002; 34: 587–91.
9. Malkowski P, Pawlak J, Michalowicz B, et al. Thrombolytic treatment of portal thrombosis. Hepatogastroenterology 2003; 50: 2098–100.
10. Condat B, Pessione F, Hillaire S, et al. Current outcome of portal vein thrombosis in adults: risk and benefit of anticoagulant therapy. Gastroenterology 2001; 120: 490–7.
11. Chaudhary A, Dhar P, Sarin SK, et al. Bile duct obstruction due to portal biliopathy in extrahepatic portal hypertension: surgical management. Br J Surg 1998; 85: 326–9.
12. Gorgul A, Kayhan B, Dogan I, Unal S. Disappearance of the pseudo-cholangiocarcinoma sign after TIPSS. Am J Gastroenterol 1996; 91: 150–4.
13. Sezgin O, Oguz D, Altintas E, Saritas U, Sahin B. Endoscopic management of biliary obstruction caused by cavernous transformation of the portal vein. Gastrointest Endosc 2003; 58: 602–8.

CASE REPORT

AUTHORS:

1. Kekathi Vidyasagar
2. S. M. Saifullah Quraishi
3. Ravi Theja
4. Chandrashekar S.

PARTICULARS OF CONTRIBUTORS:

1. Associate Professor, Department of Medicine, Kurnool Medical College, Kurnool.
2. Assistant Professor, Department of Medicine, Kurnool Medical College, Kurnool.
3. Post Graduate Student, Department of Medicine, Kurnool Medical College, Kurnool.
4. Professor, Department of Medicine, Kurnool Medical College, Kurnool.

NAME ADDRESS EMAIL ID OF THE CORRESPONDING AUTHOR:

Dr. S. M. Saifullah Quraishi,
Assistant Professor,
Department of Medicine,
Kurnool Medical College, Kurnool.
E-mail: safu53@yahoo.co.in

Date of Submission: 10/10/2014.
Date of Peer Review: 11/10/2014.
Date of Acceptance: 25/10/2014.
Date of Publishing: 12/11/2014.