

## PROSPECTIVE STUDY OF AETIOLOGY AND CLINICAL PRESENTATION OF RUBEOSIS IRIDIS IN A TERTIARY EYE CARE CENTRE IN SOUTH INDIA

Latha Hariharan<sup>1</sup>, Shalini S<sup>2</sup>

<sup>1</sup>Professor, Department of Ophthalmology, Regional Institute of Ophthalmology and Government Ophthalmic Hospital, Chennai.

<sup>2</sup>Third Year Postgraduate Student, Department of Ophthalmology, Regional Institute of Ophthalmology and Government Ophthalmic Hospital, Chennai.

### ABSTRACT

#### BACKGROUND

The aim of the study is to analyse the aetiology and clinical presentation of rubeosis iridis in a tertiary eye care centre.

#### MATERIALS AND METHODS

It was an analytical prospective study. About 50 patients were studied at our institution for six months. The aetiology and the clinical profile of the patients with rubeosis iridis was studied. Inclusion criteria was patients with comorbid conditions like diabetes and hypertension were included in this study. Patients with preexisting glaucoma either primary open angle or angle closure glaucoma and patients who had received more than three sittings of pan-retinal photocoagulation were excluded in this study. The initial presenting complaints, detailed history of the course of the disease, visual acuity, detailed slit lamp examination, intraocular pressure, detailed fundus examination and gonioscopic grading was done for all the patients.

#### RESULTS

Almost, all the cases had florid rubeosis along the pupillary border. Those extending to the angles presented with an increase in the intraocular pressure. Patients with chronic uveitis, long-standing retinal detachment and vitreous haemorrhage presented with poor vision. Male preponderance was noted in our study. About 70% presented with raised intraocular pressure. Unilateral presentation of rubeosis iridis was noted in the patients presenting with chronic uveitis and long-standing retinal detachment.

#### CONCLUSION

In our study, diabetes topped the aetiology of rubeosis very closely followed by central retinal vein occlusion and hypertension. It was also noted in few cases of chronic uveitis and long-standing retinal detachment. About 70% of the study population presented with neovascular glaucoma.

#### KEYWORDS

Rubeosis Iridis, Diabetic Retinopathy, Thrombotic Glaucoma.

**HOW TO CITE THIS ARTICLE:** Hariharan L, Shalini S. Prospective study of aetiology and clinical presentation of rubeosis iridis in a tertiary eye care centre in South India. J. Evid. Based Med. Healthc. 2017; 4(11), 584-588. DOI: 10.18410/jebmh/2017/114

#### BACKGROUND

The presence of abnormal vessels on the surface of the iris is called rubeosis iridis. All the normal vessels remain behind the scleral spur, which is usually located in the stroma and they have a typical radial arrangement. The new vessels usually cross the scleral spur and reaches the trabecular meshwork and are located on the surface of the iris. The neovascularisation begins as an endothelial budding from the capillaries of the minor arterial circle usually begins at the pupil. These new vessels are very thin walled endothelial cells without a muscular layer or adventitia. There is a lack of supportive tissue. The fibrovascular membrane consists

of proliferation of myofibroblasts, which are clinically transparent.<sup>1</sup> The ischaemia of the anterior segment and the presence of the VEGF in the aqueous due to the ischaemic retina is found to be the main source for the development of neovascularisation of iris. Pupillary border and the angles are involved first due to close contact of aqueous in these regions.<sup>2</sup> This condition is often associated with proliferative diabetic retinopathy. When iris was affected by diabetes, it was called as diabetic iridopathy and was classified into 4 grades.<sup>3</sup>

Grade 0 - No diabetic iridopathy.

Grade 1 - Non-proliferative diabetic iridopathy (dilated pupillary and stromal capillaries with short lasting fluorescence).

Grade 2 - Proliferative diabetic iridopathy (new vessels at pupillary margin and/or stroma filling rapidly with dye and leaking equally promptly and diffusely).

Grade 3 - Neovascular glaucoma.

*Financial or Other, Competing Interest: None.*

*Submission 14-01-2017, Peer Review 21-01-2017,*

*Acceptance 31-01-2017, Published 03-02-2017.*

*Corresponding Author:*

*Dr. Latha Hariharan,*

*#55, A Block, TNHB Flats,*

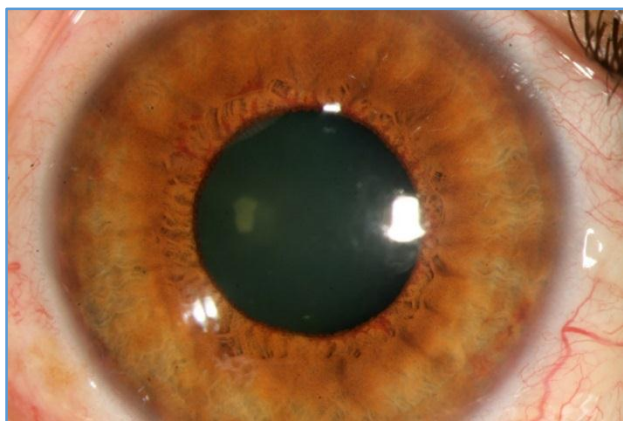*180, Luz Church Road,*

*Mylapore, Chennai-600004.*

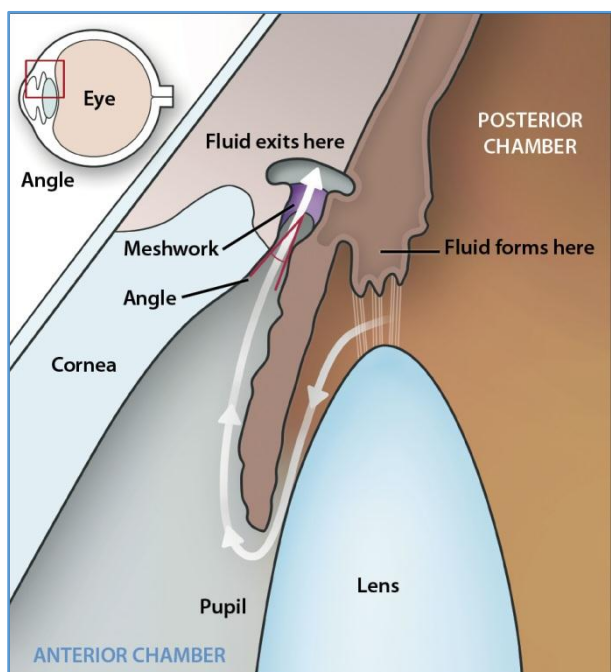
*E-mail: lathavisu1960@outlook.com*

*DOI: 10.18410/jebmh/2017/114*





**Figure 1. Rubeosis Iridis**



**Figure 2. Showing Pathway of Aqueous Outflow Hence Depicting the Common Sites for Rubeosis Iridis**

Other conditions included CRVO, long-standing retinal detachment and chronic uveitis. Coats was the first to note the new vessel in the iris in 1906 in the eyes with central retinal vein occlusion.<sup>4,5</sup> About 40% of the ischaemic central retinal vein occlusion developed neovascularisation of iris and most of them developed neovascular glaucoma also known as thrombotic glaucoma.<sup>6</sup>

#### **Aim and Objective of the Study to-**

1. Study the aetiological profile and clinical presentation of 50 cases of rubeosis in a tertiary eye care centre.
2. Emphasise on the need for the early diagnosis of the condition to prevent various complications.

#### **MATERIALS AND METHODS**

**Inclusion Criteria-** Patients with comorbid conditions like diabetes and hypertension were included in this study.

**Exclusion Criteria-** Preexisting glaucoma either primary open angle or angle closure glaucoma.

Patients who had received more than three sittings of pan-retinal photocoagulation.

#### **Methods and Study Design**

This was a prospective analytical study.

About 50 patients were studied at our institution for 6 months between July 2016 to December 2016. A detailed history, detailed ophthalmic examination was done for all and the various clinical presentations of rubeosis were analysed in this study. The initial presenting complaints, visual acuity, detailed slit lamp examination, intraocular pressure, detailed fundus examination using a slit lamp biomicroscopy with 90 D lens, indirect ophthalmoscopy using a 20 D lens and gonioscopic examination was done for all the patients. 76% of the study population were advised B scan when the media was not clear and all these patients were frequently followed up and during their subsequent visit, visual acuity, IOP, thorough slit lamp examination, slit lamp photograph and the fundus photographs were captured to look for the progression if necessary PRP was given in the same visit. Patients also presented with acute rise in the intraocular pressure ranging between 35-50 mmHg. These patients presented with a congested, painful eye and sudden drop in vision. Measures were taken to control the rise in the intraocular pressure.

The glycaemic status, blood pressure and lipid profile was checked for all the patients during the first visit. These baseline readings were documented and were rechecked during their follow up visits.

Among the 50 patients evaluated, about 22 patients had rubeosis due to PDR, 20 of them with CRVO developed rubeosis. Here, hypertension was found to be the main cause of CRVO. About 5 patients with chronic uveitis in the affected eye developed rubeosis. Three patients with long-standing RD had rubeosis. About 35 patients among them had a rise in the IOP due to neovascular glaucoma. One among three patients with long-standing RD had phthisis bulbi of the affected eye.

In our study, the condition showed a male preponderance.

These patients were frequently followed up every week during the first month and twice a month for the next three months and then monthly follow up thereafter.

#### **RESULTS**

##### **1. Age Distribution**

The range was between 45-65 years including both males and females. Majority of patients belonged to the age group of 50 to 55 years of age. An equal distribution was found between the age groups of 45 to 50 and 56 to 60 years.

Mean age of presentation was  $53.2 \pm 5.6$  years. The youngest patient was 46 years old and the oldest patient was 61 years old (Figure 3).

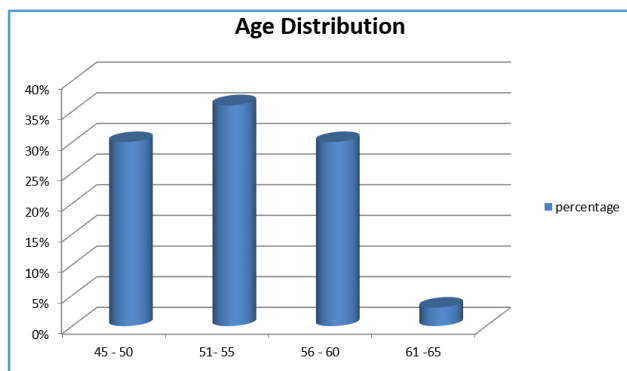


Figure 3. Showing the Age Distribution Pattern

**Sex Distribution**

In this study, there was a slight male preponderance, males accounting for 60% of patients. Majority of them were in 50-55 years age group (Figure 4).

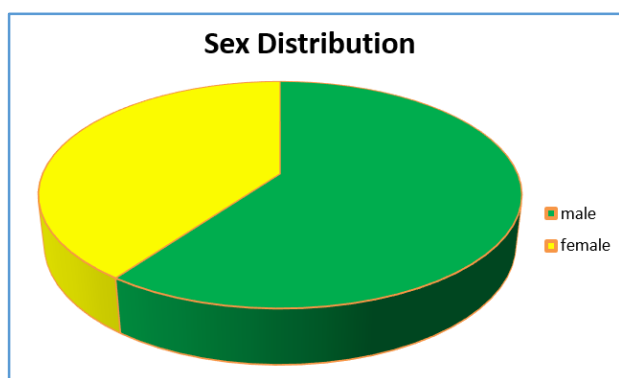


Figure 4. Showing Sex Distribution

**Laterality**

In this study, the incidence of rubeosis iridis was found more in the right eye (Figure 5).

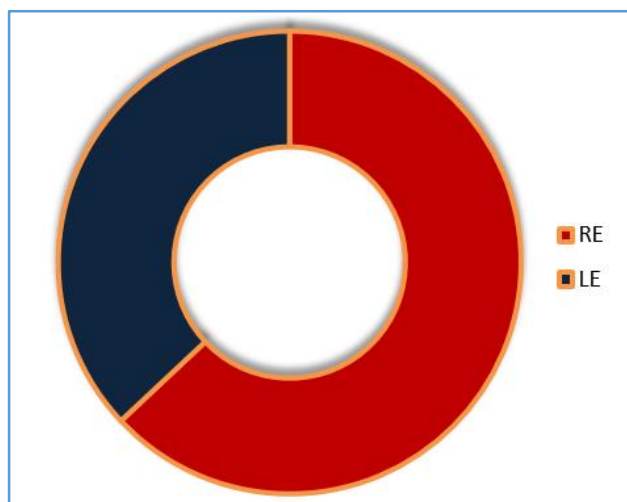


Figure 5. Showing Laterality

**Aetiology**

In our study, diabetes and CRVO were found to be the major cause for rubeosis accounting for 44% and 40%, respectively.

Other causes like chronic uveitis and long-standing RD were also documented. 10% of the study population presented with chronic uveitis and 6% with long-standing retinal detachment with dense proliferative vitreo retinopathy changes (Figure 6).

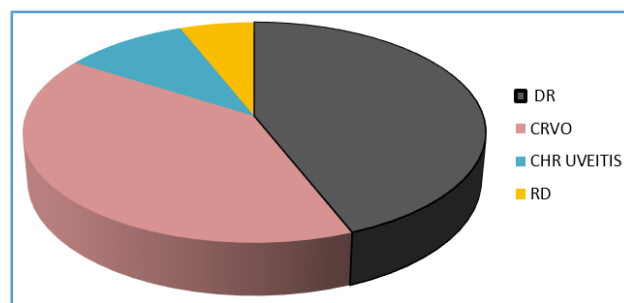


Figure 6. Showing the Aetiological Distribution

**Neovascular Glaucoma**

About 70% of the study population presented with neovascular glaucoma (Figure 7). Appropriate treatment to reduce the high intraocular pressure was considered.

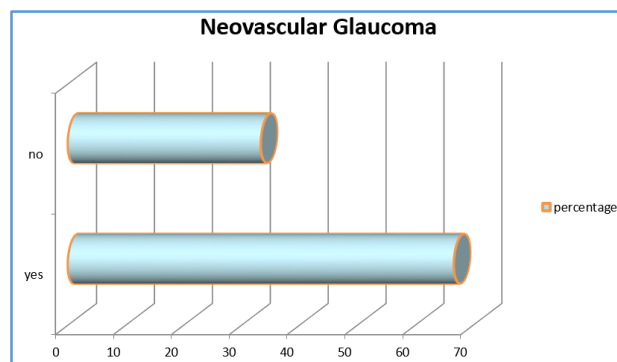


Figure 7. Showing Rise in IOP

**Visual Acuity**

In 46.6% of patients with rubeosis iridis, BCVA was 5/50 - 6/60 NIP. 10% of the patients had BCVA - 1/60 - 2/60 NIP. 23.4% of patients had BCVA of 3/60 - 4/60 NIP. 20% of patients had BCVA - 6/36 - 6/24 (Figure 8).

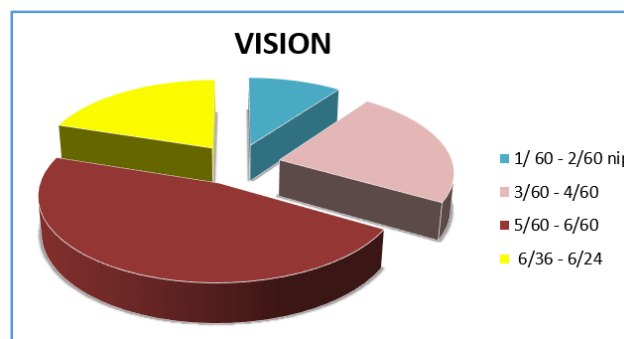


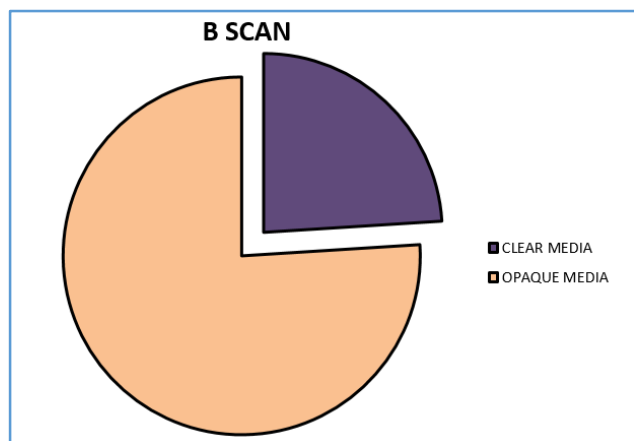
Figure 8. Showing Distribution of Visual Acuity

**B Scan**

All the patients with an opaque media were advised B scan (Figure 9).

In our study, 76% of the population had an opaque media due to cataractous lens, vitreous haemorrhage and

hazy cornea due to chronic uveitis and hence the posterior pathology was ruled out in almost every patient.



**Figure 9. Showing Number of Patients Subjected to B Scan**

## DISCUSSION

Of all the various aetiology causing rubeosis iridis, diabetes mellitus was the most frequently associated systemic condition. 44% of the study population had diabetes. The patients with diabetes had a poor glycaemic control. 60% of the diabetic population were on oral hypoglycaemic drugs. 40% were being treated with injection human insulin. Most of the patients were presented to us for routine follow up. 5% were asymptomatic. 80% of the diabetic population had diabetic retinopathy and were classified into various grades. Salu found the association of diabetic retinopathy with rise in the intraocular pressure for the first time in 1928.<sup>7</sup> Almost, all the patients had associated cataractous lens changes. These patients were also subjected to B scan to look for posterior pathology. 20% of this population had vitreous haemorrhage. 10% had tractional retinal detachment.

It was closely followed by central retinal vein occlusion, which account for 40% of the study population. The cause for central retinal vein occlusion was mostly hypertension. 30% of the patients with CRVO had blood pressure ranging between 180-160/110-90 mmHg, which was similar to previous studies.<sup>8</sup> These patients were on irregular treatment. 15% were diagnosed to be hypertensive at the time of presentation and were started on treatment with antihypertensive drugs. 60% of patients with CRVO had associated cataractous lens changes.

We also encountered patients with chronic uveitis 10% of the total study population presented with features of chronic uveitis. These patients were previously treated with oral and topical steroids. 30% of these patients were also on immune suppressants. All the patients had florid rubeosis iridis. All these patients were advised B scan as media was very hazy due to corneal involvement.

6% of the total study population had long-standing retinal detachment. These patients had a unilateral presentation of loss in the vision. One among them presented to us with phthisis bulbi. All the three patients had developed a sensory adaptation. These patients presented with a divergent squint and loss of vision in the affected eye.

Male preponderance was noted. Right eye was most commonly affected. Unilateral presentation of rubeosis iridis was noted in patients with chronic uveitis and long-standing retinal detachment, which was 16% of the total study population.

Poor visual acuity was due to either cataractous lens changes or the disease entity per se.

70% of the total study population presented with a rise in the intraocular pressure and favoured the diagnosis of neovascular/thrombotic glaucoma. Kruz on gonioscopic examination first found large radially running vessels, which directly entered into the Schlemm's canal.<sup>9</sup>

Challenges encountered while assessing the study population.

1. Most of the patients in the study population had a hazy media due to lens changes. Hence, viewing the fundus was a task in localising the neovascularisation elsewhere.
2. Gonioscopic examination of the patients with hazy cornea as in the cases with chronic uveitis with pannus and patients presenting with an oedematous cornea due to rise in the intraocular pressure. In these patients, angles were not visualised on the day of presentation.
3. The measurement of intraocular pressure by the standard Goldmann applanation tonometry was not possible in hazy corneas. In such patients, the intraocular pressure was measured using Icare tonometry.
4. The awareness about the disease and the condition was poor.
5. The gross loss in visual acuity in 16% of the study population did not correlate with the lens changes. The media was very hazy and difficulty arose while commenting on the posterior retina. Almost, 76% of the study population were advised B scan.

The other diseases and conditions associated with rubeosis iridis should also be kept in mind. These include the following conditions-<sup>10</sup>

1. Ocular Vascular Disease.
  - Central retinal artery occlusion.
  - Branch retinal vein occlusion.
  - Branch retinal artery occlusion.
  - Sturge-Weber syndrome with choroidal haemangioma.
  - Leber's miliary aneurysm.
  - Sickle cell retinopathy.
  - Ocular ischaemic syndrome.
2. Extraocular Disease.
  - Carotid artery disease.
  - Aortic arch syndrome.
  - Caroticocavernous fistula.
3. Ocular Neoplasms.
  - Malignant melanoma.
  - Retinoblastoma.
  - Optic nerve glioma with venous stasis.

- Metastatic carcinoma.
  - Reticulum cell sarcoma.
  - Angiomatosis retinae.
4. Ocular Inflammatory Diseases.
    - Syphilitic retinitis.
    - Sympathetic ophthalmitis.
  5. Ocular Therapy.
    - Vitrectomy (especially in diabetics).
    - Retinal detachment surgery.
    - Radiation.
    - Laser coreoplasty.
  6. Assorted Ocular Diseases.
    - Eales disease.
    - Coat's disease.
    - Retinopathy of prematurity.
    - Persistent hyperplastic primary vitreous.
    - Norrie's disease.
    - Trauma.
    - Stickler's syndrome.
    - Lupus erythematosus.
    - Vitreous wick syndrome.

### CONCLUSION

In our study, diabetes was considered as the most important aetiology of rubeosis iridis followed by central retinal vein occlusion, chronic uveitis and long-standing retinal detachment. An early detection and prompt treatment helps in preventing the dreaded complications like neovascular glaucoma, which usually causes severe damage to the optic nerve and causing a gross loss of vision, which is usually irreversible even with surgical intervention.

Therefore, all the patients should be treated without any delay thereby preventing a painful blind eye.

### REFERENCES

- [1] John T, Sassani JW, Eagle RC Jr. The myofibroblastic component of rubeosis iridis. *Ophthalmology* 1983;90(6):721-728.
- [2] Kanski JJ, Bowling B. *Clinical ophthalmology: a systematic approach*. 7th edn. Philadelphia: Elsevier/Saunders 2011.
- [3] Bandello F, Brancato R, Lattanzio R, et al. Relation between iridopathy and retinopathy in diabetes. *Br J Ophthalmol* 1994;78(7):542-545.
- [4] [http://eyewiki.aao.org/Neovascular\\_Glaucoma](http://eyewiki.aao.org/Neovascular_Glaucoma).
- [5] Laatikainen L, Blach RK. Behaviour of the iris vasculature in central retinal vein occlusion: a fluorescein angiographic study of the vascular response of the retina and the iris. *Br J Ophthalmol* 1977;61(4):272-277.
- [6] <http://www.sciencedirect.com/science/article/pii/S0002939467902498>.
- [7] [http://www.ajo.com/article/0002-9394\(48\)92531](http://www.ajo.com/article/0002-9394(48)92531).
- [8] Hayreh SS, Rojas P, Podhajsky P, et al. Ocular neovascularization with retinal vascular occlusion-III. Incidence of ocular neovascularization with retinal vein occlusion. *Ophthalmology* 1983;90(5):488-506.
- [9] Lisman JV. Rubeosis iridis diabetica. *American Journal of Ophthalmology* 1948;31(8):989-994.
- [10] Gartner S, Henkind P. Neovascularization of the iris (rubeosis iridis). *Surv Ophthalmol* 1978;22(5):291-312.