

# CASE REPORT

## PRIMARY EXTRANODAL NON-HODGKIN'S LYMPHOMA OF LEFT TONSIL: A CASE REPORT

N. Vijayendra Simha<sup>1</sup>, Nitha<sup>2</sup>, Sreenivas N<sup>3</sup>

### HOW TO CITE THIS ARTICLE:

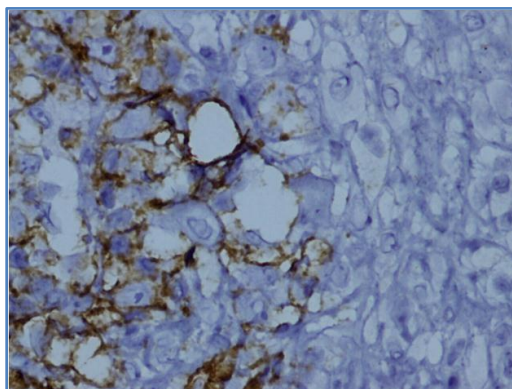
N. Vijayendra Simha, Nitha, Sreenivas N. "Primary Extranodal Non-Hodgkin's Lymphoma of Left Tonsil: A Case Report". Journal of Evidence based Medicine and Healthcare; Volume 1, Issue 12, November 24, 2014; Page: 1484-1488.

**ABSTRACT:** Lymphoma encompasses a complex group of malignancies of the lymphoreticular system. Non-Hodgkins lymphoma of the Waldeyer's ring is a rare entity. Chemoradiation gives a better prognosis. Here a case of unilateral palatine tonsil NHL with B cell lineage has been reported.

**KEYWORDS:** Tonsillar NHL, Lymphoreticular malignancy, Tonsillar asymmetry.

**INTRODUCTION:** Primary localized extranodal non-Hodgkin's lymphoma of head and neck account for 10-20% of all NHL'S. NHL of the Waldeyer's ring is a relatively rare entity. 70% occurs in the palatine tonsils but it accounts for less than 1% of head and neck malignancies.<sup>1, 2, 3</sup> Most lymphomas in palatine tonsils are the B-cell type and diffuse large B cell lymphoma (DLBCL) represents around 67-96%.<sup>4, 5</sup>

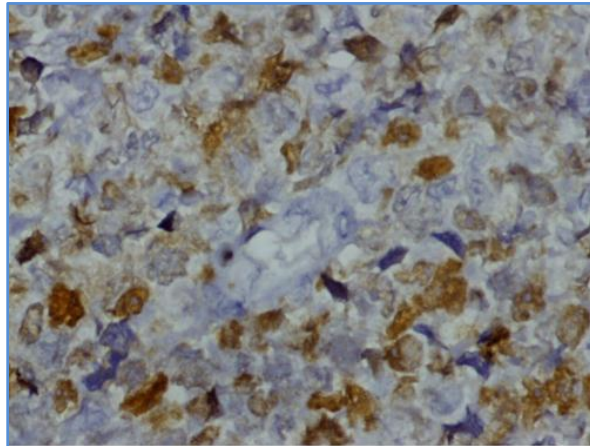
**CASE REPORT:** A 38 year old male presented with 2 episodes of sore throat from one month, insidious in onset and gradually progressive with no aggravating factors but relieved to an extent with medications. There were no constitutional symptoms. On examination, asymmetrical tonsillar hypertrophy was seen with grade 3 on the left and grade 2 on the right. Routine investigations were within normal limits. Tonsillectomy was done with a tentative diagnosis of lymphoma. Histopathological analysis revealed NHL of the tonsil, diffuse large B cell lymphoma (non GCB like). Immunohistochemically neoplastic cells were positive for CD 20 and Mum 1 and negative for CD 10 and bcl 6. Ki-67 proliferation index was about 70%. Reactive T cells were positive for CD3. Patient was treated with chemotherapy and radiotherapy and has been disease free on follow up of 1 year.



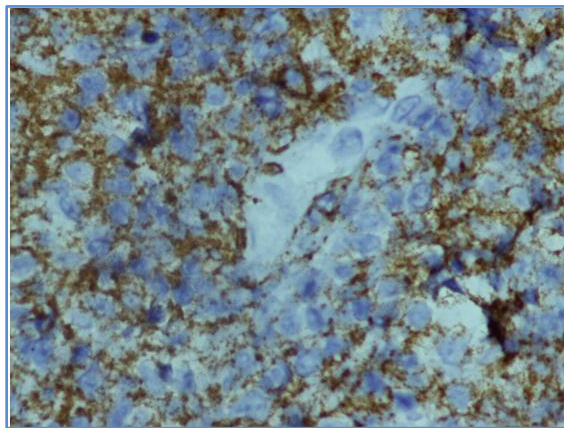
**Fig. 1: Neoplastic cells positive for Mum 1**

# CASE REPORT

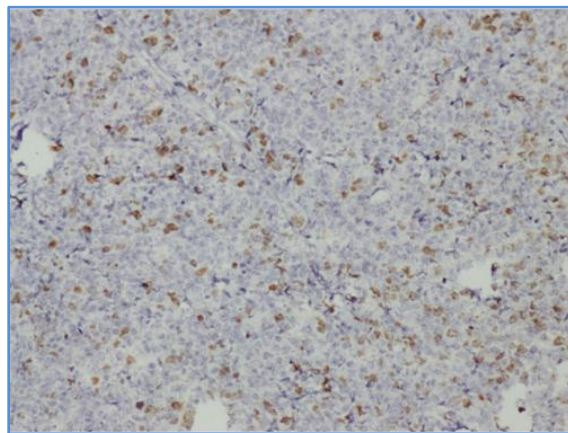
---



**Fig. 2: Neoplastic cells positive for CD20**



**Fig. 3: Neoplastic cells negative for CD 10**



**Fig. 4: Ki-67 – 70% Proliferation index**

# CASE REPORT

---

**CONCLUSION:** Non-Hodgkin's lymphoma rarely involves tonsils with the diffuse large B-cell type being common at this location. A combined treatment consisting of chemotherapy and radiotherapy leads to a satisfactory outcome in patients with this uncommon neoplasm, which tends to present at an early stage and to have a favorable prognosis.

**DISCUSSION:** Non-Hodgkin's lymphomas are a broad heterogeneous category of neoplasms arising in the reticulo endothelial and lymphatic system. It is the second most common neoplasm in the head and neck region after squamous cell carcinoma.<sup>6</sup> The Waldeyer's ring (including tonsil, nasopharynx, and base of tongue) is the most common extranodal site.<sup>7</sup>

Peak incidence is in the 6-7 decades of life with a male predominance.

The vast majority is constituted by the B cell lineage including the diffuse large B-cell lymphoma, follicular lymphoma, mantle cell lymphoma, extranodal marginal zone B-cell of MALT type and less commonly by T -cell lines.<sup>8, 9, 10</sup> Diffuse large B-cell is the most common histologic type and is an aggressive variety.

Symptoms and signs are non-specific and occur as a result of asymmetrical tonsillar enlargement, sensation of fullness in the throat, sore throat, dysphagia, odynophagia, otalgia, cervical adenopathy, tonsillar swelling or snoring. Systemic symptoms, such as fever, weight loss and night sweats are uncommon and may develop in advanced disease.<sup>1</sup>

Only 4 cases of bilateral non-Hodgkin's lymphoma of the tonsils have been reported in the English literature. Early stage disease and small lesions had 5-year survival rates of 65%-85% when compared to bulky lesions(lesions more than 7 cms) especially the tonsils.<sup>11, 12, 13</sup>

Localized non-Hodgkin's lymphomas (NHLs) of the head and neck are treated with chemotherapy or/and combination radiotherapy.<sup>14,15,16</sup> Combined chemoradiation is frequently used as the primary treatment in view of local relapses due to bulky disease and aggressive histology and for complete remission and better survival rates.<sup>17, 18, 19, 20.</sup>

**CONCLUSION:** NHL of the Waldeyer's ring is relatively rare and nothing can substitute a high index of clinical suspicion in the diagnosis of primary tonsillar lymphomas. Combined chemoradiation is highly effective and leads to a satisfactory outcome with favourable prognosis, albeit a high frequency of aggressive histology.

## BIBLIOGRAPHY:

1. Laskar S, Bahl G, Muckaden MA, Nair R, Gupta S, Bakshi A. Primary diffuse large B-cell lymphoma of the tonsil: is a higher radiotherapy dose required? *Cancer* 2007 Aug; 110(4): 816-23.
2. Jacobs C, Weiss L, Hoppe RT. The management of extranodal head and neck lymphomas. *Arch Otolaryngol Head Neck Surg* 1986 Jun; 112(6): 654-8.
3. Yamanaka N, Harabuchi Y, Sambe S, Shido F, Matsuda F, Kataura A. Non-Hodgkin's lymphoma of Waldeyer's ring and nasal cavity. Clinical and immunological aspects. *Cancer* 1985 Aug; 56(4): 768-76.

## CASE REPORT

---

4. Hart S, Horsman JM, Radstone CR, Hancock H, Goepel JR, Hancock BW. Localized extranodal lymphoma of the head and neck: the Sheffield Lymphoma Group experience (1971-2000). *Clin Oncol* 2004 May; 16(3): 186-92.
5. Mohammadianpanah M, Daneshbod Y, Ramzi M, Hamidizadeh N, Dehghani SJ, Bidouei F. Primary tonsillar lymphomas according to the new World Health Organization classification: to report 87 cases and literature review and analysis. *Ann Hematol* 2010 Oct; 89(10): 993-1001.
6. Osuch-Wojcikiewicz E, Rzepakowska A, Bruzgielewicz A, Wieczorek J. Follicular (nodular) non-Hodgkin's lymphoma of tonsil – case report. *Otolaryngol Pol.* 2007; 61(2): 203-6.
7. Depena CA, Van-Tassel P, Lee YY (1990) Lymphoma of the head and neck. *Radiol Clin North Am* 28: 723–743.
8. Epstein JB, Epstein JD, Le ND, et al. (2001) Characteristics of oral and paraoral malignant lymphoma: a population-based review of 361 cases. *Oral Surg Oral Med Oral Pathol Oral Radiol Endol* 92: 519–525.
9. American Cancer Society (1999) Cancer facts and figures 1999. American Cancer Society, Atlanta, GA.
10. SEER (surveillance, epidemiology and results), National cancer institute (1999) Cancer statistics review 1973–1996 initial content, update 5 November 1999  
Available from URI: <https://cissecure.nci.nih.gov/ncipubs/>
11. Endo S, Kida A, Sawada U, Sugitani M, Furusaka T, Yamada Y. Clinical analysis of malignant lymphomas of tonsil. *Acta Otolaryngol Suppl* 1996; 523:263-6.
12. Lugassy G, Hurwitz N, Shtalrid M, Varon D, Marshak G, Berrebi A. Clinical and pathological features of non-Hodgkin's lymphoma of the tonsil. Review of the literature and report of 10 cases. *Isr J Med Sci* 1989 May; 25(5): 251-5.
13. Avilés A, Delgado S, Ruiz H, de la Torre A, Guzman R, Talavera A. Treatment of non-Hodgkin's lymphoma of Waldeyer's ring: radiotherapy versus chemotherapy versus combined therapy. *Eur J Cancer B Oral Oncol* 1996 Jan; 32B (1): 19-23.
14. Qin Y, Shi YK, He XH, Yang JL, Yang S, Yu YX. Clinical features of 89 patients with primary non-Hodgkin's lymphoma of the tonsil. *Ai Zheng* 2006 Apr; 25(4): 481-5.
15. Gao Y, Li Y, Yuan Z, Zhao L, Liu X, Gu D. Prognostic factors in patients with primary non-Hodgkin's lymphoma of the tonsil. *Zhonghua Zhong Liu Za Zhi* 2002 Sep; 24(5): 483-5.
16. Economopoulos T, Fountzilas G, Kostourou A, Daniilidis J, Pavlidis N, Andreopoulou H, Nicolaou A, Papageorgiou E, Mellou S, Dervenoulas J, Stathakis N (1998) Primary extranodal Non-Hodgkin's lymphoma of the head and neck in adults: a clinicopathological comparison between tonsillar and nontonsillar lymphomas. (Hellenic Co-operative Oncology Group). *Anticancer Res* 18: 4655–4660.
17. Velasquez WS, Fuller LM, Jagannath S, et al. (1991) Stage I and II diffuse large cell lymphoma. Prognostic factors and long term results with CHOP-Bleo and radiotherapy. *Blood* 77: 942–947.
18. Miller TP, Jones SE (1982). Initial chemotherapy for clinically localized lymphomas of unfavourable histology. *Blood* 62: 413–418.

# CASE REPORT

---

19. Mirza MR, Brinker H, Spetch L (1992). The integration of radiotherapy into the primary treatment of non-Hodgkin's lymphoma. Crit Rev Oncol Hematol 12: 217–229.
20. Gao YH, Li YX, Zhao LJ, Yuan ZY, Liu XF, Yu ZH (2003). Treatment of early stage primary tonsil non-Hodgkin's lymphoma. Zhonghua Xue Ye Xue Za Zhi 24: 190–192.

## **AUTHORS:**

1. N. Vijayendra Simha
2. Nitha
3. Sreenivas N.

## **PARTICULARS OF CONTRIBUTORS:**

1. Associate Professor, Department of ENT, Adichunchunagiri Institute of Medical Sciences, B.G. Nagara, Nagamangala Taluk, Mandya District.
2. Post Graduate, Department of ENT, Adichunchunagiri Institute of Medical Sciences, B.G. Nagara, Nagamangala Taluk, Mandya District.
3. Associate Professor, Department of Pathology, MMC&RI, Mysore

## **NAME ADDRESS EMAIL ID OF THE CORRESPONDING AUTHOR:**

Dr. N. Vijayendra Simha,  
#59, H. B. Samaja Road,  
Basavanagudi, Bangalore – 560004.  
E-mail: drvijayendrasimha@gmail.com

Date of Submission: 06/11/2014.  
Date of Peer Review: 07/11/2014.  
Date of Acceptance: 12/11/2014.  
Date of Publishing: 19/11/2014.