

PARAGANGLIOMA: A CASE REPORTAditya Date¹, Bharat Khadav², Mackson Nongmaithem³¹PG Resident, Department of General Surgery, Dr. D. Y. Patil Medical College, Pimpri, Pune.²PG Resident, Department of General Surgery, Dr. D. Y. Patil Medical College, Pimpri, Pune.³PG Resident, Department of General Surgery, Dr. D. Y. Patil Medical College, Pimpri, Pune**ABSTRACT****INTRODUCTION**

Paragangliomas are relatively rare endocrine tumours that arise from paraganglionic tissue, a widely dispersed collection of specialized neural crest cells. In the absence of histological diagnosis and symptoms of catecholamine excess, paragangliomas may be mistaken for GISTs. Approximately, 50 cases of non-functional retroperitoneal paragangliomas were reported in the literature. We report a case of paraganglioma of the duodenum, which emphasizes the necessity to include extra-adrenal paraganglioma in the differential diagnosis and management of retroperitoneal tumors.

KEYWORDS

Paraganglioma, Catecholamine excess, Retroperitoneal GIST.

HOW TO CITE THIS ARTICLE: Date A, Khadav B, Nongmaithem M. Paraganglioma: A case report. J Evid Based Med Healthc 2016; 3(5), 173-175. DOI: 10.18410/jebmh/2016/41

INTRODUCTION: Paragangliomas are relatively rare endocrine tumours that arise from paraganglionic tissue, a widely dispersed collection of specialized neural crest cells.¹ Paragangliomas, also known as extra-adrenal pheochromocytomas, account for 5-10% of pheochromocytomas and can occur in any position between the neck and the base of the pelvis.² In the absence of histological diagnosis and symptoms of catecholamine excess, paragangliomas may be mistaken for GISTs. On abdominal CT, there are no unique imaging characteristics specific for paragangliomas. Consequently, these tumors may be mistaken for other primary epithelial or mesenchymal abdominal tumors.³ Approximately, 50 cases of non-functional retroperitoneal paragangliomas were reported in the literature.¹ We report a case of paraganglioma of the duodenum.

CASE REPORT: A 70 years old male patient came to the surgical OPD with complaints of pain in upper abdomen and abdominal distension since 4 years associated with loss of appetite and constipation. Patient was a known case of diabetes mellitus on regular treatment with blood sugar levels under control. Per abdomen examination revealed epigastric tenderness with fullness in both the flanks. Blood investigations revealed deranged liver function tests and rest of the blood investigations were within normal limits. Ultrasonography of the abdomen was suggestive of large bilobed soft tissue mass along the wall of 2nd and 3rd part of duodenum measuring 6.1cm x 8.1cm and 4.6cm x 8.6cm with calcification and cystic changes.

CT scan of abdomen revealed a lobulated soft tissue lesion in right sub-hepatic region with areas of egg shell calcification (Fig. 1). The lesion is along posterior wall of proximal 2nd part of duodenum, the anterior and medial wall along the distal 2nd and 3rd part of duodenum and superior margin of the distal 3rd part of duodenum with well-defined margins. The mass is also abutting the lateral margin of the head and uncinate process of pancreas, however less likely arising from it. A diagnosis of? GIST? Leiomyoma was made. Patient was posted for exploratory laparotomy, which revealed a mass abutting the 2nd part of duodenum and the posterior surface of the head and neck of pancreas, which was removed in toto (Fig. 2) and sent for histopathological examination. HPE was suggestive of paraganglioma (Fig. 3). Postoperative period was uneventful.

DISCUSSION: Paragangliomas often present with signs of catecholamine excess. The most common catecholamine secreted is norepinephrine and a classic triad of catecholamine excess (headache, sweating, palpitations) is described. However, this triad may be absent and patients can be asymptomatic or symptoms can be vague (psychiatric disorders, anxiety, facial pallor, weight loss, polyuria/polydipsia, hyperglycemia, secondary erythrocytosis, stroke and cardiomyopathy).^{4,5} Paragangliomas can be found from the upper cervical region to the pelvis, along the autonomic nervous system. They are most commonly present in the organ of Zuckerkandl at the aortic bifurcation.¹

Men are affected more frequently than women and most patients are between the age of 30-45 years.⁶ CT, MRI or ultrasonographic studies are sensitive in detecting a retroperitoneal mass and could delineate its location, outline, internal structure as well as its relationship with the surrounding organs. In addition, histopathological diagnosis is required to define the paraganglioma as benign or malignant tumours exhibit similar clinical diagnosis and imaging findings. Chromogranin A and synaptophysin are

Submission 30-12-2015, Peer Review 01-01-2016,

Acceptance 11-01-2016, Published 18-01-2016.

Corresponding Author:

Dr. Aditya Date,

Flat No. 3, Nikhil Niketan Apartments,

#1838, Sadashiv Peth, Pune-411030, Maharashtra.

E-mail: addydatedr@gmail.com

DOI: 10.18410/jebmh/2016/41

the most common neuropeptides synthesized in endocrine cells and can be used for immunohistochemical analysis of paragangliomas along with other protein markers, such as neuron specific enolase and vimentin. They can aid the correct diagnosis of this rare disease.⁷ Paragangliomas synthesize and store catecholamines, which include norepinephrine (noradrenaline), epinephrine (adrenaline), and dopamine. Elevated plasma and urinary levels of catecholamines and the methylated metabolites, metanephrines are the cornerstone for the diagnosis.³

Macroscopically, paragangliomas are solid tumours and are partially or completely encapsulated with a thin capsule. The cut surface of the tumour is tan to red-brown, extremely vascular, homogeneous or focally fibrotic. Larger tumours may show haemorrhage and cystic degeneration.

Histologically, retroperitoneal paragangliomas are composed of chief cells which are polygonal or slightly spindled with an amphophilic or eosinophilic cytoplasm. Histologically, paragangliomas are characterized by a honeycomb pattern in which well-circumscribed nests (Zellballen) of round-oval or giant multinucleated neoplastic cells with cytoplasmic catecholamine granules.⁸

The possibility for malignant transformation of paragangliomas makes surgical excision the treatment of choice. Radiation therapy has been advocated for patients who cannot undergo surgery or for unresectable tumours. Therapy with radionucleotides may be used for tumors exhibiting uptake on diagnostic scan. Octreotide can be used for treatment of inoperable paragangliomas.¹

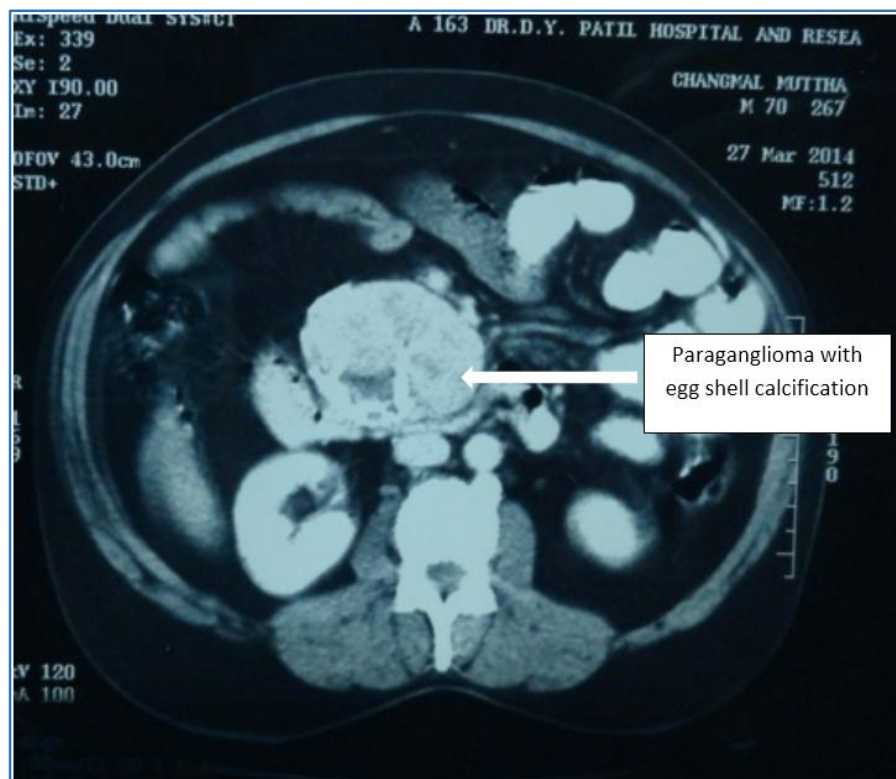


Fig. 1: CT Scan Image showing tumour mass (Paraganglioma with egg shell calcification)

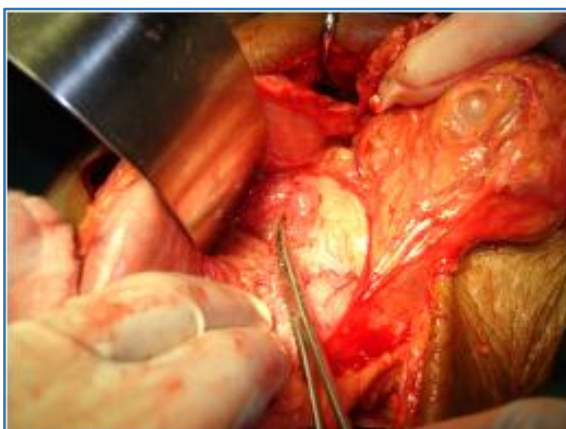


Fig. 2: Intraoperative figure showing the tumour abutting the 2nd part of duodenum and the posterior surface of the head and neck of pancreas

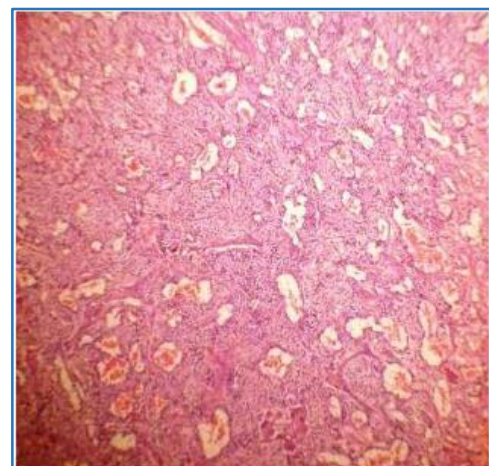


Fig. 3: Photomicrograph showing Zellballen arrangement of cells in which the cell nests are separated by fibrous septae or bands. [H&E x 40]

CONCLUSION: This case emphasizes the necessity to include extra-adrenal paraganglioma in the differential diagnosis and management of retroperitoneal tumors, despite its rarity. Vimentin may be useful in the diagnosis and also can be used to differentiate between malignant and benign tumor. Surgical excision is the only treatment of choice. Adjuvant radiotherapy or chemotherapy has no role. Regular follow-up with ultrasound and CT scan are necessary to detect early tumor recurrence.

REFERENCES:

1. Limaïem F, Bouraoui S, Bouslama S, et al. Retroperitoneal non-functioning paraganglioma: A case report. *J Interdiscipl Histopathol* 2013;1(3):168-171.
2. Zhang J-J, Liu T, Peng F. Primary paraganglioma of the lung: a case report and literature review. *The Journal of International Medical Research* 2012;40:1617-1626.
3. Bhat S, Shah A. Case report on paraganglioma duodenale. *Web med Central Surgery* 2011;2(1):1-7.
4. Yeo H, Roman S. Pheochromocytoma and functional paraganglioma. *Curr Opin Oncol* 2005;17(1):13-8.
5. Prys-Roberts C. Pheochromocytoma: recent progress in its management. *Br J Anaesth* 2000;85:44-57.
6. Hayes SW, Davidson AJ, Grimley PM, et al. Extraadrenal retroperitoneal paraganglioma: clinical, pathologic and CT findings. *AJR* 1990;155(6):1247-1250.
7. He J, Wang X, Zheng W, et al. Retroperitoneal paraganglioma with metastasis to the abdominal vertebra: a case report. *Diagnostic Pathology* 2013; 8:52.
8. Feng N, Zhang WY, Wu XT. Clinicopathological analysis of paraganglioma with literature review. *World J Gastroenterol* 2009;15(24):3003–3008.