

## OUTCOME OF TOTAL HIP ARTHROPLASTY IN AVASCULAR NECROSIS OF HIP: A PROSPECTIVE STUDY

B. Valya<sup>1</sup>, Kollam Chandrasekhar S<sup>2</sup>, Saritha Devari<sup>3</sup>

<sup>1</sup>Professor & HOD, Department of Orthopaedics, Gandhi Medical College, Secunderabad.

<sup>2</sup>Associate Professor, Department of Orthopaedics, Gandhi Medical College, Secunderabad.

<sup>3</sup>Civil Assistant Surgeon, Department of Orthopaedics, Gandhi Medical College, Secunderabad.

---

### ABSTRACT

---

#### AIM

The aim of study was to evaluate the outcome of total hip arthroplasty in avascular necrosis of hip.

#### MATERIALS AND METHODS

Total hip replacement is done in Gandhi Hospital for Ficat 3rd & 4th stages of avascular necrosis of hip. Our study included patients reporting to Gandhi Medical College/Hospital from September 2013 to May 2016, operated by Total Hip Arthroplasty using cemented/uncemented prosthesis and those who were available for followup.

#### RESULTS

The study was carried out on 28 hips of 24 patients who underwent Total Hip Arthroplasty from September 2013 till May 2016. Of the 24 patients, majority are (20) male with mean age of 37 years. Of the 28, 21 had excellent results, 5 had good results, 2 had fair results.

#### CONCLUSION

In properly selected cases, Total Hip Arthroplasty offers a better alternative procedure currently available for avascular necrosis of hip.

#### KEYWORDS

Avascular Necrosis of Hip, Total Hip Arthroplasty, Cemented, Uncemented, Harris Hip Scores.

---

**HOW TO CITE THIS ARTICLE:** Valya B, Kollam CS, Devari S. Outcome of total hip arthroplasty in avascular necrosis of hip: A prospective study. J. Evid. Based Med. Healthc. 2016; 3(68), 3681-3688. DOI: 10.18410/jebmh/2016/790

---

**INTRODUCTION:** The human hip joint is extremely complex on account of the functional demands of the body. On account of its complex biomechanics & important function, a stable painless hip is required for normal locomotion.

Number of diseases affects the hip joint. This number has grown over the years as the life expectancy of individuals has increased.

In the beginning the thought of operating on the hip deferred even the most aggressive surgeons. With the improvement in anaesthesia, post-operative care and especially the aseptic operating room ritual have brought down the risk of operating on the hip to very low, thus increasing the widespread acceptance of elective surgery.

Although hip surgery had its root in the 19<sup>th</sup> century, its greatest period of growth & development has occurred in 20<sup>th</sup> century. An ever growing population of chronic joint disease demanding relief of pain & disability has led to development of operations such as osteotomy & arthroplasty.

---

*Financial or Other, Competing Interest: None.*  
*Submission 13-08-2016, Peer Review 16-08-2016,*  
*Acceptance 23-08-2016, Published 25-08-2016.*

*Corresponding Author:*

*Dr. B. Valya,*  
*Raintree Park, Block 2, Flat 405, KPHB Colony,*  
*Kukatpally, Hyderabad, Telangana.*  
*E-mail: orthovalya@gmail.com*  
*DOI: 10.18410/jebmh/2016/790*

---

The original intent of arthroplasty was to restore motion to an ankylosed joint. This concept has expanded to include the restoration as far as possible the integrity & functional power of a diseased joint. While a resection restores motion, arthroplasty must not only restore motion but also provide stability to the joint.

While in an arthrodesis, the purpose of the operation is to create raw cancellous bone surface on each side of the joint & hold them in rigid apposition. In an arthroplasty, the purpose of the operation is to shape the ends of the bones & to hold the surfaces apart, almost always using some material interposed between the fragments. Total joint replacement has undergone many changes since it was first attempted in the early 20<sup>th</sup> century. It was on the basis of failures of previous surgeries & valuable clinical experience from it by the surgeons that these changes were introduced. Initially, bone cement was used to fix the articulating surfaces of the THA to the bony ends. But high rates of loosening of the implants, especially the acetabular components led to a change in the technique of fixation of the implants.

Thus, bone in growth for biological fixation was introduced. The technique of Cementless Total Hip Arthroplasty could be used in younger patients in the hope that it might last longer. However, due to failures in femoral stem fixation on account of little bone ingrowth, thigh pain & ideal method of fixation of the femoral stem, cemented

acetabular and cemented femoral stem fixation is advised in elderly patients.

Anthony White, in 1822, performed the first recorded arthroplasty of hip. He did an osteotomy and subsequent excision of the femoral head diseased by tuberculosis. The multiple sinuses healed postoperatively and a satisfactory range of motion was achieved by the patient<sup>1</sup>.

John Rhea Barton, in 1827, performed an intertrochanteric osteotomy for severe hip deformity in a sailor, achieving pseudoarthrosis and a reasonable range of motion and stability at the operated hip.<sup>2</sup>

In Chicago 1913, J B Murphy, developed procedures for arthroplasty for all of the major joints using a flap of fascia and fat interposed between the remodelled joint surfaces<sup>3</sup>. In 1917, William S Baer, used chromicised sheets of pig bladder as the interposing membrane (Baer's membrane).<sup>4</sup>

"Mould Arthroplasty", as Smith Peterson called his operation consisted of revision of both the head of the femur and the rim of the acetabulum. 82% good or satisfactory results were obtained in 1000 cases.<sup>5</sup> This operation was shown to be particularly useful for patient with rheumatoid patients.

In 1950, the hemiarthroplasty of the Judet brothers<sup>6</sup> and the interposition and mould arthroplasty of Smith Peterson gave surgeons experience with reconstructive hip surgery. In 1953, Philip Wiles of London implanted matched acetabular and femoral components made of stainless steel as hip replacements in 6 patients with disease.<sup>7</sup> The acetabulum was stabilised with screws and the head component with a stem, side plate and screws.

All metal combinations were introduced by McKee and Farrar (1966) and Ring (1968) in England and by Haboush, Urist and McBride in US (1957).<sup>8,9,10</sup> The results were not entirely satisfactory because of problems with loosening of the components and were between the opposing metal surfaces.

Berger R A et al 1997 showed that the intermediate short-term results of cement acetabular reconstruction have been encouraging.<sup>11</sup>

Maloney and Harris did a retrospective study<sup>12</sup> comparing hybrid and cementless primary THA performed between 1984 and 1986. 67 patients who had hybrid prosthesis had a better result both clinically and radiologically. The average post-operative score for hybrid patients was 97 points compared to 87 points for 69 patients who had the uncemented prosthesis. No hip was rated as fair or poor in the hybrid group, whereas four hips rated poor and one rated fair or poor in the hybrid group, whereas four hips rated poor and one rated fair in uncemented group. 96% of hybrid patients reported no pain or only slight occasional discomfort. In the contrast, 24% of the patients who had undergone uncemented prosthesis reported mild, moderate or severe pain. There was no migration of the acetabular component in either group. All the femoral components in the hybrid group were radiologically stable with no evidence of aseptic loosening. In contrast, 20% of the femoral component in the uncemented group had radiographic evidence of migration. None of the hips in the

hybrid group a re- operation compared with four of the hips in the uncemented group.

Goldberg et al<sup>13</sup> in 1996 performed 125 THA in 120 patients and followed up for 7-11 years. Mean age of patients was 71 years. The diagnosis included primary and secondary osteoarthritis in 112 patients, osteonecrosis in 5 patients and rheumatoid arthritis in 3 patients. The average Harris hip score was 37 points preoperatively, and at the latest followup was 92 points. One acetabular component was revised for reluctant dislocation 3 years after the surgery and one stem was revised for mechanically loosening and one stem radiographically loose. There was no evidence of cup migration more than 1 mm. There were no radiolucencies around any of the screws. Two sockets had polyethylene wear of 2 mm. This study suggested that hybrid total hip replacement is an excellent procedure for reconstruction of the arthritis hip with minimal evidence of polyethylene wear.

A study has been conducted to evaluate clinical & radiological results of cemented THR in various disorders of Hip in the Department of Orthopaedics, Gandhi Medical College/Hospital, during September 2013 to September 2015.

**MATERIALS AND METHODS:** Our study included patients reporting to Gandhi Medical College/Hospital from September 2013 to September 2015, operated by Total Hip Arthroplasty using cemented/uncemented acetabular cup and cemented/uncemented femoral stem and those who were available for followup.

**Inclusion Criteria:** All cases are selected on the basis of,

- Clinical signs and symptoms.
- Radiological findings.
- Patients who have been diagnosed as avascular necrosis of hip.
- Patients who are fit for surgery.

**Exclusion Criteria:**

- Patients above 80 years age.
- Patients who are unfit for surgery due to associated medical problems.
- Patients with compound fractures and septic arthritis.

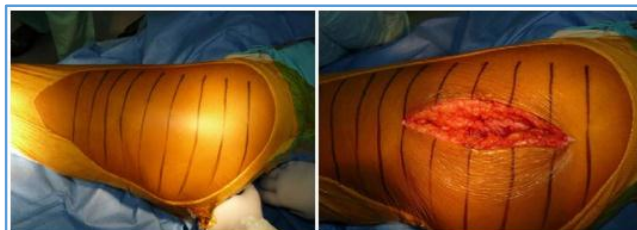
Detailed history, clinical examination, and radiological examination were carried out in all patients. Salient features included.

Routine blood and urine investigations done.

- X-Ray pelvis with both hips AP.
- X-Ray hip with thigh-R/L.
- X-Ray LS Spine (in selected patients).

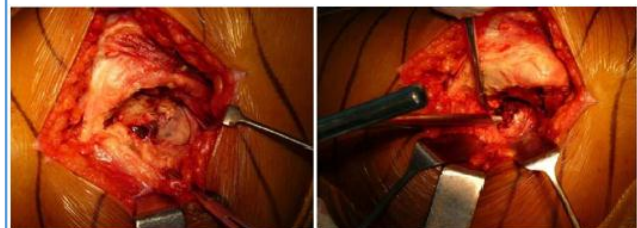Patients were evaluated and data recorded on the basis of Harris hip score.

**STEPS OF OPERATIVE PROCEDURE:**



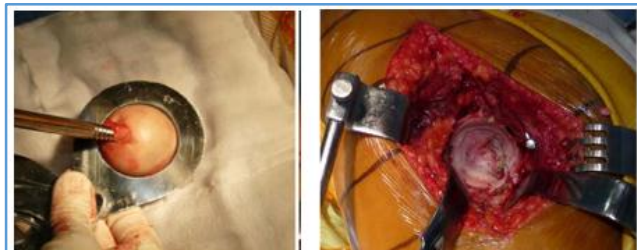
PREPARATION

SKIN INCISION



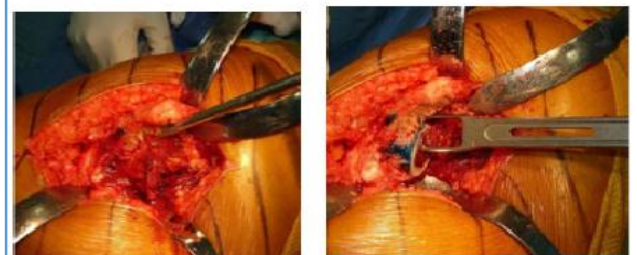T SHAPED INCISION OVER CAPSULE

EXTRACTING HEAD



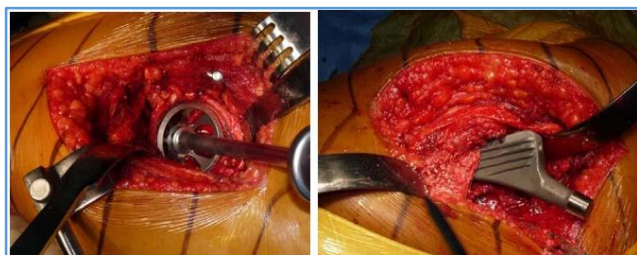MEASURING HEAD SIZE

ACETABULUM

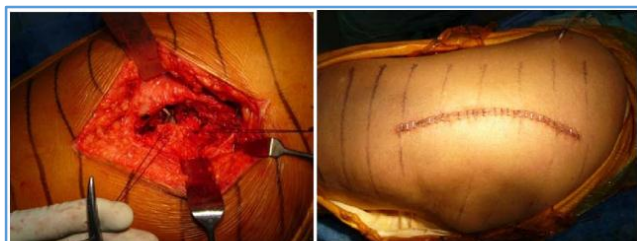

STRAIGHT REAMER ENTERING FEMORAL CANAL

BOX-OSTEOTOME



REAMING WITH BROACHES, INSERTION OF FEMORAL COMPONENT



CLOSURE AFTER REDUCTION

SKIN CLOSURE WITH STAPLES

**Post-operative Protocol:** The hip was positioned in approximately 15 degrees of abduction while the patient is recovering from the anaesthetic using a triangular pillow to maintain abduction and prevent extremes of flexion.

First postop day, check x-rays were taken. The patient is taught static quadriceps exercises; knee and ankle mobilisation exercises and made to sit.

Second postop day, dressing changed and smaller dressing applied. Gait training was started using a walker with weight-bearing to tolerance. Drains were removed 48 hours after surgery.

IV antibiotics were given for 5 days, later switched over to oral antibiotics for further 5 days. On 12<sup>th</sup> postop day, sutures were removed and discharged from the hospital to be reviewed after one month. They were advised:

- Not to squat.
- Not to sit cross-legged.
- Not to use Indian toilets.
- Not to cross the lower limb across the midline.

**Followup:** The patients were followed up at 6 weeks, 3 months, 6 months and 1 year.

**Clinical Assessment:** During each visit, patients were evaluated for pain, ROM and Harris hip score. Based on a total of 100 points possible, each question is awarded a certain number of points. Questions are further grouped into categories.

The first category is pain. No pain in the hip is awarded 44 points, slight pain 40 points, down to 0 points for disabling pain.

The second category is function. If there is no limp, not using a walking aid, and can walk more than six blocks, 33 points were awarded; less if the patient uses a cane, or can walk only two blocks, etc.

The third category, functional activities, consists of questions about how the patient climbs stairs, puts on shoes, length of time patient can sit in a chair, and use of public transportation.

Finally, the physical exam results are tabulated and based on the absence of deformity and range of motion, up to 9 points were awarded. The score is reported as 90-100 for excellent results, 80-90 being good, 70-79 fair, 60-69 poor and below 60 a failed result.

**HARRIS HIP SCORE:**

**Pain (44 possible)**

- |  |    |
|--|----|
| • None or ignores it   | 44 |
| • Slight, occasional, no compromise in activities  | 40 |
| • Mild pain, no effect on average activities, rarely moderate pain with unusual activity, may take aspirin   | 30 |
| • Moderate pain, tolerable but makes concessions to pain, some limitation of ordinary activity or work, may require occasional pain medicine stronger than aspirin | 20 |
| • Marked pain, serious limitation of activities  | 10 |
| • Totally disabled, crippled, pain in bed, bed ridden  | 0  |

**Function (47 Possible):**

**Gait (33 Possible)**

**Limp:**

None	11
Slight	8
Moderate	5
Severe	0

**Support:**

None	11
Cane for long walks	7
Cane most of the time	5
One crutch	3
Two canes	2
Two crutches	0
Not able to walk (specify reason)	0

**Distance walked:**

Unable to do stairs	0
Unlimited	11
Six blocks	8
Two or three blocks	5
Indoors only	2
Bed & Chair	0

**Activities (14 possible)**

**Stairs**

Normally without using a railing	4
Normally using a railing	2
In any manner	1
Shoes and socks	
With ease	4
With difficulty	2
Unable	0

**Sitting**

Comfortably in ordinary chair one hour	5
On a high chair for half an hour	3
Unable to sit comfortably in any chair	0
Enter Public Transport	1

**Absence of Deformity (4) is given if the patient demonstrates:**

- Less than 30° fixed flexion contracture.
- Less than 10° fixed adduction.
- Less than 10° fixed internal rotation in extension.
- Limb length discrepancy less than 3.2 cm.

**Range Of Motion (\*Normal):** Total degree measurements, then check range to obtain score.

Flexion (*140 degrees):	_____
Abduction (*40 degrees):	_____
Adduction (*40 degrees):	_____
External rotation (*40 degrees):	_____
Internal rotation (*40 degrees):	_____

**Range-of-Motion Scale:**

211-300 degrees	5
161-210 degrees	4
101-160 degrees	3
61-100 degrees	2
31-60 degrees	1
0-30 degrees	0

Range-of-Motion Score: \_\_\_\_\_

Total Harris Hip Score: \_\_\_\_\_

< 70:	Poor
70 to 79:	Fair
80 to 89:	Good
90 to 100:	Excellent

**RESULTS AND DISCUSSION:** This study was conducted in Department of Orthopaedics in Gandhi Medical College/Gandhi Hospital, Musheerabad. 28 hips were operated in 24 patients, for avascular necrosis of hip joint. Following results were obtained.

**Age:** Age varied from the lowest of 18 to a highest of 70 years. Mean age of patient in our study was 37 years.

Age (In years)	Number of Patients	Percentage (%)
<30	8	33.3%
30-50	11	45.9%
50-60	5	20.8%
<b>Total</b>	<b>24</b>	<b>100.0%</b>

*Table 1*

**Gender:** In our study, 20 patients were male and 4 were female.

Gender	Frequency	Percentage
Male	20	83%
Female	4	17%
<b>Total</b>	<b>24</b>	<b>100.0%</b>

*Table 2*

**Implants Used:** In our study, 14 (50%) were cemented, 14 (50%) were uncemented type.

Implants	Frequency (y)	Percentage
Cemented	14	50.0%
Uncemented	14	50.0%
<b>Total</b>	<b>28</b>	<b>100.0%</b>

*Table 3*

**Side Distribution:** In our study, 15 (53.6%) Right hips were operated and 13 (46.4%) Left hips were operated.

Side	No. of PT	Percentage (%)
Right	15	53.6%
Left	13	46.4%
<b>Total</b>	<b>28</b>	<b>100.0%</b>

*Table 4*

**Post-Operative Limb Length Discrepancy:**

Length	Frequency	Percentage (%)
1.0	2	7.1%
1.5	1	3.6%
Not Applicable	25	89.3%
<b>Total</b>	<b>28</b>	<b>100.0%</b>

**Table 5**

**Final Outcome According to age:**

Outcome score	<30 yrs.	30-50 yrs.	>50 yrs.	Total	Percentage
Fair	0	1	1	2	7.1%
Good	2	2	1	5	17.9%
Excellent	8	10	3	21	75.0%
<b>Total</b>	<b>10</b>	<b>13</b>	<b>5</b>	<b>28</b>	<b>100.0%</b>

**Table 6**

In the age group of patients less than 30 years (35.7% of the study group), 80% had excellent post-operative outcome scores and 20% had good outcome score. In the 30–50 years age group, 77.0% had excellent results and 15.3% had good results and 7.7% had fair results. In the patients above 50 years, 60.0% had excellent outcome scores and 20.0% had good and 20.0% had fair outcome scores. Though the outcome scores were fair in 7.7% of 30-50 years group and 20.0% in above 50 groups, there was no statistical significance noted.

Total hip arthroplasty is a well-documented surgical procedure. It relieves pain and functional disability experienced by patients with Avascular necrosis of the hip Ficat stage 3 & 4, improving their quality of life.

Study	No. of arthroplasties
Berger et al	150
Harris et al	126
Goldberg et al	125
Garino et al	123
<b>Our Study</b>	<b>28</b>

**Table 7**

While our study was limited to 28 THAs, Berger et al performed 150 THAs, Harris et al performed 126 THAs. and Goldberg et al performed 125 THAs. Garino et al performed 123 THAs. This is due to the fact that this study was limited to a very short duration. Also, financial constraints and unawareness of this procedure to the patient limited the number of patients for this study.

In western literature, as per Harkess, Charney, Eftekhar total hip arthroplasty has primarily been described for patients in older age group of sixty and above. In our study, 23.1% of the patients were found to be in the 50 and above age group, 30.8% of patients were between 30-50 yrs., 46.1% of patients were below 30 yrs. with age ranging from 20 years to 60 years and a mean age of 35 years. 12 were males and 1 female.

The Harris hip score is the most widely used scoring system for evaluating hip arthroplasty. We used Harris hip score to assess the functional outcome in our study. Singling out the primary indication of the procedure is difficult, but reports of Eftekhar, Harkess document the arthritis group to be the most common indication. Arthritis secondary to Avascular necrosis was the most common indication for THR surgery in our study.

The age limit for this series was up to 70 years. Many series have shown that the rate of loosening and revision of total hip arthroplasty is high in younger patients. The cemented acetabular component has been the source of most of these failures. The short-term results of the cementless acetabular reconstruction have been encouraging in young patients. Berger et al reported a 10-year survival of 98.8% in patients younger than 50 years.

Patients were evaluated after discharge at 4 weeks, 2 months, 6 months, 1 year. Average followup was 11 months in this study, as compared to much larger followups available in western literature (42 months by Harris et al, 8.6 years by Goldberg et al and 103 months by Berger et al).

Study	Average followup
Harris et al	42 months
Goldberg et al	8.6 years
Berger et al	103 months
Our study	11 months

**Table 8**

Mean Harris hip score improved from 34 points preoperatively to 90 points postoperatively. 92.8% of hips were graded as good or excellent in this study, 7.1% were graded fair and no poor results were reported. Harris et al reported improvement in Harris hip score from 57 preoperatively to 93 points postoperatively. 96% good to excellent results, 4% fair and no poor results were reported. Goldberg et al reported improvement in Harris hip score from 47 preoperatively to 88 points postoperatively. 85% good to excellent results, 13% fair and 9% poor results obtained in his series. Garino et al reported an improvement in HHS from 45 points preoperatively to 92 points at the time of followup.

Bourne et al, in a study of 101 total hip replacements, reported an average Harris hip score of 96 points, but only patients who were free of pain were evaluated. When patients who had pain were included, the overall average score was 90 points. Heekin et al<sup>14</sup> reported an average score of 93 points after a minimum of five years of followup of 91 hips. In a study by Katz et al., the results of 14 arthroplasties, in which the stem had been fixed without cement, the hip score averaged 84 points at forty six months. Barrack and Lebar reported an average Harris hip score of 93 points after 49 arthroplasties in which the LSF (long-term stable fixation) prosthesis (OTI [Osteoimplant Technology International], Hunt Valley, Maryland) had been used.<sup>15</sup> These figures were comparable to our results.



Study	Average Harris Hip Score, post-op
Harris et al	93
Goldberg et al	88
Garino et al	92
Bourne et al	90
Heekin et al	93
Katz et al	84
Barrack and Lebar	93
Our study	90

**Table 9**

In our study, all patients in the age group less than 30 years, (33.3% of the study group), had excellent post-operative outcome scores. In the 30–50 years age group, 76.9% had excellent and 15.4% had a good and 7.7% had fair postoperative outcome scores which is in par with a study by Mont et al., who reported favourable results of total hip replacements without cement in patients less than forty-five years old.

Pain relief was also dramatic following THR. 50% of the patients had marked pain preoperatively and 31% had moderate pain. Postoperatively 94% of patients were relieved of pain, only 6% patients had moderate pain. Similar result was obtained by Harris et al (98% complete pain relief) and Berger et al (94.5% complete pain relief).

Study	Complete relief of pain
Harris et al	98.0%
Berger et al	94.5%
Our study	94.0%

**Table 10**

Slight or no limp is seen in 89.3% of patients in this study. Moderate limp was present in 10.7% of patients. In a study by Harris, 63% patients had no limp and 28% of patients had slight limp. Berger et al also reported low rate of limping. The limping improves over a period of time with progressive abductor exercises. As this study has a followup of 11 months, percentages of patients limping are expected to decrease with time.

94% patients needed no support or only occasional cane for walking long distances. 6% patients required cane full time. This finding is comparable to the results obtained by Harris et al (95% patients used cane occasionally). Anterior thigh pain occurred in only 14.3% of the patients in the present study, which disappeared after few months. Our study detected no association between pain in the thigh and position of the stem which shows similar results as seen in a study by Matthew J. Kraay, Victor M. Goldberg et al, pain in the thigh occurred after only 5 percent (five) of the total hip arthroplasties and detected no association between pain in the thigh and the size of the stem.

In cemented, radiographically results were excellent. Second generation cementing techniques were used. Grading the initial appearance cement mantle columns

resulted in 44% hips with Grade A, 30% with Grade B, 16% with Grade C1, and 10% with Grade C2 cementing technique. This result was comparable to results by Berger et al (41% hips with Grade A, 24% with Grade B, 7% with Grade C1, and 27% with Grade C2 and 1% Grade D cementing technique). Two hips showed evidence of loosening or osteolysis in femoral and/or acetabular component. No hip showed vertical migration of acetabular cup. In series by Harris et al, no femoral component as definite or probably loose and one acetabular component showed migration. However, as our study has very short followup, definite conclusions can only be drawn after longer followup.

Radiographically, in uncemented, the results were also excellent. Extensive pedestal formation is considered another potential radiographic sign of instability of the implant. In our study, one case of femoral subsidence seen, this is not affecting the functional outcome. In contrast, Campbell et al reported that 25 percent (twenty-eight) of 110 stems had notable subsidence at two years, and Barrack and Lebar found that 6 percent (three) of forty-nine stems had subsided at least three to four millimetres. Studies with longer followup have demonstrated a notably higher prevalence of femoral osteolysis.

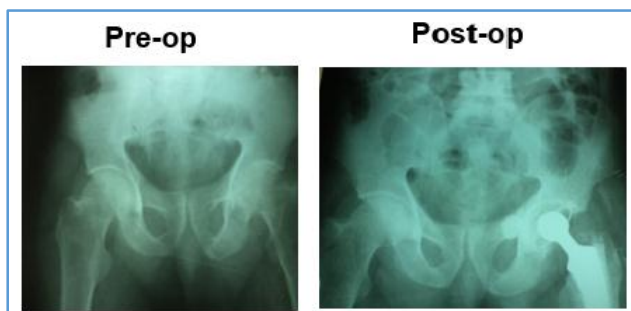
Intraoperative periprosthetic femoral fractures are becoming increasingly common and are a major complication of total hip replacement (THR). The largest study of intraoperative femoral fractures at the time of revision total hip arthroplasty was reported by Meek et al. Of 211 consecutive patients, 64 (30%) sustained an intraoperative femoral fracture and 147 did not sustain a fracture. Berend et al reported on 1320 primary total hip arthroplasties done with use of an uncemented femoral stem. There were 58 intraoperative calcar fractures, which were treated with cerclage wires or cables and unrestricted weight-bearing postoperatively. At the time of followup, at a mean of 7.5 years and a minimum of 2 years, no patient had undergone a revision. In one study, an intraoperative femoral fracture was encountered during 1% (238) of 23,980 primary total hip arthroplasties compared with 7.8% (497) of 6349 revisions, and subsequent studies have demonstrated similar results. In the study mentioned above, the rate of periprosthetic fractures during primary total hip arthroplasty was 5.4% (170 of 3121) when a cementless femoral component was used compared with 0.3% (sixty-eight of 20,859) when a cemented stem was used. Other studies demonstrated a prevalence of intraoperative fracture of 1.2% (seven of 605) when a cemented stem was used and 3% (thirty-nine of 1318) when a cementless femoral component was used. Our study is on par with other studies. In our study, 12.5% (one of 8 uncemented) sustained periprosthetic fracture and no patients with cemented variety sustained any fracture.

Study	Periprosthetic fracture in uncemented variety	Periprosthetic fracture in cemented variety
Berry DJ	5.4%	0.3%
Schwartz JT et al	3.0%	1.2%
Our study	12.5%	None

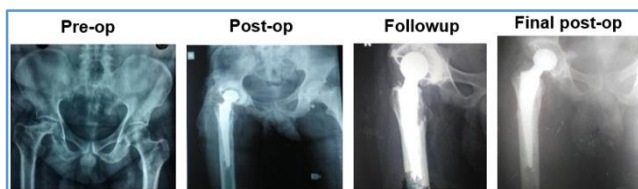
**Table 11**

In uncemented prosthesis, stress shielding was noted in 33.3% of the patients and 91.3% of them were below the age of 40. All the patients had good to excellent outcome score. There was no statistical data to prove any association of stress shielding to placement of the stem. However, these reactive changes did not adversely affect the clinical outcome or radiographic stability or predispose the distal aspect of the femur to osteolysis in our series.

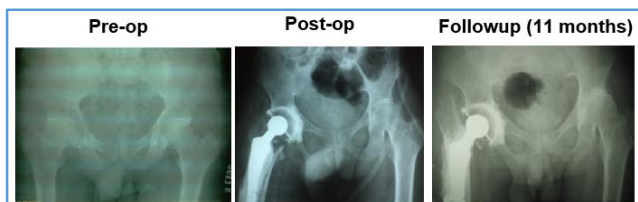
**Four complications were seen in our series:** One case of acetabular perforation noted on postop x-ray with no complaints from patient.



One case of infection and loosening noted, treated with antibiotic therapy and two staged re-implantation of components.



One case of Vancouver type A1 fracture, treated conservatively and advised no weight-bearing for 1 month and review, but unfortunately patient missed the followup and reviewed at 11 months with complaints of occasional pain in ipsilateral knee. Radiologically stem loosening and subsidence noted, advised revision THR. Patient refused surgery.



One patient had Cerebrovascular accident, medical treatment given but patient did not recover and collapsed.

**CONCLUSION:** We have done an evaluation of Total Hip Arthroplasty using cemented, uncemented components. We have operated 28 hips in 24 patients for avascular necrosis of head of femur.

Excellent to good results were obtained in 92.9% of patients postoperatively according to Harris hip criteria. Hence, this study provides an evidence modality of treatment for avascular necrosis of head of femur.

However, because of short period of study and less number of subjects, longer study is required to make definitive conclusions. At present it can be concluded that in properly selected cases, THA offers a better alternative procedure currently available for avascular necrosis of hip with the following pitfalls:

1. A greater magnitude of surgery.
2. Increased blood loss.
3. An increased early dislocation rate (As compared to hemiarthroplasty).
4. Increased cost of surgery.
5. Difficulty in revision arthroplasty (Due to cement use).
6. Complications associated with the use of cement.

**REFERENCES**

1. Thompson FR. An essay on the development of arthroplasty of the hip. Clin Orthop Relat Res 1966;44:73-82.
2. Barton JR. On the treatment of ankylosis by the formation of artificial joints. 1827. Clin Orthop Relat Res 2007;456:9-14.
3. Murphy JB. Arthroplasty. Am Surg 1913;57:593.
4. Baer VS. Arthroplasty with the aid of animal membrane. Am J Orthop Surg 1918;216(3):171-199.
5. Peterson SMP. Arthroplasty of the hip: a new method. J Bone and Joint Surg 1939;21(2):269-288.
6. Judet J, Judet R. The use of an artificial femoral head for arthroplasty of the hip joint. J Bone and Joint Surg 1950;32B(2):166-173.
7. Wiles P. The surgery of the osteoarthritic hip. Br Jr Surg 1958;45(193):488-497.
8. Mckee GK, Farrar WJ. Replacement of arthritic hips by Mckee Farrar prosthesis. J. Bone and Joint Surg 1966;48(2):245-259.
9. Ring PA. Complete replacement arthroplasty of the hip by the ring prosthesis. J Bone and Joint Surg 1968;50B(4):720-731.
10. Urist M. The principles of hip socket arthroplasty. J Bone and Joint Surg 1957;39(4):786-810.
11. Berger RA, Jacobs JJ, Quigley LR, et al. Primary cementless acetabular reconstruction in patients younger than 50 years old. 7- to 11-year results. Clin Orthop Relat Res 1997;344:216-226.
12. Maloney WJ, Harris WH. Comparison of a hybrid with an uncemented total hip replacement. J Bone and Joint Surg 1990;72(9):1349-1352.

13. Goldberg VM, Ninomiya J, Kelly G, et al. Hybrid total hip arthroplasty 7 to 11 year follow up. *Clin Orthop Relat Res* 1996;333:147-154.
14. Heekin RD, Callaghan JJ, Hopkinson WJ, et al. The porous coated anatomic hip inserted without cement. *J Bone and Joint Surg* 1993;75(1):77-91.
15. Barrack RL, Mulroy RD, Harris WH. Improved cementing technique and femoral component loosening in young patients with hip arthroplasty 12 years radiographic review. *J Bone and Joint Surg* 1992;74(3):385-389.