

OCULAR SURFACE DISORDERS AT A RURAL MEDICAL COLLEGE HOSPITAL IN MAHARASHTRA, INDIA

Prajakta Pradip Sambarey¹, Vinay Suresh Chakkarwar²

¹Professor and Head, Department of Ophthalmology, MIMER Medical College, Telegaon (Dabhade), Pune, Maharashtra.

²Junior Resident, Department of Ophthalmology, MIMER Medical College, Telegaon (Dabhade), Pune, Maharashtra.

ABSTRACT

BACKGROUND

Disorders affecting the ocular surface may present from mild ocular discomfort to blindness; therefore, prompt detection and apt management assume prime importance.

MATERIALS AND METHODS

A prospective, cross-sectional, observational study was done to identify and manage various disorders affecting the ocular surface in patients at a rural hospital. Purposive sampling was done, and proportion of various disorders was calculated. Twelve hundred patients with ocular surface disorders visiting the hospital were included in the study. After prior consent and comprehensive history, a thorough, ocular examination was done using slit lamp and accessories. Staining with fluorescein, Tear-film Break Up Time (TBUT), Schirmer's tests and biopsies were done when necessary. General and systemic examination was performed to detect associated diseases. Specific management strategies were employed for each disorder.

RESULTS

The mean age was 42.27 ± 41.44 years. Conjunctivitis was the most common disorder present in 509 patients, followed by Dry Eye Disease (DED) in 292. Other disorders detected included Stevens-Johnson syndrome, clinically suspicious cicatricial pemphigoid, blepharitis, keratitis, chemical injuries, pterygium, ophthalmia nodosa, sebaceous gland carcinoma (SGC) and graft versus host disease.

CONCLUSION

Timely detection by thorough examinations and appropriate management of ocular surface diseases alleviates patient's suffering, and in some cases prevents blindness.

KEYWORDS

Ocular Surface Disorders, Presentations, Management.

HOW TO CITE THIS ARTICLE: Sambarey PP, Chakkarwar VS. Ocular surface disorders at a rural medical college hospital in Maharashtra, India. J. Evid. Based Med. Healthc. 2018; 5(36), 2600-2605. DOI: 10.18410/jebmh/2018/536

BACKGROUND

The ocular surface is an interface between the functioning eye and the environment. Trauma or disease can compromise ocular surface integrity. This dysfunction leads to protean manifestations ranging from a mild corneal abrasion to severe stem cell loss, decreased vision, consequences of dry eye disease (DED) and even blindness. Diseases of the ocular surface are extremely common and range from asymptomatic to debilitating.¹ Timely management of ocular surface problems can avert many serious ocular debilities.

Aims and Objectives

This prospective, cross-sectional, observational study was done to detect and manage disorders affecting the entire ocular surface in 1200 patients at a rural medical college hospital in Maharashtra, India, during the period of October 2011 to April 2013.

MATERIALS AND METHODS

The study was planned after consulting a statistician and with approval by the ethics committee. After prior consent, patients with ocular surface disorders visiting the hospital were included in the study. A comprehensive history was recorded, laying particular stress on duration, diurnal fluctuation of symptoms and exacerbating conditions. History of associated systemic disorders and use of systemic and ocular medication as well as any surgical procedure undergone by the patient was also noted. A general and systemic examination was done to detect associated diseases likely to compromise ocular surface integrity. Ocular examination was conducted using a slit-lamp with accessories like applanation tonometer and 78D and 90D lenses, and direct and indirect ophthalmoscope. The extent of corneal involvement was assessed by staining with

Financial or Other, Competing Interest: None.
Submission 10-08-2018, Peer Review 13-08-2018,
Acceptance 29-08-2018, Published 01-09-2018.

Corresponding Author:

Dr. Vinay Suresh Chakkarwar,
Laxmi Netralaya and Laser Centre,
Shivaji Chauk, Main Road,
Pusad, Yavatmal District,
Maharashtra- 445204.

E-mail: vinaysuresh55@rediffmail.com

DOI: 10.18410/jebmh/2018/536



fluorescein strips. Tear substitutes were prescribed in all cases. Specific management strategies were employed according to the underlying pathology.

Hot fomentation and azithromycin eye drops (1% W/V) three times a day and ointment (1% W/W) at bed time were advised in cases of Meibomian Gland Dysfunction (MGD). An oral doxycycline dose of 100 mg per day was prescribed for minimum two weeks in resistant cases. Squamous blepharitis was treated by cleaning the lid margins with diluted baby shampoo and application of steroid ointment. Azithromycin eye ointment was prescribed in ulcerative blepharitis. The importance of lid hygiene was particularly stressed upon in all cases. Whenever necessary, a dermatologist was consulted. Epilation was done in trichiasis, and excision and reconstructive surgery was performed in the case of sebaceous gland carcinoma.

Ophthalmia nodosa was treated by removal of caterpillar hair and topical steroids. Vitamin A deficiency was managed by dietary advice and ocular lubrication. Allergic conjunctivitis was managed by either topical antihistaminics, ketorolac or steroids, depending on the severity. Additionally, Olopatadine eye drops (0.1% W/V) were used in vernal catarrh. Antibiotic eye drops were used in bacterial conjunctivitis.

Oral and/or topical acyclovir was used according to recommended doses in clinically diagnosed Herpes zoster and simplex infections. Conjunctival biopsy was advised for suspected Ocular Cicatricial Pemphigoid. Dry eyes were diagnosed with the help of history and ocular examination. Tear-film Break Up Time (TBUT) and Schirmer's tests were performed when necessary. Modification of environmental factors such as proper height of computer screens, taking frequent breaks while working on computer screens, use of humidifiers were suggested. Supportive treatment was advised along with ocular lubrication depending upon severity.

Pterygia that were progressive and/or causing discomfort were treated by excision and conjunctival autografts. Chemical injuries were managed by thorough irrigation with normal saline, assessment of damage, and timely treatment with topical antibiotics, steroids, cycloplegics and anti-glaucoma medication when needed.

Fornix maintenance, avoidance of corneal exposure and treatment of infections were advised in Stevens-Johnson syndrome along with management of other systemic problems.

Hypertonic saline eye drops (5%) along with ointment (6%) and bandage contact lenses were used in bullous keratopathy. Keratoplasty was advised for patients that did not respond.

Scraping from corneal ulcers was subjected to gram staining, KOH mount and bacterial culture, and fungal culture when necessary. Treatment was initiated with Ofloxacin eye drops (0.3%) and fortified gentamycin eye drops in suspected bacterial ulcers, and topical Natamycin 5% or Itraconazole 1% in suspected fungal keratitis. Atropine eye ointment 1% and supporting measures were also advised. Lachrymal sac syringing was performed in all

cases of corneal ulcers to know the patency of lachrymal passages. Anti-glaucoma drugs were administered whenever needed.

Peripheral keratitis was managed by proper lid hygiene, azithromycin ointment and topical prednisolone acetate 1% eye drops. Topical steroids and atropine were prescribed in Mooren's ulcer.

Filamentary keratitis was treated by withdrawal of all topical medication, removal of filaments and lubrication. Acute dacryocystitis was managed with systemic antibiotics and anti-inflammatory drugs along with hot fomentation. Lachrymal abscess was drained. Either dacryocystectomy or dacryocystorhinostomy was performed in cases of chronic dacryocystitis.

RESULTS

A total of 1200 patients with ocular surface disorders were enrolled for this study, of which there were 625 males and 575 females. Their ages ranged from one year to 100 years (mean age 42.27 ± 41.44 years) as shown in Table 1.

There were 17 different types of ocular disorders observed in these patients, and their distribution is illustrated in Figure 1. Blepharitis was seen as the commonly observed lid disorder, and the distribution of anterior infective, anterior seborrheic and posterior blepharitis in patients is shown in Figure 2.

The distribution of different etiological types of conjunctivitis is depicted in Figure 3. The age distribution of patients with allergic conjunctivitis is shown in Table 2.

There were 105 patients (55.26%) with seasonal allergic conjunctivitis, 49 (25.78%) with perennial allergic conjunctivitis, and 36 patients (18.94%) with vernal catarrh. Table 3 shows the age and sex distribution of patients with vernal catarrh, and the age and sex distribution of patients with dry eyes is presented in Table 4.

Of the 292 cases with dry eyes, conjunctivochalasis was observed in 23. History of systemic and/or ocular medication use was there in 57 patients, 21 had diabetes mellitus, 24 were computer professionals while six had conjunctival xerosis; one person had a graft versus host reaction after bone marrow transplantation.

There were 129 patients with pterygium, whose age and sex distribution is presented in Table 5.

There were 55 patients with viral keratitis. Among these, nine patients had features of Herpes zoster Ophthalmicus with keratitis, seven had dendritic ulcer with decreased corneal sensation as in herpes simplex infection and others had epidemic follicular conjunctivitis.

Forty-seven patients had corneal ulcer (Suppurative Keratitis). Table 6 shows their age and sex distribution, and Figure 4 depicts culture results.

There were 13 cases of chemical injury. The age ranged from 25 years to 35 years. Seven cases had injury by alkali and six cases by acidic agent as shown in Table 7. There were 20 cases of dacryocystitis, as shown in Figure 5.

Age in Years	No. of Cases	Percentage
1-20	217	18.06%
21-40	382	31.80%
41-60	342	28.47%
61-80	242	20.14%
Above 80	18	1.49%

Table 1. Age Distribution of Patients with Ocular Surface Diseases

Age in Years	Cases	Percentage
1-10	42	21.98%
11-20	94	49.21%
21-30	36	18.84%
31-40	10	5.23%
More than 40	8	4.71%

Table 2. Age Distribution of Patients with Allergic Conjunctivitis

Age Groups in Years	Males	Percentage	Females	Percentage	Total	Percentage
10-20	7	50%	21	95.45%	28	77.77%
Above 20	7	50%	1	4.54%	8	22.22%
Total	14	100%	22	100%	36	100%

Table 3. Age and Sex Distribution of Patients with Vernal Catarrh

Age in Years	Males	Percentage	Females	Percentage	Total	Percentage
1-20	8	4.93%	4	3.07%	12	4.10%
21-40	21	12.96%	20	15.38%	41	14.04%
41-60	45	27.77%	44	33.84%	89	30.47%
61-80	79	48.76%	55	42.30%	134	45.89%
More than 80	9	5.55%	7	5.38%	16	5.47%

Table 4. Age and Sex Distribution of Dry Eye Patients

Age in Years	Males	Percentage	Females	Percentage	Total	Percentage
20-30	3	6.25%	6	7.40%	9	6.97%
31-40	12	25%	13	16.04%	25	19.37%
41-50	17	35.41%	24	29.62%	41	31.78%
51-60	7	14.58%	24	29.62%	31	24.03%
More than 60	9	18.75%	14	17.28%	23	17.82%

Table 5. Age and Sex Distribution of Pterygium

Age in Years	Males	Females	Total
10-20	1	0	1
21-30	0	0	0
31-40	1	1	2
41-50	4	7	11
51-60	4	6	10
61-70	6	7	13
More than 70	5	5	10

Table 6. Age and Sex Distribution of Corneal Ulcer

Sex	Acid	Alkali
Female	3	1
Male	3	6

Table 7. Types of Chemical Injuries

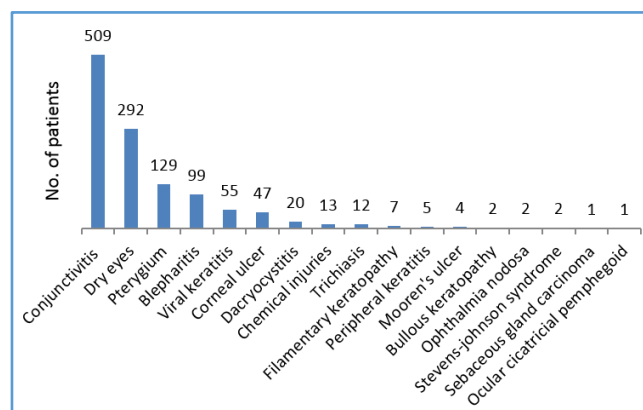


Figure 1. Observed Types of Ocular Surface Disorders

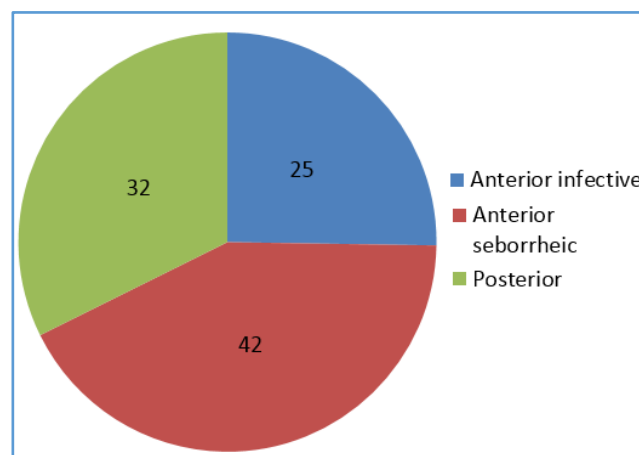


Figure 2. Types of Blepharitis Observed in Patients

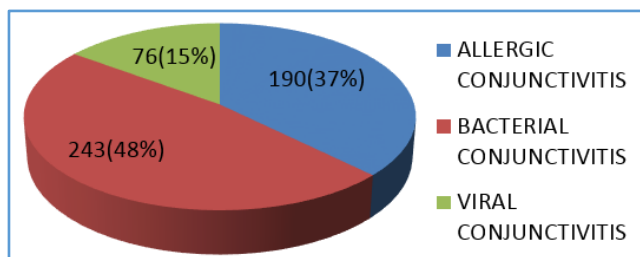


Figure 3. Distribution Types of Conjunctivitis in Patients

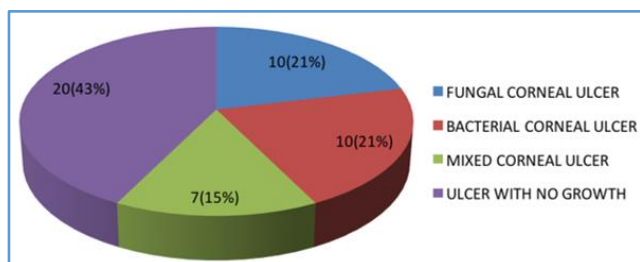


Figure 4. Culture Results of Corneal Ulcer

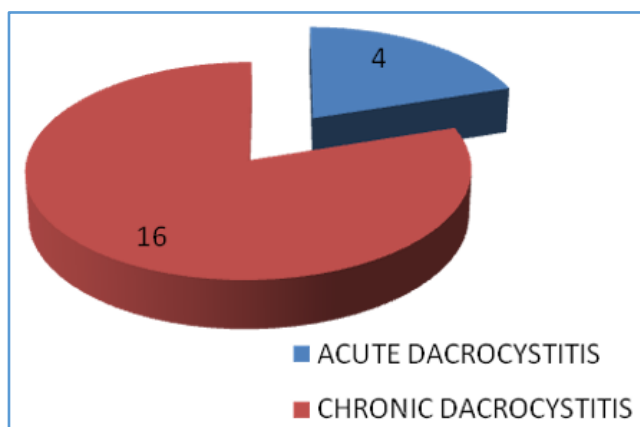


Figure 5. Types of Dacryocystitis

DISCUSSION

An unstable ocular surface can lead to various forms of ocular dysfunction. This is a comprehensive study where all the ocular surface disorders involving lids, conjunctiva, cornea and ocular adnexa were analysed together.

Around 60% of patients with ocular surface disorders were in the economically productive age group (21 to 60 years) with a possibility of lowered work efficiency and quality of life.

Blepharitis, sebaceous gland carcinoma and trichiasis were the diseases affecting lids. The role of doxycycline and azithromycin in restoring carotenoids in meibum and stability of tear film is stated by Foulks GN et al.² This treatment also helped our patients.

Sebaceous Gland Carcinoma diagnosed at our institute was managed elsewhere as recurrent chalazion. There have been various studies wherein SGC masqueraded chalazion.³

No steroid was used in bacterial conjunctivitis patients. Karen K Yeung et al. have mentioned the controversial role of antibiotic steroid combination to reduce scarring in bacterial conjunctivitis.⁴ Povidone-iodine 1.25% ophthalmic

solution is recommended by Isenberg SJ et al. as an alternative to topical antibiotics in infective conjunctivitis.⁵

In the present study, 22(61.11%) females had vernal catarrh. Kansakar I. states the male to female ratio as 4: 1 in Vernal Catarrh.⁶ As there were very few cases of Vernal Catarrh reported in our study, the male to female ratio may not be the true representation.

The overall prevalence of dry eyes reported in various studies ranges from 14.5 % to 29.25%.⁷⁻¹⁰ In our study, we observed 24.31% patients with dry eyes. About 81.84% of patients with DED were older than 40 years of age. This is similar to the study reported by Sahai et al.⁹ More males (M:F=162:130) had dry eyes as shown in Table. 4; contrary to the observation made by Moss et al. and Basak et al., where they observe that dry eyes are more common in females.^{7,8} Fifty-seven patients with DED had history of use of systemic and/or ocular medication. Topical Benzalkonium Chloride (BAC) as a preservative and anti-glaucoma drugs having preservatives other than BAC, preservative free eye drops as well and role of complicated drug interaction in precipitating dry eyes is discussed by Frederick et al.¹¹ The patients in our study were using eye drops with and without preservatives for a long time ranging from one to six months. None of the patients in our study had dry eyes secondary to Sjogren’s syndrome or collagen vascular diseases.

Twenty-one dry eye patients had diabetes mellitus. Manaviat et al. reported an incidence of 54.3% dry eyes in type 2 diabetes. Various other studies too have reported association of dry eyes and tear film dysfunction in diabetic patients.¹²

Twenty-four computer professionals had dry eyes. Yuichi Uchino et al have discussed role of decreased mucin5AC (MUC5AC) concentration in tears in video display terminal users for dry eye symptoms.¹³ Twenty-three dry eye patients had conjunctivochalasis. H. Pult et al. have stressed the importance of looking for nasal Lid Parallel Conjunctival Folds (LPCOF) in early detection of dry eyes.¹⁴

Two among the six patients with conjunctival xerosis were aged above 20 years. None had liver disease or cystic fibrosis. Though Vitamin A levels were not estimated, all patients responded well to dietary advice and lubricants. Conjunctival xerosis has been reported in cystic fibrosis of pancreas in patients above the age of 12 years by Neugebauer et al.¹⁵

There was one patient who had received bone marrow transfusion for acute myeloid leukemia (AML) in 2011. The patient presented with severe dry eyes and had poor response to tear substitutes. E M Rocha et al. have reported two cases of Graft Versus Host Disease having severe dry eyes not responding to conventional therapy.¹⁶ Our patient was comfortable after the use of autologous serum along with tear substitutes. Hussain M et al. have stated the benefits of autologous serum in dry eyes.¹⁷

Pterygium was seen more in females (62.80%) The affected females worked outdoors in the fields. Salagar KM et al. have linked outdoor work to the occurrence of pterygium.¹⁸

In patients of Ophthalmia nodosa the lodging of the hair in the conjunctiva may be due to possibility of crawling of the caterpillar near the eye as practice of sleeping on the floor is common in rural area. Ocular surface damage, caterpillar hair in vitreous and even possibility of panophthalmitis is reported in various studies.^{19,20}

We suspected ocular cicatricial pemphigoid in a 57-year-old female who had shortening of fornices with recurrent episodes of conjunctival redness. Biopsy and immunohistochemistry (IHC) studies were advised to confirm the diagnosis.^{21,22} Unfortunately, the patient did not show up.

Five patients with corneal ulcer had history of removal of corneal foreign body by tongue which is common practice in the rural area. Nikhil Gokhale has discussed the lowered efficacy of newer fluoroquinolones to control gram negative infections.²³ Therefore fortified gentamycin eye drops along with ofloxacin were used to manage bacterial keratitis.

Filamentary keratitis patients were better after withdrawal of medication, removal of filaments and lubrication with preservative free tear substitutes. Albiets J et al. have stated that prolonged use of topical and/or systemic medication can induce filamentary keratitis. The authors have also mentioned the beneficial effects of mechanical removal of filaments and preservative free tear substitutes on the condition.²⁴ Hidetoshi Tanioka et al. too have associated filamentary keratitis with ocular surface inflammation.²⁵

Amongst the five peripheral keratitis patients, three had marginal keratitis with blepharitis and two had phlyctenular keratoconjunctivitis. The phlyctenular keratoconjunctivitis patients had no evidence of tuberculosis. Mozayeni et al. and Gautam et al. have reported staphylococcal and other organismal antigens to cause phlyctenular conjunctivitis.^{26,27}

No systemic involvement was observed in Mooren's ulcer as stressed by Sangwan et al.²⁸ Bullous keratopathy was a complication of cataract surgery. Acid injuries were with domestic cleaning agents or accidental injury by battery acid. Alkali injuries were caused by lime consumed frequently along with tobacco in rural areas or injury by cement and lime at building sites. Patients with Stevens-Johnson syndrome had used oral paracetamol for fever. It is reported that drugs like paracetamol raise the risk of development of Stevens-Johnson syndrome.²⁹

Defective tear clearance is present in dacryocystitis. Friedrich Paulsen et al. have described impact of defective clearance of tears on the ocular surface.³⁰

CONCLUSION

A wide range of diseases affect the ocular surface that compromise integrity and functional efficiency of the eye. This study has shed light on the need for timely detection and management of ocular surface diseases to alleviate the patient's suffering, as well as to prevent blindness in certain cases.

Acknowledgement

We sincerely thank Dr. Awanti Sambarey for suggesting corrections in the manuscript and Dr. Urmila Diwekar for library access.

REFERENCES

- [1] Lee WB, Mannis MJ. Historical concepts of ocular surface disease. In: Holland EJ, Mannis MJ, Lee WB, eds. Ocular Surface disease: cornea, conjunctiva and tear film. 1st edn. London: W.B. Saunders 2013:3-10.
- [2] Foulks GN, Borchman D, Yappert M, et al. Topical azithromycin and oral doxycycline therapy of meibomian gland dysfunction: a comparative clinical and spectroscopic pilot study. *Cornea* 2013;32(1):44-53.
- [3] Nemoto Y, Arita R, Mizota A, et al. Differentiation between chalazion and sebaceous carcinoma by noninvasive meibography. *Clin Ophthalmol* 2014;8:1869-1875.
- [4] Yeung K, Weissman B. Bacterial conjunctivitis (pink eye) treatment & management. Los Angeles emedicine. [medscape.com/article/1191730-treatment](https://emedscape.com/article/1191730-treatment) (updated: Oct 05, 2017). <https://emedscape.com>
- [5] Isenberg SJ, Apt L, Valenton M, et al. A controlled trial of povidone-iodine to treat infectious conjunctivitis in children. *Am J Ophthalmol* 2002;134(5):681-688.
- [6] Kansakar I. Profile of vernal keratoconjunctivitis in Nepal: a hospital based study. *Nepal Med Coll J* 2011;13(2):92-95.
- [7] Moss SE, Klein R, Klein BE. Prevalence of and risk factors for dry eye syndrome. *Arch Ophthalmol* 2000;118(9):1264-1268.
- [8] Basak SK, Pal PP, Basak S, et al. Prevalence of dry eye diseases in hospital-based population in West Bengal, Eastern India. *J Indian Med Assoc* 2012;110(11):789-794.
- [9] Sahai A, Malik P. Dry eye: prevalence and attributable risk factors in a hospital-based population. *Indian J Ophthalmol* 2005;53(2):87-91.
- [10] Gupta N, Prasad I, Jain R, et al. Estimating the prevalence of dry eye among Indian patients attending a tertiary ophthalmology clinic. *Ann Trop Med Parasitol* 2010;104(3):247-255.
- [11] Fraunfelder FT, Sciubba JJ, Mathers WD. The role of medications in causing dry eye. *J Ophthalmol* 2012;2012:1-8.
- [12] Manaviat MR, Rashidi M, Afkhami-Ardekani M, et al. Prevalence of dry eye syndrome and diabetic retinopathy in type 2 diabetic patients. *BMC Ophthalmol* 2008;8:10.
- [13] Uchino Y, Uchino M, Yokoi N, et al. Alteration of tear mucin 5AC in office workers using visual display terminals: the Osaka study. *JAMA Ophthalmol* 2014;132(8):985-992.
- [14] Pult H, Purslow C, Murphy PJ. The relationship between clinical signs and dry eye symptoms. *Eye (Lond)* 2011;25(4):502-510.

- [15] Neugebauer M, Vernon S, Brimlow G, et al. Nyctalopia and conjunctival xerosis indicating vitamin A deficiency in cystic fibrosis. *Eye (Lond)* 1989;3(Pt 3):360-364.
- [16] Rocha EM, Pelegrino FS, De Paiva CS, et al. GVHD dry eyes treated with autologous serum tears. *Bone Marrow Transplant* 2000;25(10):1101-1103.
- [17] Hussain M, Shtein RM, Sugar A, et al. Long-term use of autologous serum 50% eye drops for the treatment of dry eye disease. *Cornea* 2014;33(12):1245-1251.
- [18] Salagar KM, Biradar KG. Conjunctival autograft in primary and recurrent pterygium: a study. *J Clin Diagn Res* 2013;7(12):2825-2827.
- [19] Sethi PK, Dwivedi N. Ophthalmia nodosa. *Indian J Ophthalmol* 1982;30(1):11-14.
- [20] Joshi D. Ophthalmia nodosa with intraocular caterpillar setae. *Med J Armed Forces India* 2011;67(2):167-168.
- [21] Mondino BJ, Brown SI, Lempert S, et al. The acute manifestations of ocular cicatricial pemphigoid: diagnosis and treatment. *Ophthalmology* 1979;86(4):543-552.
- [22] Power WJ, Neves RA, Rodriguez A, et al. Increasing the diagnostic yield of conjunctival biopsy in patients with suspected ocular cicatricial pemphigoid. *Ophthalmology* 1995;102(8):1158-1163.
- [23] Gokhale NS. Medical management approach to infectious keratitis. *Indian J Ophthalmol* 2008;56(3):215-220.
- [24] Albiets J, Sanfilippo P, Troutbeck R, et al. Management of filamentary keratitis associated with aqueous-deficient dry eye. *Optom Vis Sci* 2003;80(6):420-430.
- [25] Tanioka H, Yokoi N, Komuro A, et al. Investigation of the corneal filament in filamentary keratitis. *Invest Ophthalmol Vis Sci* 2009;50(8):3696-3702.
- [26] Mozayani R, Lam S. Phlyctenular keratoconjunctivitis and marginal staphylococcal keratitis. In: Krachmer J, Mannis M, Holland E, eds. *Cornea*. Vol. 2. St Louis, Missouri: Mosby - Year Book Inc 1997:1389-1395.
- [27] Gautam P, Shrestha GS, Sharma AK. Phlyctenular keratoconjunctivitis among children in the tertiary eye hospital of Kathmandu, Nepal. *Oman J Ophthalmol* 2015;8(3):147-150.
- [28] Sangwan VS, Zafirakis P, Foster CS. Mooren's ulcer: current concepts in management. *Indian J Ophthalmol* 1997;45(1):7-17.
- [29] Biswal S, Sahoo SS. Paracetamol induced Stevens-Johnson syndrome-toxic epidermal necrolysis overlap syndrome. *Int J Dermatol* 2014;53(8):1042-1044.
- [30] Paulsen FP, Corfield AP, Hinz M, et al. Characterization of mucins in human lacrimal sac and nasolacrimal duct. *Invest Ophthalmol Vis Sci* 2003;44(5):1807-1813.