

## OCULAR ISCHAEMIC SYNDROME- A CASE STUDY

Rashmi Priyanka M<sup>1</sup>, S. Padmini<sup>2</sup>, K. Mohan Raj<sup>3</sup>

<sup>1</sup>Second Year Resident, Department of Ophthalmology, Sree Balaji Medical College and Hospital, Chromepet, Chennai.

<sup>2</sup>First Year Resident, Department of Ophthalmology, Sree Balaji Medical College and Hospital, Chromepet, Chennai.

<sup>3</sup>Professor and HOD, Department of Ophthalmology, Sree Balaji Medical College and Hospital, Chromepet, Chennai.

**HOW TO CITE THIS ARTICLE:** Priyanka RM, Padmini S, Raj MK. Ocular ischaemic syndrome- a case study. J. Evid. Based Med. Healthc. 2018; 5(5), 465-467. DOI: 10.18410/jebmh/2018/94

### PRESENTATION OF CASE

55 years old male presented to ophthalmology department in our hospital with the complaints of an insidious onset of gradually progressive visual loss and pain in right eye since 3 months. Left eye was normal. He was a non-smoker but alcoholic and is not a known case of hypertension. He was recently diagnosed with Diabetes mellitus and is a known case of dyslipidemia (Total cholesterol-234 mg/dl, TGL-269 mg/dl, HDL-30 mg/dl, LDL- 150.2 mg/dl, VLDL-53.8 mg/dl, Total cholesterol / HDL ratio- 7.80, LDL/HDL ratio- 5.01). After examination his visual acuity in right eye was PL negative, left eye 6/12 and near vision less than N36. On admission his pulse was regular, his blood pressure was 120/70 mmHg. Other systems were normal. The ocular position of both eyes on forward gaze was fixed at the midline and extraocular movements were normal. The anterior segment examination showed rubeosis iridis in the right eye. Left eye was normal. Intraocular pressure was 20.6 mm Hg in the right eye and 17.3 mm Hg in the left eye. A dilated fundus examination of right eye showed neovascularization of disc, superficial hemorrhages and absent foveal reflex. Multiple microaneurysms and superficial haemorrhages were present in the posterior pole extending up to the mid periphery along with few cotton wool spots (Figure 1). Left eye fundus was normal.

Visual fields in right eye could not be done due to absence of perception of light whereas visual field in the left eye was normal. Carotid Doppler study showed right carotid bulb plaque with stenosis of 60% and bilateral internal carotid arteries showed echogenic material with minimal flow – suggestive of occlusion (Figure 3).

### DIFFERENTIAL DIAGNOSIS

The differential diagnosis of ocular ischaemic syndrome are Central retinal vein occlusion (CRVO): The age at which it occurs is variable. The retinal veins are dilated and tortuous. The hemorrhages are flame shaped and located in all quadrants in nerve fiber layer. Microaneurysms are uncommon, other microvascular abnormalities are opto-

*Financial or Other, Competing Interest: None.*

*Submission 10-01-2018, Peer Review 16-01-2018,*

*Acceptance 27-01-2018, Published 29-01-2018.*

*Corresponding Author:*

*Dr. K. Mohan Raj,*

*Professor and HOD,*

*Department of Ophthalmology,*

*Sree Balaji Medical College and Hospital,*

*Chromepet, Chennai.*

*E-mail: mohanrajdr@yahoo.com*

*DOI: 10.18410/jebmh/2018/94*



ciliary shunts and capillary dropouts. Hard exudates are rare. Optic disc edema is common. Central retinal artery perfusion pressure is normal. Fundus fluorescein angiography shows prolonged A-V transit time, in retinal vessel staining, veins are more stained than arteries. Macular edema is common and choroidal filling is normal.

**Diabetic Retinopathy-** It is characterized by microaneurysms, dot and blot hemorrhages, hard exudates which are commonly seen in posterior pole and mid-periphery. Intraretinal microvascular abnormalities and capillary dropout are also seen in some cases. FFA will show normal AV transit time and absence of retinal vessel staining. Choroidal filling will be normal. Macular edema is seen if central serous maculopathy is present.

**Hyperviscosity Syndrome-** serum or blood hyperviscosity will be present. Fundus picture will show optic disc swelling, enlarged retinal veins, retinal capillary microaneurysms, cotton wool spots and retinal hemorrhages. Sometimes areas of venous dilatation and venous occlusion may be seen.

OIS may also be associated with Giant cell arteritis, aortic arch syndrome, hyperhomocysteinaemia, thyroid orbitopathy, Takayasu's disease and scleroderma.

### CLINICAL DIAGNOSIS

OIS a rare condition associated with stenosis or occlusion of Internal carotid artery (ICA) which may result in ocular hypo perfusion and visual loss. Ocular ischaemic syndrome can be caused by arterial hypertension, diabetes mellitus, dyslipidemia and coronary artery disease. The symptoms are visual loss and pain. Decrease in visual acuity in OIS may be severe, with acute or subacute presentation.<sup>1,2,3</sup> Visual fields may vary from normal to central scotoma, centrocaecal scotoma, central or temporal island.<sup>4</sup> Increased Intra ocular pressure (IOP) or ischemia can cause ocular pain which is usually dull and constant in the affected eye, it may spread to orbit and upper face. It is usually worse in standing position and relieved on lying down. In elderly patients, Giant cell arteritis is to be ruled out. A history of transient visual loss is present in approximately 10–15% of patients with OIS and is most frequently caused by transient embolization of the CRA or its branches, but vasospasm may also play a role. The signs of ocular ischaemic syndrome should be differentiated from central retinal vein occlusion and diabetic retinopathy. In OIS, the retinal veins are dilated but not tortuous and occurs between 50-80 years of age. Dot and blot hemorrhages are seen in mid-periphery and in

deeper retinal layers. Micro aneurysms are common and located in mid periphery. Macular telangiectasias, retinal AV communications and capillary dropout are seen. There are no hard exudates. Optic disc is normal and central retinal artery perfusion pressure is decreased.

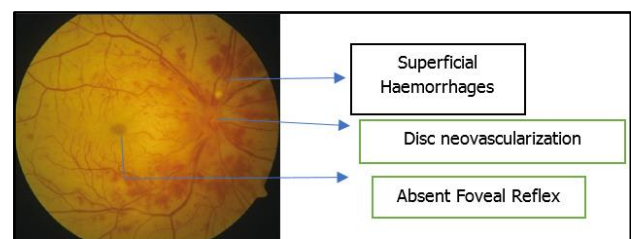
Ocular hypoperfusion is most frequently due to severe carotid artery stenosis or occlusion. The major cause and for OIS is atherosclerosis of the carotid vascular system and this may be the initial manifestation.<sup>5,6,7</sup> Other possible causes are the Takayasu syndrome, ophthalmic artery stenosis, vasospasm and giant cell arteritis. In these cases, the vascular obstruction can occur anywhere proximal to the point where the central retinal and ciliary arteries branch from the ophthalmic artery.<sup>8</sup> Systemic hypertension and diabetes mellitus are more commonly seen in patients with OIS. In this case, the patient is newly diagnosed diabetic and not a hypertensive. He is known case of dyslipidemia. In a patient presenting with ocular ischaemic syndrome, careful general physical examination should be done to rule out ocular manifestations of a more serious systemic disease.

The possibility of Takayasu arteritis should be considered in ocular ischaemic syndrome when presenting in a young woman. Fundus fluorescein angiogram plays an important role in diagnosing ocular ischaemic syndrome and guiding therapy. Ocular ischaemic syndrome can be confused with Diabetic Retinopathy (DR) and Central retinal vein occlusion (CRVO). Patients with DR tend to have bilateral involvement and affect all age groups, whereas Ocular ischaemic syndrome is more often unilateral and affect older patients in their 50s and 80s. Hard exudates are common in DR, but usually absent in ocular ischaemic

syndrome. CRVO and ocular ischaemic syndrome both tend to affect older patients. In contrast to ocular ischaemic syndrome, CRVO may show optic disc swelling and more pronounced macular edema. On FFA, in CRVO there is no defect in choroidal filling pattern and vessel staining is mostly venous whereas it is predominantly arterial in ocular ischaemic syndrome.

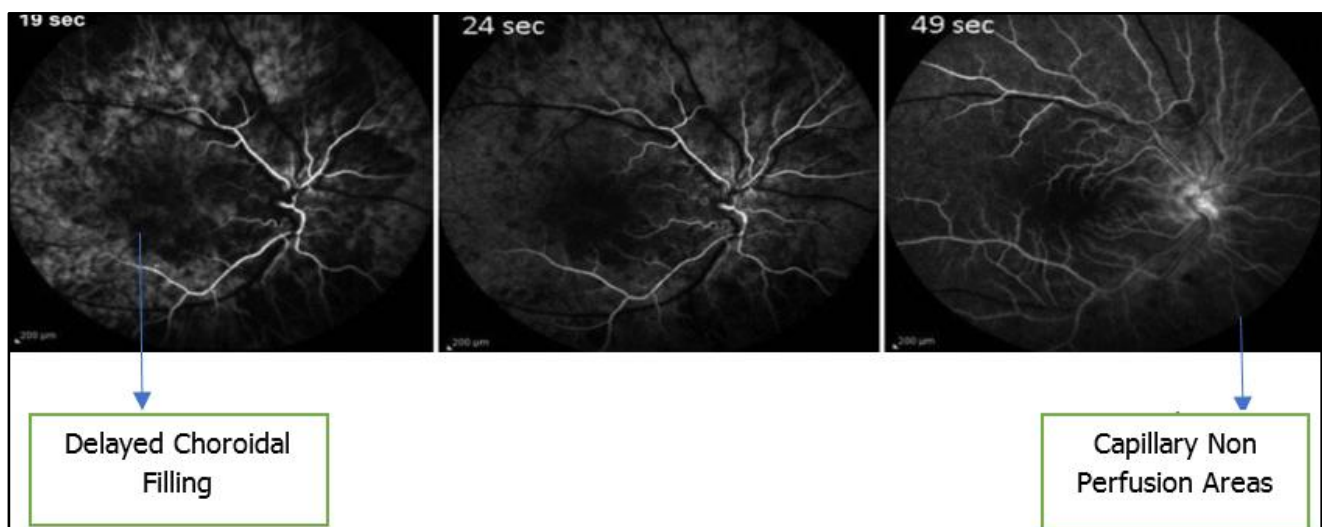
Investigations revealed dyslipidemia and newly detected Diabetes mellitus.

Anterior segment examination showed rubeosis iridis in right eye. A dilated fundus examination of right eye showed neovascularization of disc, superficial hemorrhages and absent foveal reflex. Multiple microaneurysms and superficial haemorrhages were present in the posterior pole extending up to the mid periphery along with few cotton wool spots.



**Figure 1. Fundus Picture**

Fundus fluorescein angiography (FFA) showed delayed choroidal filling and prolonged arteriovenous transit, retinal capillary non-perfusion at 19, 24 and 49 secs. (Figure 2)



**Figure 2. FFA Showing Delayed Choroidal Filling, Prolonged Arteriovenous Transit and Capillary Non-Perfusion**

Doppler study of carotid and vertebral vessels revealed bilateral intima medial complex of CCA show mild thickening, right carotid bulb plaque with stenosis of 60% and bilateral internal carotid arteries show echogenic material with minimal flow – suggestive of occlusion of right ICA.



**Figure 3. Doppler Showing Occlusion of Right ICA with Atheromatous Plaque**

### DISCUSSION OF MANAGEMENT

The management involves treating the ocular complications and preventing further damage. All the cases have to be investigated for associated vascular risk factors and have to be treated accordingly. As for as eyes are concerned, anterior segment inflammation, retinal ischemia, increased IOP and neovascular glaucoma have to be treated. Steroids and cycloplegics have to administered. Glaucoma is to be treated by medical management. If neovascular glaucoma is present, trabeculectomy with antimetabolites or aqueous shunt have to be considered. Panretinal photocoagulation or transconjunctival cryotherapy or trans scleral diode laser treatment may be needed in some patients.<sup>9,10</sup> Intravitreal anti vascular endothelial growth factors and triamcinolone may be needed in cases with cystoids macular edema. All cases need neurological examination.

### SURGICAL TREATMENT

Carotid artery endarterectomy, carotid artery stenting, Extracranial-Intracranial (EC-IC) Arterial Bypass Surgery may be needed in selective cases.<sup>11</sup> In our case, the patient was given low dose aspirin and referred to cardiology department for further management.

### FINAL DIAGNOSIS

Based on the clinical presentation, fundus evaluation, laboratory investigations and Doppler study, our patient was diagnosed with ocular ischaemic syndrome. On further evaluation with Fundus Fluorescein Angiography (FFA), it strongly suggested ocular ischaemic syndrome with delayed choroidal filling and prolonged arteriovenous transit, retinal capillary non-perfusion. Hence, our final diagnosis was ocular ischaemic syndrome with unilateral presentation probably due to dyslipidemia due to ipsilateral carotid artery occlusion by atheromatous plaque.

### REFERENCES

- [1] Gordon N. Ocular manifestations of internal carotid artery occlusion. *Br J Ophthalmol* 1959;43(5):257-267.
- [2] Hedges TR. Ophthalmoscopic findings in internal carotid artery occlusion. *Am J Ophthalmol* 1963;55:1007-1012.
- [3] Bullock JD, Falter RT, Downing JE, et al. Ischemic ophthalmia secondary to an ophthalmic artery occlusion. *Am J Ophthalmol* 1972;74(3):486-493.
- [4] Mizener JB, Podhajsky P, Hayreh SS. Ocular ischemic syndrome. *Ophthalmology* 1997;104(5):859-864.
- [5] Marx JL, Hreib K, Choi IS, et al. Percutaneous carotid artery angioplasty and stenting for ocular ischemic syndrome. *Ophthalmology* 2004;111(12):2284-2291.
- [6] Beti NF, Mateo I, La Calle VD, et al. The ocular ischemic syndrome. *Clinical Neurology and Neurosurgery* 2003;106(1):60-62.
- [7] Sivalingam A, Brown GC, Magargal LE, et al. The ocular ischemic syndrome. II. Mortality and systemic morbidity. *Int Ophthalmol* 1989;13(3):187-191.
- [8] Ros MA, Magargal LE, Hedges TR, et al. Ocular ischemic syndrome: long-term ocular complications. *Ann Ophthalmol* 1987;19(7):270-272.
- [9] Flaxel CJ, Larkin GB, Broadway DB, et al. Peripheral transscleral retinal diode laser for rubeosis iridis. *Retina* 1997;17(5):421-429.
- [10] Bloom PA, Tsai JC, Sharma K, et al. Cyclodiode. Trans-scleral diode laser cyclophotocoagulation in the treatment of advanced refractory glaucoma. *Ophthalmology* 1997;104(9):1508-1519.
- [11] Neroev VV, Kiseleva TN, Vlasov SK, et al. Visual outcomes after carotid reconstructive surgery for ocular ischemia. *Eye* 2012;26(10):1281.