

MORPHOMETRIC ANALYSIS OF CORPUS CALLOSUM- A STUDY IN CADAVER AND MRI*Ambili Puthanveetil¹, Rakhin Kareparambil Balan²*¹Assistant Professor, Department of Anatomy, Government Medical College, Kozhikode.²Assistant Professor, Department of Forensic Medicine, Government Medical College, Thrissur.**ABSTRACT****BACKGROUND**

The Corpus Callosum (CC) can best be seen in the mid-sagittal section of brain both in cadaver and MRI. The morphometric measurements of the same will be of use in neurosurgical procedures. Sexual dimorphism and the age-related changes in its measurements remained controversial. Till date, no studies have been done on corpus callosum in Kerala.

MATERIALS AND METHODS

Measurements of CC has been taken and studied in detail in 24 formalin fixed brains from the Department of Anatomy and 48 MR images from the Department of Radiology. The changes according to age and sex were analysed.

RESULTS

The mean length of CC in the cadaver was 7.24 cm, which was 3.38 cm posterior to frontal pole and 5.73 cm anterior to occipital pole. In MR images, the mean length was 7.10 in males and 6.76 in females. The difference we got was not statistically significant. The length increased with age. Thickness of genu and body decreased as the age advances, but the splenial thickness was found to be increasing with age. There was significant correlation between the thicknesses of various parts of CC.

CONCLUSION

The values were almost similar to those in the previous studies. Morphometrically, a significant gender difference was not identified in the present study. There were changes according to age both in males and females.

KEYWORDS

Corpus Callosum, Cadaver, MRI, Morphometric Measurements.

HOW TO CITE THIS ARTICLE: Puthanveetil A, Balan RK. Morphometric analysis of corpus callosum- A study in cadaver and MRI. J. Evid. Based Med. Healthc. 2017; 4(53), 3219-3222. DOI: 10.18410/jebmh/2017/639

BACKGROUND

Corpus Callosum (CC) is the largest commissural pathway, which is a well-defined structure that can be seen in mid-sagittal section of brain. The purpose of the study was to measure the thickness of various parts of CC and its distance from the brain surface. They are of value in the surgical interventions and stereotactic approaches to the foramen of Monro or third ventricle and in cases of callosotomy for intractable epilepsy. MR imaging is used for preoperative determination of the extent of callosotomy for epilepsy as well as for postoperative evaluation, especially T1 weighted images. Most of the studies related to CC were done in Caucasians, but less in Asian subjects. A few studies have been reported from Indian population, but none in Keralites. The present study was done both in formalin fixed brain in cadavers and in the living using MRI.

Aim- To study the morphometry of corpus callosum and its distance from the surface of brain in cadaver and MR images.

Objectives

- To find out the thickness of various parts of corpus callosum.
- To find out the correlation between different parts of CC.
- To compare the size of CC with that of brain.
- To measure the distance of corpus callosum from the brain surface.
- To look for age and gender differences of CC.

MATERIALS AND METHODS

24 formalin fixed cadaver brains (20 males and 4 females) from the Department of Anatomy and 48 MR images (25 males and 23 females) from the Department of Radiology were used for the study.

In the cadaver, the measurements were taken from the medial surface of the cerebral hemisphere using dividers and read on an mm graduated scale.

In MRI, T1W images in mid sagittal plane were used. The measurements were taken using calipers from the screen directly.

The values were noted and the ratios with the brain size were calculated.

Exclusion Criteria

MRI with gross intracranial abnormality that can affect the measurements such as lipoma of CC, hydrocephalus, haemorrhage, tumours and dysgenesis of corpus callosum (partial or complete).

Financial or Other, Competing Interest: None.

Submission 16-06-2017, Peer Review 23-06-2017,

Acceptance 01-07-2017, Published 03-07-2017.

Corresponding Author:

Dr. Rakhin Kareparambil Balan,

Assistant Professor, Department of Forensic Medicine,

Government Medical College, Thrissur,

E-mail: ambilipambilip@rediffmail.com

DOI: 10.18410/jebmh/2017/639



The measurements taken were-

1. The thickness of genu (G).
2. Thickness of body (B).
3. Thickness of splenium (S).
4. The length of CC (L).
5. The height of CC (H).
6. The distance of genu from frontal pole.
7. The distance of splenium from the occipital pole.
8. The distance of body from superior medial border at the level of foramen of Monro.
9. The total length of the hemisphere from frontal to occipital pole.

Statistical analyses were done with SPSS, paired t-test and Pearson correlation analysis.

RESULTS

In the cadaver, the average length of CC was 7.24 cm, which was 46% of the length of cerebral hemisphere (mean length 15.6 cm). Average height of CC was 2.3 cm. CC was closer to the frontal pole (3.3 cm) than to the occipital pole (5.7 cm). Distance to the body from superior medial border was almost the same as the genu from the frontal pole (3.4 cm). The mean thickness of genu and splenium were the same (1.2 cm). The thickness of body was less when compared to them (0.7 cm) (Table 1).

All the cadavers were in 60 to 80 age group. Most of them were males. Only 4/24 specimens were female brains. Hence, the values were not analysed for age or sex difference in cadaveric specimens.

In MRI in the present study, the age group ranges from 3 years to 80 years.

The mean thickness of genu and splenium is 1.04 cm in males and 1.06 cm in females (range 0.9 to 1.2 cm) and the body is half the thickness of them, i.e. 0.46 cm both in males and females (range 0.4 to 0.6 cm).

The mean length of CC was 7.10 cm in males and 6.76 cm in females. Mean length was 43.8% of the total length of male

brain and 43.3% of female brain (mean distance between frontal to occipital pole was 16.2 cm in males and 15.6 cm in females).

The correlation among different parameters was done in males and females separately and a positive correlation was found between thicknesses of genu and splenium, genu and body, body and splenium and between length and height and length and splenial thickness in males (Table 2). In females, a significant positive correlation was present only between the genu and splenium and between height and length. There was no statistically significant correlation found between other parameters.

The thickness of various parts of CC was correlated with age and thickness of genu and body decreased with age. The splenial thickness increased with age. The length and height showed a gradual increase with aging (Figure 1).

The values were analysed for sex difference. No statistically significant difference was found between males and females for the measurements of CC (Table 3).

	Min. (cm)	Max. (cm)	Mean	% of Brain Length
FP to OP	14	16.5	15.58	
Length of CC	6.5	7.7	7.24	46.46%
G to FP	2.8	3.5	3.28	21.05%
S to OP	5	6.3	5.73	36.78%
B to SM at F M	3	3.8	3.35	21.15%
Height of CC	1.9	2.6	2.3	14.76%
Genu	1	1.3	1.16	7.45%
Body	0.5	0.7	0.65	4.17%
Splenium	1	1.3	1.16	7.45%

Table 1. Measurements of CC and its Distances from Brain Surface Obtained from Cadavers

G: genu, S: splenium, B: body, FP: frontal pole, OP: occipital pole, SM: superior medial border, FM: Foramen of Monro.

Male	Genu	Body	Splenium	Length	Female	Genu	Body	Splenium	Length
Genu	1				Genu	1			
	23					25			
Body	0.531 (**)	1			Body	0.161	1		
	0.009					0.441			
	23	23				25	25		
Splenium	0.604 (**)	0.538 (**)	1		Splenium	0.577 (**)	-0.028	1	
	0.002	0.008				0.003	0.893		
	23	23	23			25	25	25	
Length	0.022	0.341	0.535 (**)	1	Length	0.330	-0.238	0.384	1
	0.919	0.111	0.008			0.108	0.252	0.058	
	23	23	23	23		25	25	25	25
Height	-0.202	0.412	0.193	0.610 (**)	Height	-0.071	-0.017	-0.006	0.592 (**)
	0.356	0.051	0.378	0.002		0.738	0.935	0.979	0.002
	23	23	23	23		25	25	25	25

Table 2. Correlation between Parameters of CC (MRI) in Males and Females Separately

** Correlation is significant at the 0.01 level (2-tailed).

* Correlation is significant at the 0.05 level (2-tailed).

Genu		N	Mean	Std. D	t	P
	Male	23	1.04	0.19	-0.491	0.626
Body	Female	25	1.06	0.16		
	Male	23	0.46	0.10	-0.262	0.795
Splenium	Female	25	0.47	0.10		
	Male	23	1.03	0.21	1.189	0.24
Length	Female	25	0.96	0.15		
	Male	23	7.10	0.59	1.723	0.092
Height	Female	25	6.76	0.79		
	Male	23	2.32	0.28	0.777	0.441
	Female	25	2.25	0.33		
	Male	23				

Table 3. Measurements of CC Obtained from MR Images Analysed for Sex Difference

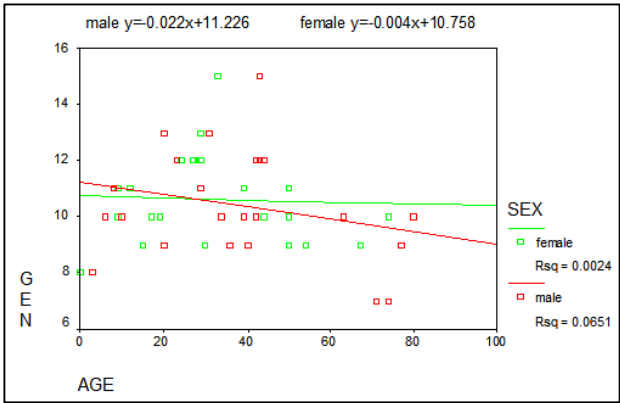


Figure 1a. Genu

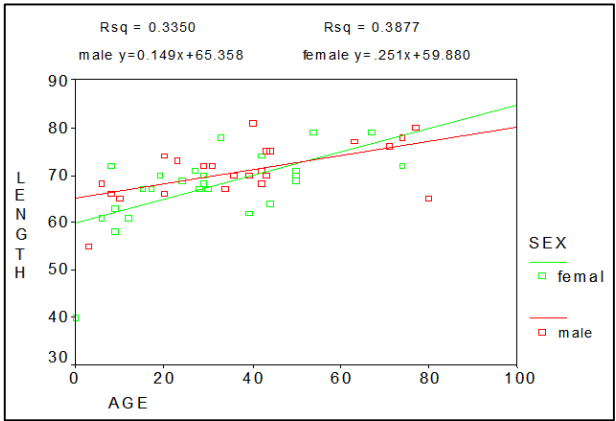


Figure 1d. Length

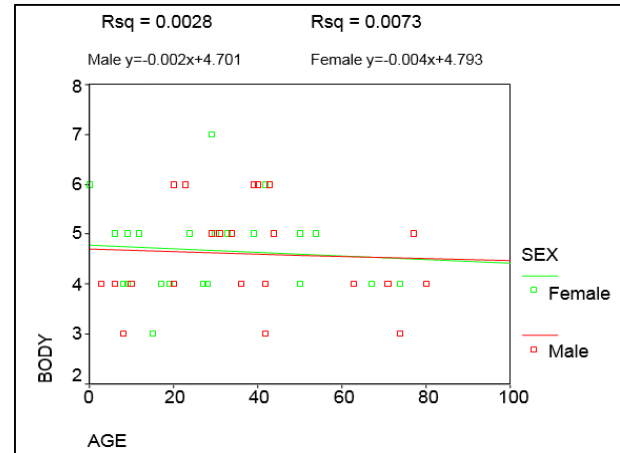


Figure 1b. Body

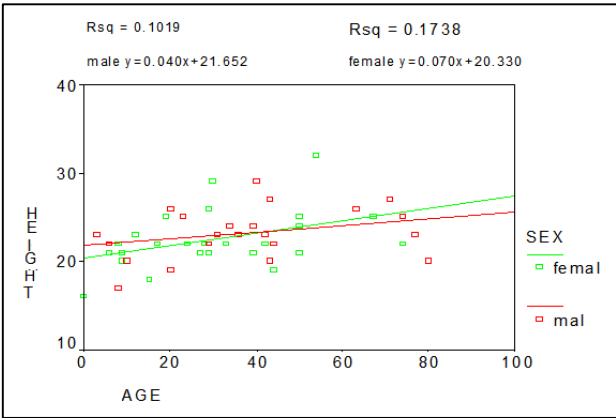


Figure 1e. Height

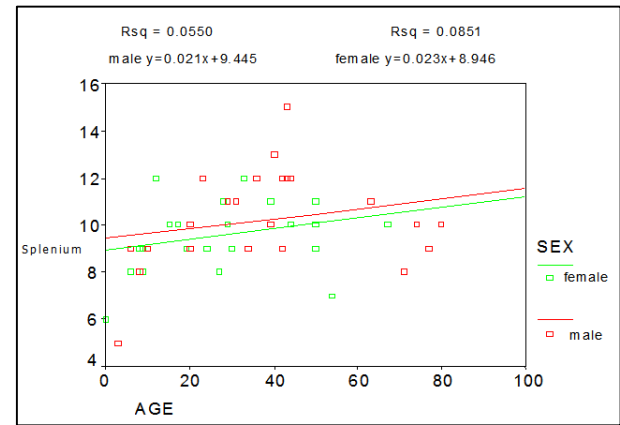


Figure 1c. Splenium

Figure 1 (a-e). Change in Measurements of CC According to Age.

DISCUSSION

The CC is the largest commissure in the brain and can be easily identified both in gross specimen and MR images. It consists of the white matter fibres connecting different parts of cerebral cortex of two hemispheres across the midline. The fibres have a topographic arrangement in the CC like inferior frontal and anteroinferior parietal fibres passes through the genu, rest of the frontal and parietal lobes pass through the body. The temporal and occipital fibres pass through the splenium.

The cadaveric studies related to the CC starts from 1982 after the observation of a sexual dimorphism in the splenium of CC by de Lacoste Utamsingh.¹ According to him, the splenium was larger and more bulbous in females. A lot of

studies had been done afterwards on morphology and morphometry of CC in cadaver in relation to the gender, but the results were controversial.^{2,3,4,5}

The length of CC was 7.2 cm in the present study, goes hand in hand with the previous studies^{2,3} except in Srilankan males where the measurement was 8.03 cm.⁴ Thickness of genu and splenium was 1.16 cm and was close to the values obtained in other studies¹⁻⁵ except the splenial width in females observed by de Lacoste, which was 1.64 cm. Width of the body was same compared to the study by Gokarn I.A.

The development of CC had been studied in foetal specimens and found that genu was the first to appear, then the body and then splenium. Rostrum was the last to develop and it is completed by about 20 weeks of intrauterine life.⁶ The thickness of different parts of CC gradually increases after birth according to the area being developed.

Several studies had been done in MRI to analyse the CC using various methods hoping to solve the debate of gender difference and to know the changes according to age.^{7,8,9,10} The studies using MRI had the advantage of obtaining the callosal measurements, which were not affected either by postmortem changes or formalin fixation. Some researchers tried to find out differences in measurements of CC in normal individuals according to their handedness, their abilities like music¹¹ and in twins.¹²

The present study has collected data from 3 years to 80 years. It did not take into account the handedness, their abilities like music or alcoholism. Similar study was done by S Takeda et al in 9 to 86 yrs. age group⁷ and the results are similar to the present study except for the correlation between splenial thickness and age. In other studies, the results varies in parameters, which includes an increase in all the measurements except genu⁸ decrease in thickness of body¹⁰ and an increase only in length^{13,14,15} according to age. The callosal measurements in the present study were almost the same with the previous studies. The difference if any comes from the difference in the age group selected for the study. The thickness of splenium ranged between 0.96 and 1.17 in all the studies. No study supports the high value of de Lacoste (1.64 cm). But, sexual dimorphism was supported by some authors^{4,8} though most of the previous studies deny a sexual difference similar to the present study.

CONCLUSION

The thickness of different parts of CC, its length and height are measured from both cadaver and MR images and compared with the brain size. The distance of different parts of CC was measured from the brain surface. The values from MR images were analysed for difference in age and sex. All these measurements will be of use in the neurosurgery for surgical and stereotactic approaches to the CC itself or the ventricles of brain (3rd ventricle or interventricular foramen of Monro). It can also be used in analysing the changes in neurological diseases.

REFERENCES

- [1] DeLacoste-Utamsingh C, Holloway RL. Sexual dimorphism in the human corpus callosum. *Science* 1982;216(4553):1431-1432.
- [2] Going JJ, Dixon A. Morphometry of adult human corpus callosum: lack of sexual dimorphism. *J Anat* 1990;171:163-167.
- [3] Anagnostopoulou S, Mourgel S, Katritsi D. Morphometry of corpus callosum: an anatomical study. *Neuroanatomy* 2006;5:20-23.
- [4] Isurani I, Ganananda N, Nadeeka P. Gross anatomical study on gender difference in corpus callosum. *Galle Medical Journal* 2009;14(1):22-25.
- [5] Gupta T, Singh B, Kapoor K, et al. Normative data of corpus callosal morphology in a north-west Indian population-an autopsy and MRI study. *J Nepal Med Assoc* 2009;48(173):46-51.
- [6] Hewitt W. The development of human corpus callosum. *J Anat Lond* 1962;96(3):355-358.
- [7] Takeda S, Hirashima Y, Ikeda H, et al. Determination of indices of the corpus callosum associated with normal aging in Japanese individuals. *Neuroradiology* 2003;45(8):513-518.
- [8] Kosar MI, Erdil FH, Sabanciogullari V, et al. Morphometry of corpus callosum related with gender and age- MRI study. *Pak J Med Sci* 2012;28(3):408-412.
- [9] Weis S, Kimbacher M, Wenger E, et al. Morphometric analysis of the corpus callosum using MR: correlation of measurements with aging in healthy individuals. *AJNR Am J Neuroradiol* 1993;14(3):637-645.
- [10] Ozdemir ST, Ercan I, Sevinc O, et al. Statistical shape analysis of differences in shape of the corpus callosum between genders. *The Anatomical Record* 2007;290(7):825-830.
- [11] Ozturak AH, Tascioglu B, Aktekin M, et al. Morphometric comparison of the human corpus callosum in professional musicians and non-musicians by using in vivo magnetic resonance imaging. *J Neuroradiol* 2002;29(1):29-34.
- [12] Casanova MF, Sanders RD, Goldberg TE, et al. Morphometry of the corpus callosum in monozygotic twins discordant for schizophrenia: a magnetic resonance imaging study. *J Neurol Neurosurg Psychiatry* 1990;53(5):416-421.
- [13] Suganthi J, Raghuram L, Antonisamy B, et al. Gender & age-related difference in the morphology of the corpus callosum. *Clin Anat* 2003;16(5):396-403.
- [14] Mohammadi MR, Zhand P, et al. Measurement of the corpus callosum using magnetic resonance imaging in the north of Iran. *Iran J Radiol* 2011;8(4):218-223.
- [15] Georgy BA, Hesselink JR, Jernigan TL. MR imaging of corpus callosum. *AJR* 1993;160(5):945-955.