

## MODIFIED MUCOSAL FLAP TECHNIQUE IN ENDOSCOPIC ENDONASAL DACRYOCYSTORHINOSTOMY

Samarapuri A<sup>1</sup>, Kavitha K<sup>2</sup>

<sup>1</sup>Associate Professor, Department of Ophthalmology, Government Medical College, Omandurar Government Estate, Chennai, Tamil Nadu.

<sup>2</sup>Assistant Professor, Department of Ophthalmology, Government Medical College, Omandurar Government Estate, Chennai, Tamil Nadu.

---

### ABSTRACT

---

#### BACKGROUND

The success rate of endonasal dacryocystorhinostomy with the modified flap technique is almost equivalent to that of external dacryocystorhinostomy. In the initial period, the nasal mucosal flap was excised in endoscopic endonasal dacryocystorhinostomy and the ridge of the bony ostium is left uncovered. This leads to outgrowth of the bony ostium which is the commonest cause for failure in endonasal dacryocystorhinostomy. In our modified technique, we have covered the bony ridge with nasal mucosal flap to prevent bony outgrowth and closure of the ostium.

The study was performed to evaluate the improvement in success rate following modified mucosal flap technique in endoscopic endonasal dacryocystorhinostomy (DCR).

#### MATERIALS AND METHODS

A prospective study was conducted on 28 patients in the age group of 20-60 years with distal nasolacrimal duct obstruction from January 2018-November 2018 at Chengalpattu Government Medical College Hospital. Investigations were done to rule out bleeding disorders. Diagnostic nasal endoscopy was done to look for deviated nasal septum, atrophic rhinitis and middle turbinate hypertrophy. Hypertensive patients were excluded. Endonasal dacryocystorhinostomy was done under infiltrative anaesthesia after nasal packing. A curvilinear incision was made from the attachment of middle turbinate to the attachment of inferior turbinate. The bony ostium was made and after lifting up the mucosa, the sac was opened anteriorly, medial wall being excised anteriorly. In the modified mucosal flap technique, splitting of the nasal mucosa into two halves to cover the trimmed bony edge was done.

#### RESULTS

In our study, females were most commonly affected and the common age group being 31-50 years. Success rate with modified mucosal flap technique was 92.86% as compared to the conventional mucosal flap technique (89.9%). We had failure rate of 7.14% due to synechiae formation. Distal stenosis from progressive healing and closure of the ostium was the common cause of failure in conventional mucosal flap technique.

#### CONCLUSION

Modified mucosal flap technique with splitting of the nasal mucosa into two halves to cover the trimmed bony edge has shown to improve the success rate in our study.

#### KEYWORDS

Dacryocystitis, Endonasal Dacryocystorhinostomy, Bony Ostium, Modified Mucosal Flap, Ostium Stenosis Prevention.

**HOW TO CITE THIS ARTICLE:** Samarapuri A, Kavitha K. Modified mucosal flap technique in endoscopic endonasal dacryocystorhinostomy. J. Evid. Based Med. Healthc. 2019; 6(10), 770-773. DOI: 10.18410/jebmh/2019/159

#### BACKGROUND

Dacryocystorhinostomy (DCR) is a surgical procedure performed for the relief of nasolacrimal duct obstruction of either anatomical or functional cause. This is done to increase the tear drainage by removing the lacrimal bone

*Financial or Other, Competing Interest: None.*

*Submission 28-02-2019, Peer Review 01-03-2019,*

*Acceptance 05-03-2019, Published 08-03-2019.*

*Corresponding Author:*

*Dr. K. Kavitha,*

*HF 4, Saffaron Heights,*

*No. 19, Pallava Garden,*

*Third Main Road, Zamin, Pallavaram,*

*Chennai- 600117, Tamil Nadu.*

*E-mail: kavithatuty@yahoo.co.in*

*DOI: 10.18410/jebmh/2019/159*



and incorporating lacrimal sac with lateral nasal mucosa. This can be achieved either by external or endoscopic endonasal approach.

External dacryocystorhinostomy has remained the 'gold standard' surgical technique for nasolacrimal duct obstruction with success rate of 90-95%.<sup>1</sup> Endoscopic endonasal DCR was first described in 1893 by Caldwell and its gaining popularity as it has distinct advantage of not disturbing anatomical attachment of the medial palpebral ligament so that lacrimal pump mechanism is preserved, ability to diagnose intranasal pathology like deviated nasal septum, nasal polyp, inferior turbinate hypertrophy and atrophic rhinitis. Another advantage is that it produces no scar on the face with less intraoperative bleeding.

Most studies on dacryocystorhinostomy show that the success rate of external dacryocystorhinostomy is always better compared to that of endoscopic endonasal dacryocystorhinostomy. This is due to inadequate bony ostium. Bony outgrowth from the bare edges of the bony ostium and closure of the ostium. Formation of granulation tissue and synechiae formation in the nasal mucosa also increases the failure rate in endoscopic dacryocystorhinostomy. To prevent these complications various techniques are followed out of which the modified mucosal flap technique has shown better success rate. This technique also preserves most part of the nasal mucosa so that function of the nasal mucosa is not much affected.

### Aim

To evaluate the improvement in success rate following modified mucosal flap technique in Endoscopic endonasal dacryocystorhinostomy.

This was a prospective study conducted on 28 patients with distal nasolacrimal duct obstruction (acute and chronic dacryocystitis) from January 2018- November 2018 in the ophthalmology department at Chengalpattu government medical college hospital. Post-operatively the patients were followed up for an average period of 6 months.

### Inclusion Criteria

We included all patients with acute on chronic dacryocystitis, mucocele of the lacrimal sac and chronic dacryocystitis in our study.

### Exclusion Criteria

Patients with history of previous lacrimal surgery or trauma with evidence of bony deformity, canalicular obstruction, septal deviation, atrophic rhinitis, nasal polyp, nasal malignancy and tuberculosis were excluded from our study. Systemic conditions like hypertension and bleeding diathesis were also excluded.

### MATERIALS AND METHODS

28 patients in the age group of 20 years-60 years with distal nasolacrimal duct obstruction underwent complete ophthalmological evaluation in our ophthalmology department at Chengalpattu government medical college from January 2018- November 2018. Lacrimal syringing and probing was done to assess the level of obstruction of nasolacrimal duct. Bleeding time and clotting time were done to rule out bleeding diathesis. Schirmer's test was done to rule out dry eye. Diagnostic nasal endoscopy was performed to look for deviated nasal septum, atrophic rhinitis and middle turbinate hypertrophy. All patients were operated under local anaesthesia.

### Procedure

Nasal packing was done fifteen minutes prior to surgery with 4% xylocaine with adrenaline (4:1). External and intranasal infiltrative anaesthesia with 2% lignocaine with 1 in 80000 adrenaline was given. Positioning of the patient with 15°

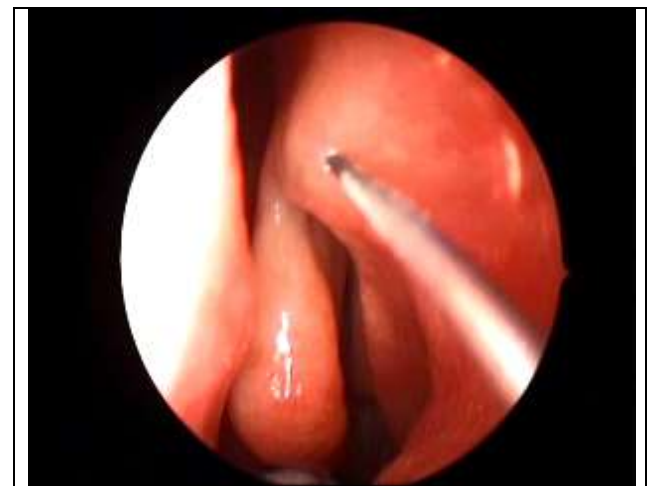head up tilt was done. 30° nasal endoscope was used. Postnasal packing was done with wet gauze.

A Curvilinear Incision was made over mucosa on lateral nasal wall using sickle knife, from the attachment of middle turbinate to the attachment of inferior turbinate with the width of approximately 1 cm and height of about 1.5 cm. The nasal mucosa was reflected back, bony ostium was performed with Smith-Kerrison punch forceps and the size was approximately 0.75-1 cm. Lacrimal Probing was done and by tenting the lacrimal sac it was opened anteriorly from the intranasal aspect. Medial wall of the lacrimal sac was excised anteriorly, and haemostasis was secured. (In conventional technique, posterior trimmed edge of the sac was approximated with the nasal mucosal flap).

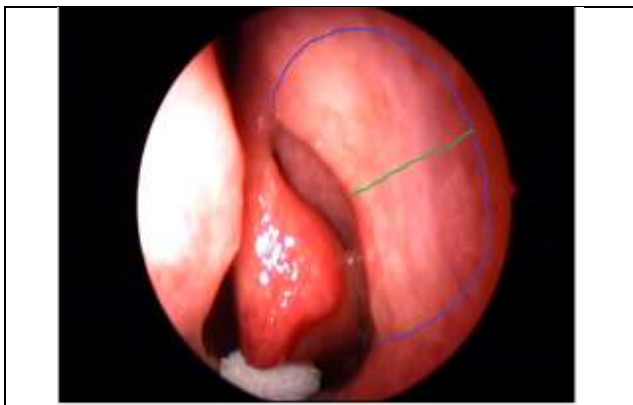
In this Modified mucosal flap technique, splitting of the nasal mucosal flaps into two halves which could cover the trimmed bony edge was done. The preservation of the nasal mucosa and fashioning of a nasal flap covering the bared bone, can reduce the formation of granulation tissue and lessen the risk for subsequent scar formation which causes closure of the ostium. The surgical site was packed with small piece of gel foam to hold the flaps in position. Nasal pack was applied which was removed after 6 hrs.

Patients were advised not to sneeze or blow the nose and were treated with systemic antibiotics, topical steroid antibiotic eye drops and topical nasal decongestant. Postoperatively syringing was done on 1<sup>st</sup> day, after 1 week, 1 month, 3 months and at the end of 6 months. Patients were followed up for a period of 6 months. The success rate was assessed by complete resolution of epiphora with patent lacrimal system evaluated by lacrimal syringing and nasal endoscopy.

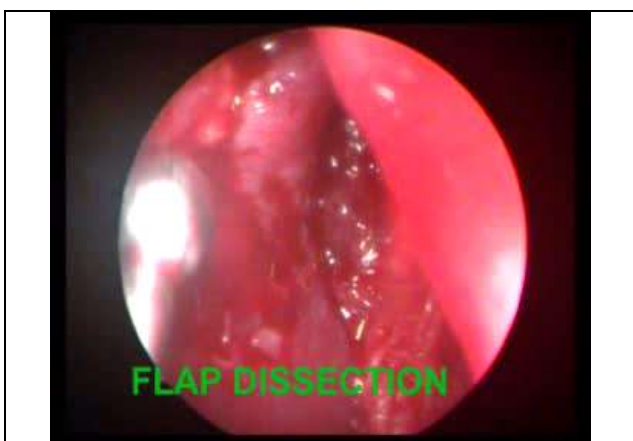### RESULTS



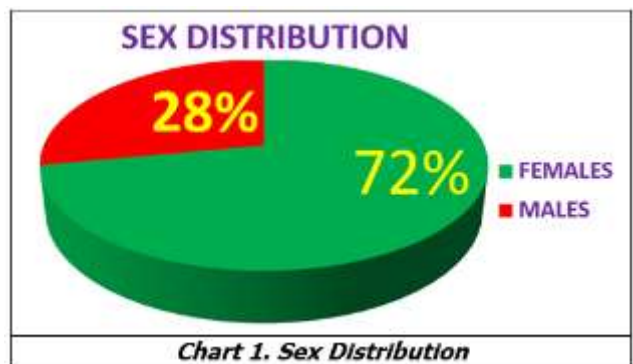
**Image 1. Infiltrative Anaesthesia**



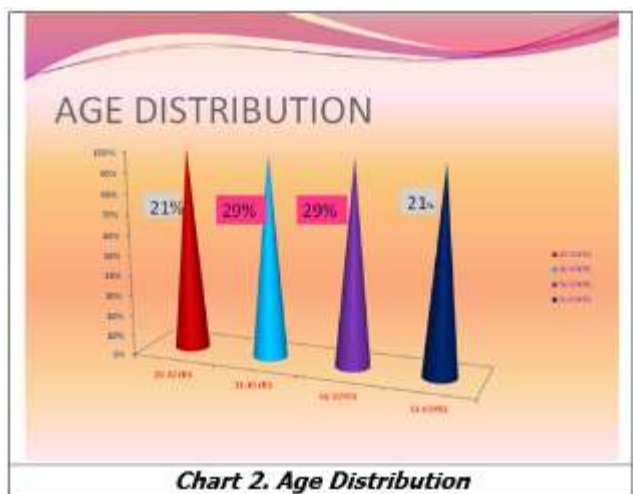**Image 2. Incision on Nasal Mucosa**



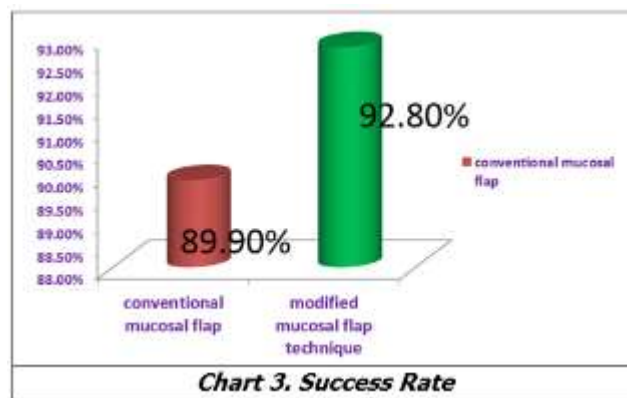
**Image 3. Flap Dissection**



**Chart 1. Sex Distribution**



**Chart 2. Age Distribution**



**Chart 3. Success Rate**

**DISCUSSION**

Dacryocystorhinostomy is the treatment of choice for chronic dacryocystitis, which can be performed by either external skin approach or the endoscopic endonasal approach. Development of high definition cameras and instruments like debridor have increased the outcome of endoscopic endonasal surgery with less complications.

A growing clinical experience has confirmed the value of the endoscopic endonasal dacryocystorhinostomy technique in the management of saccal and postsaccal obstruction of lacrimal drainage apparatus. Better understanding of the nasal cavity anatomy, refined instrumentation, preservation of nasal mucosa, adequate bony ostium, less duration of surgical procedure and good postoperative care have improved the success rate comparable to that of external dacryocystorhinostomy.

Anatomical variation of sac is dependent on anatomy of lateral wall of nose<sup>2</sup> which can be visualized directly with endoscopic guidance in endoscopic endonasal dacryocystorhinostomy. This helps in achieving 100% success.

Furthermore, adequate removal of bone while creating a bony ostium during the procedure plays a key role for successful surgery. For better surgical outcome during osteotomy the upper margin of the bony ostium should correspond to the fundus of the sac and also the frontal process of the maxillary bone above the attachment of middle turbinate has to be removed. The site of opening of the common canaliculus should correspond to the center of created bony ostium. Adequate excision of the medial wall of the lacrimal sac corresponding to the bony ostium will prevent the spontaneous closure of the sac mucosa and also prevent sump syndrome.

Creation of bony ostium with Smith-Kerrison forceps is better than using burrs and LASER because of burns and burr debris related complications.

The modified mucosal flap technique allows coverage of the denuded bone without obstructing the rhinostomy and accelerates the healing of the area without the need of exhaustive postoperative care in the immediate days after surgery. This technique also prevents the formation of fibrous scar around the ostium.

Endoscopic endonasal dacryocystorhinostomy has the advantage of no facial scarring without disturbing the physiological lacrimal pump by preserving medial palpebral

ligament.<sup>3</sup> This procedure helps to reduce the morbidity with less risk for intraoperative bleeding.<sup>4</sup> Endoscopic endonasal dacryocystorhinostomy has been reported to be faster than the traditional external dacryocystorhinostomy, more acceptable and equivalently successful<sup>5</sup> and it can be performed in acute dacryocystitis also.<sup>6</sup> Patients with bilateral dacryocystitis can undergo endoscopic endonasal dacryocystorhinostomy in the same sitting. Associated nasal pathologies like deviated nasal septum, nasal polyp and inferior turbinate hypertrophy can also be managed along with this procedure.

In our study, 72% were females and 28% males. Females were most commonly affected, and this correlates well with studies of Heikki et al<sup>7</sup> where the male: female ratio is 1:3. Most common age group being 31-50 Years. Our data correlates well with studies of Ibrahim et al.<sup>8</sup> Success rate was assessed by complete resolution of epiphora and patent lacrimal system which was evaluated by lacrimal syringing and nasal endoscopy.

The success rate of 89% has been reported for the lacrimal sac flap technique than for conventional endoscopic endonasal dacryocystorhinostomy in which part of the medial wall of the lacrimal sac and nasal mucosa are excised<sup>9</sup> but our study showed the success rate of 92.86% where we used modified nasal mucosal flaps. Mann and Wormald<sup>10</sup> stated that the shrinkage of ostium is small but significant amount in the first 4 weeks after surgery and then stabilizes. We had failure rate of 7.14% due to synechiae formation. No other complications were detected in the immediate postoperative period (like hematoma, ecchymosis, or epistaxis).

Thus, a simple modification of fashioning a nasal mucosal flap can easily preserve most of mucosal flap to cover the exposed bone. This mucosal flap technique reduces the formation of bony outgrowth in the margins of the ostium. It also prevents the formation of granulation tissue which in turn reduces the risk of closure of ostium, and thus improves the success rate of endoscopic endonasal dacryocystorhinostomy.

## CONCLUSION

Distal stenosis from progressive healing with closure of the ostium is the common cause of failure in conventional

mucosal flap technique. The technique of creation of mucosal flap helps in healing by primary intention with less chance of ostium shrinkage. Modified mucosal flap technique by splitting the nasal mucosa into two halves to cover the trimmed bony edge has shown to improve the success rate.

## REFERENCES

- [1] Hartikainen J, Antila J, Varpula M, et al. Prospective randomized comparison of endonasal endoscopic dacryocystorhinostomy and external dacryocystorhinostomy. *Laryngoscope* 1998;108(12):1861-1866.
- [2] Bharangar S, Singh N, Lal V. Endoscopic Endonasal Dacryocystorhinostomy: best surgical management for DCR. *Indian J Otolaryngol Head Neck Surg* 2012;64(4):366-369.
- [3] Thimmappa TD, Amith P, Nagaraj M, et al. Endonasal DCR: our experience. *IAIM* 2015;2(2):100-107.
- [4] Eloy P, Bertrand B, Martinez M, et al. Endonasal dacryocystorhinostomy: indications, technique and results. *Rhinology* 1995;33(4):229-233.
- [5] Dolman PJ. Comparison of external dacryocystorhinostomy with non-laser endonasal dacryocystorhinostomy. *Ophthalmology* 2003;110(1):78-84.
- [6] Whittet HB, Shun-Shin GA, Awdry P. Functional endoscopic transnasal dacryocystorhinostomy. *Eye (Lond)* 1993;7(Pt 4):545-549.
- [7] Heikki S, Reider G, Jouko H. Endonasal CO<sub>2</sub>-Nd: YAG laser dacryocystorhinostomy. *Acta Ophthalmologica* 1994;72(6):703-706.
- [8] Ibrahim HA, Noble JL, Batterbury M, et al. Endoscopic guided trephination dacryocystorhinostomy (Hesham DCR): technique and pilot trial. *Ophthalmology* 2001;108(12):2337-2346.
- [9] Yuen KS, Lam LY, Tse MW, et al. Modified endoscopic dacryocystorhinostomy with posterior lacrimal sac flap for nasolacrimal duct obstruction. *Hong Kong Med J* 2004;10(6):394-400.
- [10] Mann BS, Wormald PJ. Endoscopic assessment of the dacryocystorhinostomy ostium after endoscopic surgery. *Laryngoscope* 2006;116(6):1172-1174.