Loeffler's Syndrome - A Case Report

Dev Prakash Singh Rathour[1], Shubham Singh[2], Naveen Tandon[3], Pragat Gupta[4]

[1]Associate Professor, Department of Radiology, Era's Lucknow Medical College, Lucknow, Uttar Pradesh.
[2]Physician, Lucknow, Uttar Pradesh. [3]Physician, Lucknow, Uttar Pradesh.
[4]Consultant Pathologist, Lucknow, Uttar Pradesh.

PRESENTATION OF CASE

On 2nd August, a 10 yrs. old female patient, weighing 23 Kgs. presented with sudden onset of hyperpyrexia along with severe right sided chest pain and non-productive cough for past 3 days. No Family history of Tuberculosis and Allergy noted. No past history of passage of worms in stool or allergy noted. On examination, occasional crepitations were noted over right upper chest posteriorly; other parameters were normal. Chest skiagram depicted soft opacity in right middle zone. Blood examination show (column I) polymorphonuclear lymphocytosis, Hb 12.2 gm%, white blood cell count 16,300 cells/cumm, ESR 12 mm in first hour, Mantoux test turned out to be negative; platelets were adequate; stool was negative for ova and cyst. Patient was initially managed as a case of bacterial pneumonitis with Cefixime 100 mg BD and Acetaminophen.

On 9th Aug re-evaluation of patient revealed minimal response to the earlier therapy, the radiograph depicted cavitary lesion with air fluid level in right middle zone. Pathological investigation revealed rise in eosinophil count (col II). Patient was put on Augmentin & Albendazole 400 mg (single dose). On 16th Aug, 7 days therapy with Augmentin patient became afebrile and right sided chest pain minimized, CT Chest revealed a well-defined thick walled cavity in posterior segment of right upper lobe measuring 5.4 x 4.9 cms approx. Pathological reports dated 18 Aug (col IV) showed marked rise in eosinophil counts along with cysts of *Ascaris lumbricoides* in the stool.

On 19th Aug., patient was put on corticosteroid (Deflazacort) 0.25 mg per Kg body weight on alternate days. On re-evaluation on 21st Aug., patient showed dramatic response to the therapy clinically as well as radiologically with almost complete clearance of the opacity depicted on earlier radiographs. Patient also gave history of passage of solitary worm in stools on 20th August. Haematology report on 24th Aug. showed decline in leucocytosis with raised eosinophil count (col V). Patient was put on Diethylcarbamazine (Hetrazan) for 2 weeks. On re-evaluation on Sep 5th eosinophil count came back to normal with no clinical complaints.

DIFFERENTIAL DIAGNOSIS

Respiratory Tract Infection (Bacterial Pneumonitis)
Pulmonary Tuberculosis.
Loeffler's Syndrome.

Corresponding Author:
Dr. D. P. S. Rathour,
 # C-24, H-Park,
Mahanagar Extension,
Lucknow-226006, Uttar Pradesh.
E-mail: drdpsrathour@gmail.com

DOI: 10.18410/jebmh/2020/209

Financial or Other Competing Interests: None.

How to Cite This Article:
Rathour DPS, Singh S, Tandon N, et al. Loeffler's syndrome - a case report. J. Evid. Based Med. Healthc. 2020; 7(19), 960-962. DOI: 10.18410/jebmh/2020/209

Submission 04-03-2020,
Peer Review 06-04-2020,
Acceptance 24-04-2020,
Published 11-05-2020.

Columns	I	II	III	IV	V	VI
Date	Aug. 2nd	Aug. 9th	Aug. 16th	Aug. 18th	Aug. 24th	Sept. 5th
T.L.C.	16300	16300	13800	13900	10800	8900
D.L.C.						
Polymorphs	85	64	68	34	22	65
Leukocytes	14	28	14	32	42	28
Eosinophils	01	08	18	32	36	04
Monocytes	00	00	00	02	00	03
Consecutive Samples of Sputum (for AFB)	Negative	Negative	Negative			
Stool R/E				Cyst of Ascaris +ve		

Table 1

Figure 1. Skiagram Dated 2nd August Showing Soft Opacities in Middle Zone of Right Lung

Figure 2. Skiagram Dated 9th August Showing Large Thick Walled Cavitary Lesion with Air Fluid Level in Middle Zone of Right Lung

Figure 3. Skiagram Dated 21st August Showing Much Smaller Cavitary Lesion

Figure 4. Skiagram Dated 30th August Showing Almost Complete Disappearance of the Lesion

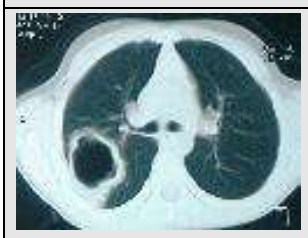

Figure 5. Computed Tomogram Showing Thick Walled Cavitary Lesion in Posterior Segment of Upper Lobe of Right Lung

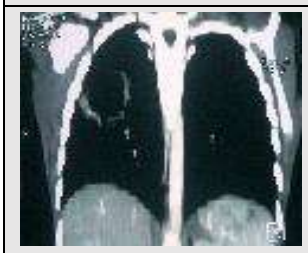

Figure 6. Coronal Computed Reconstruction Showing Thick Walled Cavitary Lesion

CLINICAL DIAGNOSIS

Respiratory Tract Infection (Bacterial Pneumonitis).

DISCUSSION OF MANAGEMENT

Initially based on clinical symptoms and radiography patient was managed as a case of bacterial pneumonitis with antibiotics, and antipyretics. Revaluation after a week as there was rise in eosinophil count and cavitary lesion on radiograph with persisting clinical symptoms, Antihelminthic single dose with antibiotic for a week was advised. As there was increase in size of pneumonitic chest opacity with cavitation and persisting clinical symptoms corticosteroid was started. Dramatic improvement was noted clinically & radiologically.

FINAL DIAGNOSIS

Loeffler's Syndrome.

DISCUSSION

Loeffler's Syndrome is synonymous with transitory Pulmonary Infiltrations, eosinophilia and benign course & few symptoms, first reported by Loeffler in 1932.[1,2] Loeffler's Syndrome is a part of extrinsic eosinophilic syndrome, pathophysiology of which presumably reflects a hypersensitivity response to an ingested or inhaled antigen from food, medication or an infection agent like Ascaris lumbricoides, Strongyloides Toxocara, Ankylostoma and Paragonimiasis.[2,3,4,5] It is self-limited (usually less than one month duration) and symptoms are mild.[6] Later on Disease with acute and severe type symptoms described by Lohr & Leon Kindberg.[7]

Generally the symptomatology in Loeffler's Syndrome is mild to moderate but in present case the symptoms were aggravated due to super added bacterial infection which resulted in marked polymorphonuclear lymphocytosis which also masked the findings of Loeffler's Syndrome initially and findings of peripheral Eosinophil count started rising once the bacterial infection started subsiding. The pain was uncharacteristically very severe in nature since the cavitary lesion was almost touching the pleura; which in turn was, causing pleurisy.

On review of literature, CT findings reported in eosinophilic lung disease, are of ground glass attenuation pulmonary nodule i.e., focal round area of high attenuation less than 3 cm in diameter, well defined or ill-defined with air space consolidation and bronchial wall thicknening.[6,8,9] In the present case, pulmonary lesion was bigger (measuring 5.4 x 4.9 cm) with cavitary changes. It is mentioned in the literature that heavier the infestation, more profuse are the pulmonary lesions.[5,9]

REFERENCES

[1] Grainger RG, Allison DJ, Dixon AK. Grainger & Allison's diagnostic radiology: a textbook of medical imaging. 4th edn. Churchill Livingstone 2001: p. 600, 895.

[2] Mason RJ, Murray J, Broaddus VC, et al. Textbook of Respiratory Medicine. 3rd edn. Philadelphia: WB Saunders 2005:1679-1695.

[3] Barrett-Connor E. Parasitic pulmonary disease. Am Rev Res Dis 1982;126(3):558-563.

[4] Weller PF. The immunobiology of eosinophils. N Engl J Med 1991;324(16):1110-1118.

[5] Peros-Golubicic T, Smojver-Jezek S. Hypereosinophilic syndrome: diagnosis and treatment. Curr Opin Pulm Med 2007;13(5):422-427.

[6] Kim Y, Lee KS, Choi DC, et al. The spectrum of eosinophilic lung disease: radiologic findings. J Comput Assist Tomogr 1997;21(6):920-930.

[7] Kartagener M. Chronic Pulmonay infiltration with eosiniphils. Schweiz Med Wchnschr 1942;720:862.

[8] Cheon JE, Lee KS, Jung GS, et al. Acute eosinophilic pneumonia: radiographic and CT findings in 6 patients. Am J Roentgenol 1996;167(5):1195-1199.

[9] Silva CI, Churg A, Muller NL, et al. Hypersensitivity pneumonitis spectrum of high resolution CT and pathologic findings. Am J Roentgenol 2007;188(2):334-344.