

## LOCAL EFFECTS OF STAINLESS STEEL PLATES ON POST FRACTURE BONE REMODELLING AND BONE MASS

Santhosh Kumar M. N.<sup>1</sup>, Philip Jacob<sup>2</sup>, M. A. Thomas<sup>3</sup>

<sup>1</sup>Associate Professor, Department of Orthopaedics, Government Medical College, Kottayam, Kerala.

<sup>2</sup>DNB Trainee, Department of Orthopaedics, Government Medical College, Kottayam, Kerala.

<sup>3</sup>Professor and HOD, Department of Orthopaedics, Government Medical College, Kottayam, Kerala.

---

### ABSTRACT

---

#### BACKGROUND

Fixation of fractures with plate and screw became an inevitable component of treatment of fractures.<sup>1</sup> The stainless steel plate and screws used in fracture fixation has thus evolved to a great extent and stood the test of time.<sup>2,3</sup> The alloy components of stainless steel includes iron, chromium and nickel.<sup>4</sup> However, the reaction to the apparently inert material produced local tissue response leading to early removal in some cases and elective and delayed removal in others where symptoms were comparatively tolerable.<sup>2</sup> The actual histological changes that occurred in the bone and adjacent soft tissues is analysed with a histopathological background of the tissue collected during implant removal.<sup>3</sup>

#### MATERIALS AND METHODS

Fifty of the patients who were subjected to stainless steel plate and screw removal at Government Medical College, Kottayam, Kerala were included in the study. A small portion of the underlying bone and adjacent soft tissue were collected and histologically assessed. Findings were noted.

#### RESULTS

Histopathological examination of the collected bone and soft tissue showed various types of tissue reaction occurring in the bone underneath the stainless-steel plate and soft tissue adjustment of the stainless-steel plate and screw, leading to defect in bone remodelling and bone mass.<sup>3</sup>

#### CONCLUSION

The stainless-steel plate although supposed to be inert and biocompatible stimulate tissue response like bone necrosis, foreign body granuloma, acute and chronic inflammation etc.<sup>5</sup> This microscopic revelation of these findings gives a clearer picture unlike x-rays which fail to give finer details.

#### KEYWORDS

Stainless Steel Plate, Histology, Histopathology, Bone Remodelling, Bone Mass, Osteonecrosis, Foreign Body Granuloma.

**HOW TO CITE THIS ARTICLE:** Santhosh Kumar MN, Philip Jacob, Thomas MA. Local effects of stainless steel plates on post fracture bone remodelling and bone mass. J. Evid. Based Med. Healthc. 2018; 5(34), 2477-2481. DOI: 10.18410/jebmh/2018/511

---

#### BACKGROUND

Bone is a highly organized tissue in the human body which heals by new bone itself unlike other tissues which are replaced by fibrous tissue. It is a dynamic tissue which undergoes osteoblastic and osteoclastic activities continuously.

The fracture in a bone can heal as in a healing of a skin wound by primary intention if fully reduced approximated and held in position by firm plate fixation. But the manner of fixation of plate and the material used in the fixation plate can modify the events in fracture healing including the remodelling as well as the quality of bone

after bone union. Stainless steel plates used in fixation of fractures are low cost materials but are strong, ductile, stress-yielding adequately, most inert and hence bio compatible.<sup>1</sup> In spite of these virtues, corrosion, local reaction, fatigue failure, osteoporosis of underlying bone and occasionally re-fracture after removal of the plates are also occasional accompaniments. Though alternate superior materials like titanium are presently available they are five to ten-fold costlier and hence stainless-steel plate continues to be used widely even now for fracture fixation. Infection, gap nonunion, atrophic nonunion, osteoporosis, implant breakage peri implant fracture, re fracture on removal of the implant are all not unusual in bones fixed with stainless steel plates. Strength of union preventing re-fracture depends on the quality of union, the bone mass at previous fracture sites, and the fracture remodelling. Hence a study of effects of stainless steel plate fixation in post fracture bone remodelling and bone mass would show the histological and histopathological sequelae that occur in fractures treated by stainless steel plate fixation.

*Financial or Other, Competing Interest: None.*

*Submission 02-08-2018, Peer Review 08-08-2018,*

*Acceptance 17-08-2018, Published 20-08-2018.*

*Corresponding Author:*

*Dr. Santhosh Kumar M. N,*

*Sandeepani, Mudiyrkara, Gandhinagar P.O.,*

*Kottayam- 686008, Kerala.*

*E-mail: drmnskumar@yahoo.co.in*

*DOI: 10.18410/jebmh/2018/511*



### Aim of the study

This study helps to observe the changes in the bone tissue in the histological and histopathological perspective in fractures fixed with stainless steel plate. Most of the earlier studies mainly makes the radiological observation. Moreover, a study on human population in this aspect is also rare.

### MATERIALS AND METHODS

The study was conducted at Government Medical College, Kottayam, Kerala during the period from 2008-2011. The study population included 50 patients between 20 & 50 years of age of either sex. There were 30 males and 20 females who reported for removal of stainless steel plate after variable time period, following the fixation due to various reasons like pain at plate and screw site, unexplained discomfort in the implant site or the whole limb. Some reported for removal based on their information that plates and screws are to be removed after a sound union. Certain others were afraid of future complications like initiation of infection later at the plate site especially with the chance of development of diabetes mellitus as age advances and so on. Only patients who had stainless steel plate fixation were included in this study. They were grouped into two, first one included those who reported for stainless steel plate and screw removal before 60 weeks after the fixation. The second group consisted of patients who came after 60 weeks following surgical fixation. The patients included only those who did not undergo any repeat surgery like bone grafting, repeat debridement for infection etc. The patients who had fractures involving articular surface, those with plate fixed for undisplaced fracture, pregnant patients, those with any known primary skeletal pathology, malignancy all were excluded from this study. The recent x-ray of the involved limb showing the healed fracture and the implant was taken to have a radiological assessment of the fractured portion. Pre-operative dose of IV antibiotic was given half an hour prior to surgery; procedure was done under regional anaesthesia after standard surgical preparation. Tourniquet was used in the operated limb. Incision was along the previous scar and standard layer by layer dissection. The screws were removed initially followed by the plate. The soft tissue adjacent to the plate and 0.5 cm of bone under the surface of the plate were taken, collected in glass specimen carriers containing 10% formalin. Bone and soft tissue were sent in separate containers for histological/histopathological evaluation by routine H&E staining. The bone tissue was processed, decalcified and taken for staining and microscopic evaluation. The findings of microscopic histopathological evaluation were noted, and the obtained data was analysed.

### RESULTS

The study revealed various effects of steel plates on post fracture bone remodelling and bone mass at the fracture region. The histopathological findings included- (1) Chronic inflammation, (2) Foreign body granuloma, (3) Fibroblast

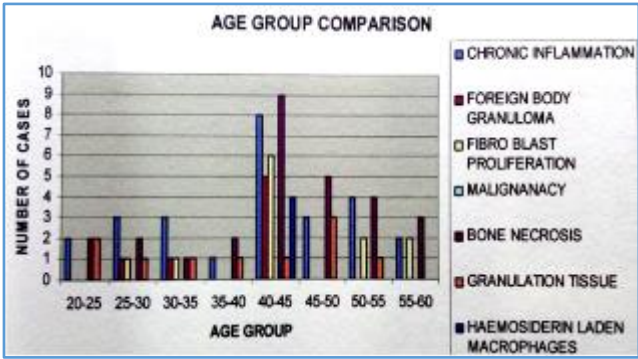
proliferation, (4) Bone necrosis, (5) Granulation tissue (6) Haemosiderin laden macrophages.<sup>3,6</sup>

The finding in any one fracture region fixed with stainless steel plate was a combination of the above findings, predominant response being a combination with bone necrosis.

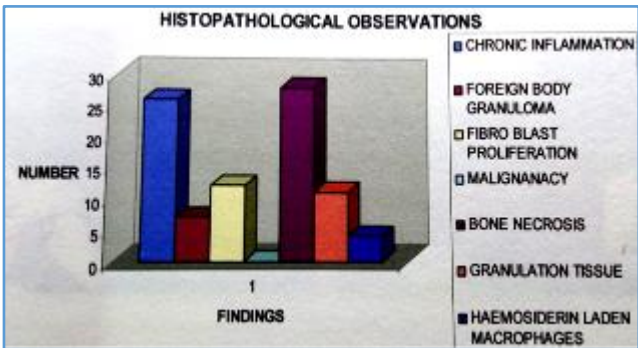
Where the histopathologic interpretation by Pathologist was granulation tissue with necrotic bone and inflammatory cells, the lesions were described as "section showing tissue composed of proliferated capillaries surrounded by dense proliferation of fibroblast with inflammatory infiltrate composed of eosinophils, plasma cell and lymphocytes and scattered entrapped bony spicules and necrotic bone". Where the interpretation of the tissue by the Pathologist was chronic inflammation with granulation tissue formation the description was "inflammatory exudates composing of lymphocytes and few plasma cells with areas of calcification and thick-walled blood vessels". Where the interpretation of histopathological examination was only chronic inflammatory lesion, the finding described was "areas adjacent to the bony spicules showed proliferation of fibroblast, small thin walled congested capillaries and scattered lymphocytes, plasma cells, neutrophils and histiocytes.<sup>7</sup> The peri implant osteoporosis section showed haemosiderin laden macrophages along with fibroblastic proliferation and hyalinized collagen. Other observations of the study were:

1. When the duration of the plate in situ increased more fibrous tissue proliferation occurred, with a concurrent incidence of foreign body granuloma.
2. Compression mode of plate fixation resulted in bone necrosis.

Sl. No.	Observation	Number	%
1.	Chronic inflammation	26	52
2.	Foreign body granuloma	07	14
3.	Fibroblast proliferation	12	24
4.	Bone necrosis	28	56
5.	Granulation tissue	11	22
6.	Hemosiderin laden macrophages	04	08
<b>Combined Lesions</b>			
1.	Chronic inflammation, bone necrosis and granulation tissue	06	12
2.	Chronic inflammation and granulation	05	10
3.	Inflammation, bone necrosis and fibrous proliferation	07	14
4.	Inflammation and foreign body granuloma	03	06
5.	Necrosis alone	08	16
6.	Inflammation, foreign body granuloma, bone necrosis and fibrous proliferation	01	02
7.	Inflammation bone necrosis, fibrous proliferation and haemosiderin laden macrophages	01	02
<b>Table 1. Histopathological Observations</b>			

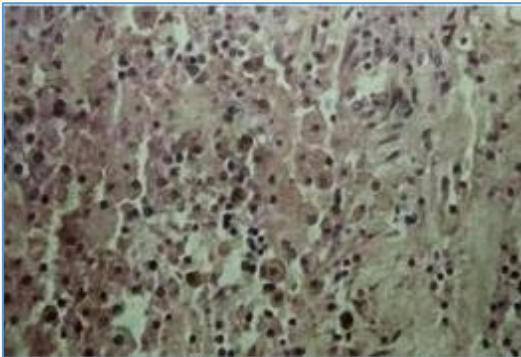


**Graph 1. Showing Age-group Comparison of Various Histological Observations**

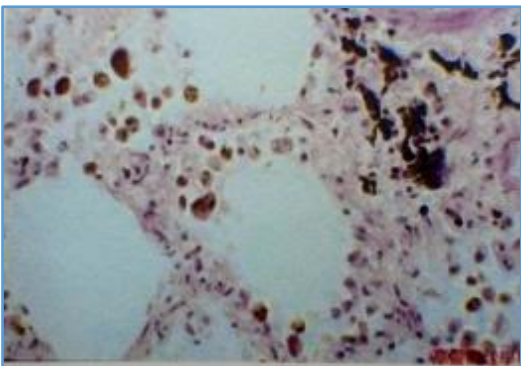


**Graph 2. Showing Frequency Distribution of Various Histological Observations**

**Microscopic Appearance of Tissue Sent for Histological Evaluation-**

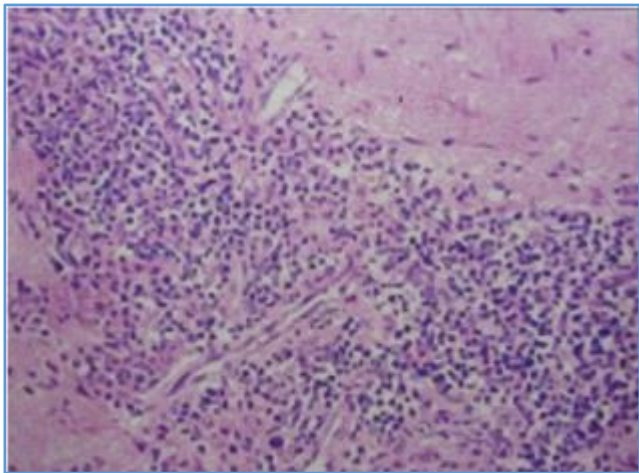


**Figure 1. Haemosiderin Laden Macrophages (Low Power view)**

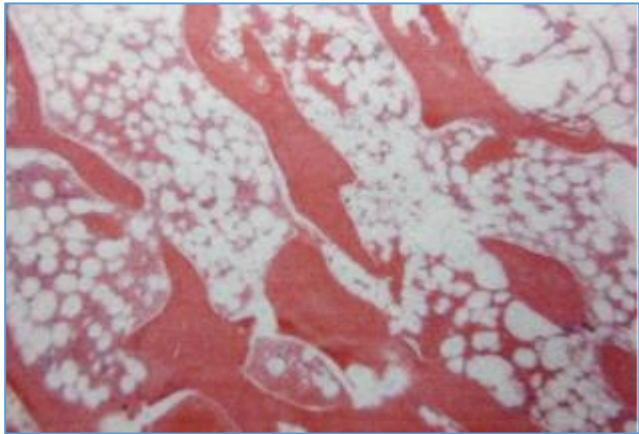


**Figure 2. Haemosiderin Laden Macrophages (High Power View)**

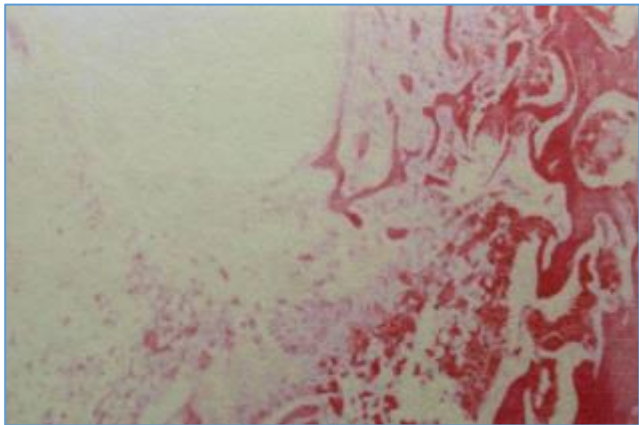
**Microscopic Appearance of Tissue Sent for Histological Evaluation-**



**Figure 3. Chronic Inflammation**



**Figure 4. Bone Necrosis**



**Figure 5. Foreign Body Granuloma of Bone**

**DISCUSSION**

Studies analysing the effects of fixation with stainless steel and other plates on post fracture bone remodelling and bone mass have been carried out earlier. Most of these studies were on animal subjects.<sup>1</sup> Studies conducted on human beings are comparatively few.<sup>5</sup> Radiological evaluation has its own limitations based on: 1) Quality and type of the x-ray. 2) The exposure factor. 3) Magnification & 4) Inter observer variation and so on.

The present study comprising of 50 patients were in the 20 - 60 age group where most of the fractures occur being the active age group which is exposed to more chance of fractures. Metal degradation in the body can be evoked by dissolution and corrosion apart from mechanical stress and forces. Rigid fixation with plates leads to cortical osteoporosis of the bone region fixed with plates and screws and also delays the bridging of the callus. Rigid fixation also provokes refracture on removal of the plate.

In the present study of three-year period consisting of patients in the age group of 20-60 years, the bone tissue for HPE was taken from underneath the plates and soft tissue from most adjacent area. These tissues were histologically evaluated and analysed. Osteonecrosis was the prominent finding. Fixation of bone by stainless steel plate results in an acute inflammation initially and progresses to chronic inflammation eventually resulting in fibrous tissue proliferation and bone necrosis. Haemosiderin laden macrophages were also a common finding along with foreign body granuloma. Refracture rate on plate removal to the rate of 8% was found in forearm plate fixation. The refracture occurred at times even intra-operatively which is matter of a serious concern. When considering the relevance of the histological findings at the site of plate fixation, osteonecrosis detected in the HPE was a feature associated with rigid fixation, where the bone mass was also found to be less intra-operatively, apart from the decreased callus found in the x-rays. Where the plate appeared to be fixed in non-compression mode, and thus less rigidly fixed, osteonecrosis under the plate was also less.

Early removal, (meaning less than 60 weeks in this study) leads to more marked remodelling than late removal (meaning later than 60 weeks in this study).

Structural remodelling of Haversian envelop is influenced by the length of time the plate remains in situ. The exact duration of return to normal bone architecture and thus normal bone strength is not known. It is probably longer than previously thought. Stress testing which might evoke refracture to assess the strength of union and bone mass was not undertaken as it would lead to results which are not acceptable for a study conducted observing ethical issues.

### Summary

This study was conducted to assess the effects of stainless steel plate fixation on post fracture bone remodelling and bone mass. Plain x-ray partly displays the effects of plate fixation in bone fracture. The histopathological observation is a better picture of the actual histological responses occurring at the fracture region.<sup>3</sup> The study gives a moderate picture of the tissue responses to the stainless-steel plate fixation of the fracture. It showed that as the duration of the plates in situ increased, more fibrous tissue proliferation occurred and also the concurrent increase in incidence of foreign body granuloma. Rigid fixation in compression mode increased bone necrosis under the plate. Less rigid fixation would appear to be better for bone

quality and bone mass with a reduced bone necrosis. The major finding of the study as listed in order of incidence include bone necrosis and chronic inflammation followed by fibrous tissue and fibroblast proliferation, granulation tissue, foreign body granuloma and haemosiderin laden macrophages.<sup>5</sup> These effects were seen mostly as combinations.

### CONCLUSION

The study of effects of stainless steel plates on post fracture bone remodelling and bone mass yielded the following conclusion-

- Stainless steel plate fixation could cause damage to the fractured bone in the long term if it is retained for prolonged periods.
- It reveals the actual microscopic tissue changes occurring in the vicinity and underneath the plate better than what is detected radiographically.
- Forearm stainless steel plates fixations lead to more chances of refracture than other long bones.
- Implant removal facilitates more effective control of infection at the fracture site.
- When fracture is united radiologically, removal of the plates is to be recommended.
- In symptomatic patients, symptoms were relieved by removal of the stainless-steel plates.<sup>8</sup>
- Late removal of the plates decreases the osteogenic response and inhibits subsequent bone remodelling.
- Less rigid plate fixations are preferred as it reduces bone necrosis and thus improves bone mass and bone remodelling.

### Comments

The finding in this study gives the presumption that replacement of stainless steel plates with more inert materials like titanium would most probably decrease the local reactions like inflammatory response, granulation tissue, acute and chronic inflammatory tissues, foreign body granuloma, haemosiderin laden macrophages etc. In the prevailing circumstances, the surgeon has limitations in assuring the quality the stainless implants available in the market. At the same time, the extensive and exclusive use of titanium like materials is limited by the cost factor.

### Acknowledgement

I place on record the guidance and support of Professor and HOD Dr MA Thomas in the conduct of the study. I am thankful to DR Philip Jacob DNB resident who was the backbone of this study. I express my sincere thanks to the faculty in the Department of Pathology of our institution without whose graceful support this study would not have been possible. I am thankful to all the colleagues in the department of orthopaedics who have in one way or the other extended their help in this study.

**REFERENCES**

- [1] Sahoo NK, Anand SC, Bhardwaj JR, et al. Bone response to stainless steel and titanium bone plates. An experimental study on animals. *Med J Armed Forces India* 1994;50(1):10-14.
- [2] Figueira N, Silva TM, Carmezim MJ, et al. Corrosion behavior of Ni-Ti alloy. *Electrochimica Acta* 2009;54(3):921-926.
- [3] Voggenreiter G, Leiting S, Brauer H, et al. Immuno-inflammatory tissue reaction to stainless steel and titanium plates used for internal fixation of long bones. *Biomaterials* 2003;24(2):247-254.
- [4] Maruyama N. Mechanical testing of metallic biomaterials. *Metals for Biomedical Devices* 2010:157-177.
- [5] Wooley PH, Nasser S, Fitzgerald RH. The immune response to implant materials in humans. *Clin Orthop Relat Res* 1996;326:63-70.
- [6] Cramers M, Lucht U. Metal sensitivity in patients treated for tibial fractures with plates of stainless steel. *Acta Orthop Scand* 1977;48(3):245-249.
- [7] Franz S, Rammelt S, Scharnweber D, et al. Immune responses to implants - a review of the implications for the design of immunomodulatory biomaterials. *Biomaterials* 2011;32(28):6692-6709.
- [8] French HG, Cook SD, Haddad RJ. Correlation of tissue reaction to corrosion in osteosynthetic devices. *Journal of Biomedical Materials Research* 1984;18(7):817-828.