

LIGHT-EMITTING DIODE BULBS IN PAEDIATRIC AIRWAY- A CASE SERIES

Abhik Sikdar¹, Sanjeev Mishra², Sameer Nivsarkar³, Richa Agrawal⁴, Shrikant Phatak⁵

¹Consultant, Department of ENT and Head and Neck Surgery, Choithram Hospital and Research Centre, Indore, Madhya Pradesh.

²Senior Resident, Department of ENT and Head and Neck Surgery, Choithram Hospital and Research Centre, Indore, Madhya Pradesh.

³Consultant, Department of ENT and Head and Neck Surgery, Choithram Hospital and Research Centre, Indore, Madhya Pradesh.

⁴Clinical Assistant, Department of ENT and Head and Neck Surgery, Choithram Hospital and Research Centre, Indore, Madhya Pradesh.

⁵Consultant and HOD, Department of ENT and Head and Neck Surgery, Choithram Hospital and Research Centre, Indore, Madhya Pradesh.

HOW TO CITE THIS ARTICLE: Sikdar A, Mishra S, Nivsarkar S, et al. Light-emitting diode bulbs in paediatric airway- A case series. J. Evid. Based Med. Healthc. 2017; 4(91), 5518-5520. DOI:10.18410/jebmh/2017/1103

PRESENTATION OF CASE

On extensive internet search of published English literature, we found only 3 cases of Light-Emitting Diode (LED) bulb in airway.^{1,2,3} We present 2 cases of LED bulb aspiration presenting to us in the last 6 months.

Case1

The first case was an 8-year-old boy who presented to us with 1-day-old history of accidental 'swallowing' of an LED bulb he got for his science project. Child did not have any signs or symptoms of respiratory distress. Auscultation revealed adequate air entry bilaterally with associated conducted sounds. Chest radiograph showed a wire-like shadow in the right main bronchus suggestive of a diode bulb with its electrodes trailing proximally (Figure 1). After taking consent, rigid bronchoscopy (sheath 6.7 millimetres outer diameter, 30 centimetres length) was done under general anaesthesia. The bulb in right main bronchus was removed with double action serrated bronchoscopy forceps under vision of STORZ paediatric bronchoscopic telescope (2.9 millimetres diameter and 50 centimetres length) with STORZ camera system (Figure 2). Check bronchoscopy was done. Patient withstood procedure well and was shifted to recovery for 2-hour observation. Postoperatively, nebulisation (salbutamol, budesonide and adrenaline), intravenous steroids and antibiotics were administered.

Case 2

Second patient was a 5-year-old girl who presented with cough and cold for 4 days and fever for 2 days. Parents volunteered history of aspiration of LED bulb 4 days back. Child did not have any signs of respiratory distress and auscultation revealed conducted sounds with bilateral equal

air entry. Chest radiograph delineated twisted wire-like shadow in the right main bronchus. Rigid bronchoscopy (sheath 5.7 millimetres outer diameter, 30 centimetres length) was done under general anaesthesia and the foreign body removed uneventfully with double-action serrated optical forceps (Figure 3).

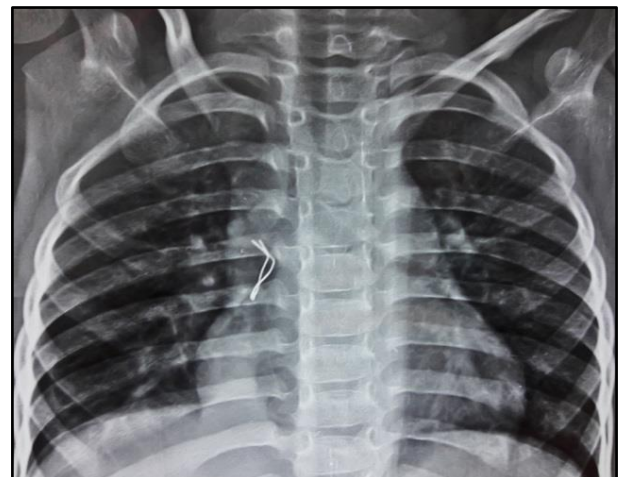


Figure 1. Showing X-Ray Chest Showing Twisted Wire like Shadow



Figure 2. The Extracted LED Bulb

Financial or Other, Competing Interest: None.

Submission 10-11-2017, Peer Review 15-11-2017,

Acceptance 25-11-2017, Published 27-11-2017.

Corresponding Author:

Dr. Abhik Sikdar,

Flat No. 902, Block A3, Avasa Housing, Opposite

Phalbag, Main A. B. Road, Bijalpur, Indore- 452012.

E-mail: abhik_sikdar@yahoo.co.in

DOI: 10.18410/jebmh/2017/1103



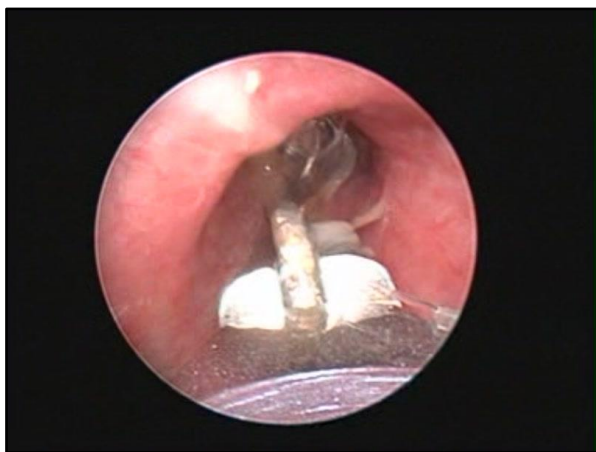

Figure 3. Bronchoscopic Removal of Foreign Body

DIFFERENTIAL DIAGNOSIS

Paediatric foreign body aspiration, most of the times present as stridor and respiratory distress along with history of fever and respiratory tract infections. Thus, a differential diagnosis of infective aetiology should be considered. Both of our cases were clinically asymptomatic. Strong history as given by parents in both cases was suggestive of foreign body in airway.

CLINICAL DIAGNOSIS

On clinical history and examination, the diagnosis of foreign body main bronchus was made in both cases, which were supported by the radiological evidence of wire-like shadow in right main bronchus.

PATHOLOGICAL DISCUSSION

Foreign body in airway presents as acute respiratory distress or in longstanding and undiagnosed cases, it may lead to chronic lung parenchymal complications like pneumonia, emphysema, lung collapse or bronchiectasis. Tracheobronchial FBA can be fatal if the object completely obstructs the airway leading to asphyxia and rapid death. The severity of symptoms depends upon the size, site and nature of foreign body aspirated. However, in some instances as in both of our cases, patients maybe asymptomatic. Children less than 4 years are more susceptible to FBA.^{4,5} They lack molar teeth for proper chewing and explore their surroundings by mouthing. FBA in infancy is rare as subject is usually under constant parental supervision. However, sometimes elder sibling may introduce a foreign body into the infants' mouth. Our two children were of 8 years and 5 years, respectively. The offending foreign body can be lodged anywhere along the tracheobronchial tree.⁶In our cases, both were lodged in right main bronchus. Commonly, nuts, seeds and sometimes toy parts are aspirated. In both of our cases, it is a rare foreign body- LED bulb aspiration.

DISCUSSION OF MANAGEMENT

Tracheobronchial Foreign Body Aspiration (FBA) is a major cause of morbidity and mortality in children. While chest radiograph being easily available is helpful in diagnosis of radiopaque FBA, definitive diagnosis can be done by high

resolution computerised tomography, which show size, site, number, duration and nature of foreign body. Because of the high risk associated with FBA, rigid bronchoscopy preferably with optical instruments under video-telescopic guidance is the gold standard for management.

The magnified view on monitor makes it safer with better coordination between surgeon and anaesthetist. It also provides a faster learning curve for the surgeons and residents. Both bulbs were extracted using the rigid KARLSTORZ optical bronchoscope system with the ventilating sideport, which allows intermittent jet ventilation. This life-saving procedure can have complications like incomplete removal, laryngeal spasm, pulmonary oedema and bradycardia. Thus, tracheostomy, mechanical ventilation and a relook bronchoscopy was included in the informed consent. None of the patients required post-procedure endotracheal intubation.

For the otolaryngologist, there is nothing more life-saving, yet iatrogenically life-threatening as that of bronchoscopic foreign body removal. Complication rates depend on anaesthesia type, patient condition, availability of appropriate instruments and on the operator's skill and experience.^{7,8}

FINAL DIAGNOSIS

With clinical evaluation, radiological evidences and after therapeutic rigid bronchoscopy, the final diagnosis of foreign body LED bulb in right main bronchus was made in both the cases and managed accordingly. Both the children were discharged uneventfully next day. The follow up period was unremarkable.

With technological innovation, LED bulbs are routinely available, thus easily accessed by children. Consequently, incidences of such bulb aspiration are also increasing. As an otolaryngologist, one should keep in mind, chances of a LED bulb as a bronchial foreign body. There must be appropriate bronchoscopic forceps, preferentially optical to manage such cases safely.

Ethics- Informed consent were taken from parents of both the children for medical research publication.

Acknowledgment

Dr. Sunil Chandiwal, Director Medical Services, Choithram Hospital and Research Centre, Indore.

REFERENCES

- [1] Roslina H, Subha ST, Hisyam S, et al. LED bulb in trachea and bronchus of an 8 months old infant. *Rawal Med J* 2012;37(2):220-221.
- [2] Yetim TD, Bayarogullari H, Arica V, et al. Foreign body aspiration in children; analysis of 42 cases. *J PulmonResp Med* 2012;2:121.
- [3] Lau CT, Lan L, Wong K, et al. A light bulb moment: an unusual cause of foreign body aspiration in children, *BMJ Case Reports* 2015.DOI:10.1136/bcr-2015-211452

- [4] Yadav SP, Singh J, Aggarwal N, et al. Airway foreign bodies in children: experience of 132 cases. *Singapore Med J* 2007;48(9):850-853.
- [5] Reilly JS, Cook SP, Stool D, et al. Prevention and management of aerodigestive foreign body injuries in childhood. *Pediatr Clin North Am* 1996;43(6):1403-1411.
- [6] Mundra RK, Agrawal R, Sinha R. Unusual foreign body aspiration in infants below 6 months of age. *Indian J Otolaryngol Head Neck Surg* 2014;66(2):145-148.
- [7] Chen LH, Zhang X, Li SQ, et al. The risk factors for hypoxemia in children younger than 5 years old undergoing rigid bronchoscopy for foreign body removal. *Anesth Analg* 2009;109(4):1079-1084.
- [8] Hasdiraz L, Oguzkaya F, Bilgin M, et al. Complications of bronchoscopy for foreign body removal: experience with 1,035 cases. *Ann Saudi Med* 2006;26(4):283-287.