

CASE REPORT

LARGE CERVICO-MEDIASTINAL GOITRE: A RARE CASE REPORT

Jakkula Kishore¹, J. Anuradha², P. S. Srinivas³

HOW TO CITE THIS ARTICLE:

Jakkula Kishore, J. Anuradha, P. S. Srinivas. "Large Mediastinal Goitre: A Rare Case Report". Journal of Evidence based Medicine and Healthcare; Volume 2, Issue 13, March 30, 2015; Page: 2100-2103.

INTRODUCTION: Goitre is enlargement of thyroid gland due to various causes, most of them are benign.^[1] A retrosternal goitre is a multinodular goitre with lower border is extending down behind manubrium sterni into superior mediastinum.^[2] A true intra thoracic goitre is a goitre arising from ectopic thyroid tissue, which is rare and may present in any one of the mediastinum (superior, anterior and posterior in that order).^[3,4] More commonly, a mediastinal goitre is the resultant of extension of cervical goitre down into thorax, where there is enough space to enlarge unlike in the neck, presenting with atypical symptoms.^[3,4,5] We report one case of cervico-mediastinal large goitre in a young female and the surgical management with few references.

CASE REPORT: A 35 yrs old house wife came with recurrent neck swelling since past 8yrs. She had also weight loss, excessive sweating, palpitations and anxiety. Recently, since one year she was suffering with intractable dry cough and occasional attacks of bronchospasm. In past 14yrs ago she underwent some surgery for the neck swelling, probably for thyroid swelling. She was referred to chest physician and found to have intrathoracic goitre along with neck goitre. The respiratory symptoms probably attributed to the compression of trachea by large goitre.

She was investigated, her thyroid function tests were normal and so of other biochemical tests. CXR showed large mediastinal mass (Fig. 1). The CECT neck and thorax revealed large anterior mediastinal mass connecting to the neck mass probably? thymus tumor or a mediastinal goitre (Fig. 2). The FNAC done from neck and mediastinal swelling (ctguided) showed colloid / nodular goitre.

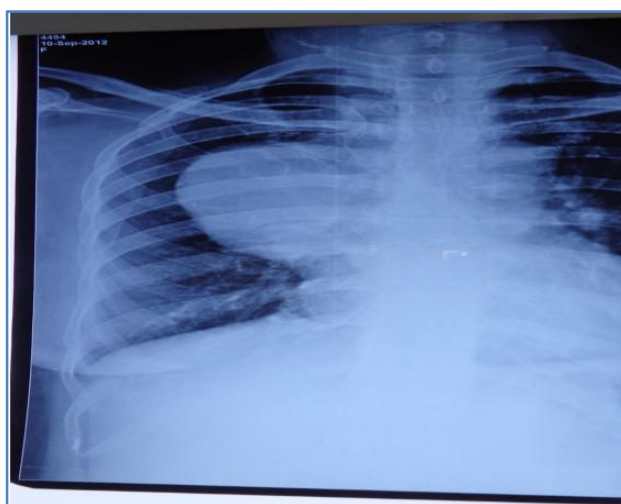


Fig. 1

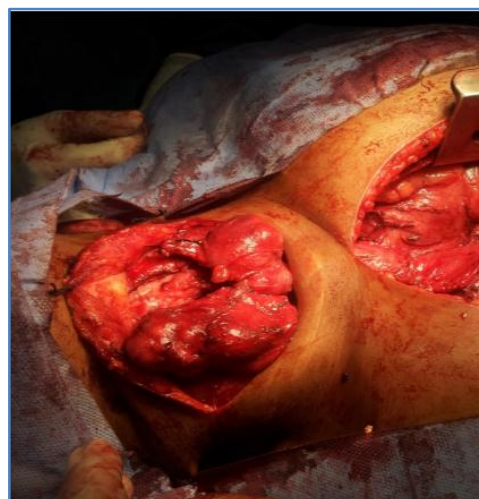


Fig. 2

CASE REPORT

She underwent total thyroidectomy via cervical incision and median sternotomy for removal of intra thoracic goitre intoto, under general anesthesia. The surgical steps are, first neck opened and all the pedicles identified, ligated and cut, whole of the goitre in the neck mobilised. Both the superior parathyroids are identified and preserved, in case the inferior parathyroids are damaged during retrosternal dissection. The recurrent laryngeal nerves both were identified and traced down to thoracic inlet.

Later, a median sternotomy given, the thoracic part of goitre which is almost 20x15x8cms size occupying the anterior mediastinum adherent to pericardium. The whole mediastinal goitre was mobilised, there were few dilated inferior thyroid veins entering into innominate vein in superior mediastinum, they were carefully ligated and cut. Few were oversewn with 4-0 proline. For mediastinal dissection a harmonic scalpel was used, to decrease bleeding.

The whole specimen carefully removed through thorax, after the cervical portion carefully negotiated down into thorax, incontinuity with rest. (Fig. 3)

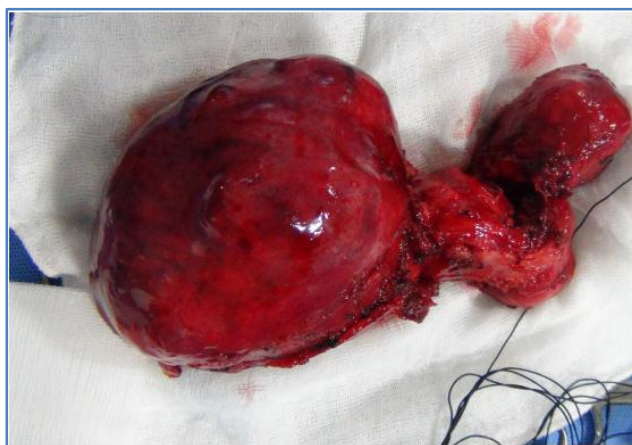


Fig. 3

The wound closed in layers after keeping drains. Postop period was uneventful except mild hypocalcemia, which was treated with oral calcium and she was discharged on 7th postop day.

The specimen was sent to HPE which came as nodular colloid goitre in both cervical and thoracic parts. There was no evidence of malignancy.

DISCUSSION: A mediastinal goitre is defined when 50% of thyroid gland is present substernally.^[3] About 5-10% of all mediastinal masses are intrathoracic goitres. They present in anterior, middle mediastinum commonly and rarely in posterior mediastinum.^[3,4] They are mostly asymptomatic unless they compress upon surrounding structures, as in case large benign goitre, producing dysphagia or dyspnea, asthma like respiratory symptoms.^[3] They occasionally present early with malignant goitres involving surrounding structures by infiltration and adherence.^[3]

The intra thoracic goitres are historically divided into primary and secondary types.^[3,4]

CASE REPORT

Primary intrathoracic goitres are rare arise from true ectopic (aberrant) thyroid glands and they are only 1% of all retrostrnal goitres, they have blood supply from mediastinal vessels, do not have connection to cervical thyroid.^[3]

The secondary intrathoracic one are the commonest type and they arise from lower border of cervical goitre, this down ward migration is due to traction forces during swallowing, gravity, negative intrathoracic pressure and the presence of anatomical barriers influencing preventing the direction of growth in the neck. Hence, they have connection with cervical thyroid and gets blood supply invariably from inferior thyroid artery.^[4,5,6]

The goitre progresses down along the trachea enter either anterior, middle or posterior mediastinum.^[4] The patients remain symptomless for years, the first symptom usually is dyspnea aggravated on lying down posture or flexion of neck, because of compression of trachea. Patient prefer to spend at night in a chair.^[3,5,6] Sometimes they come with episodes of asthma or dysphagia. Clinically along with neck swelling there can be dilated veins over chest.^[6]

A chest x- ray PA view or latera films reveal a mass, a CT scan or MRI would help in assessing the nature and extent of the mediastinal goitre. Tissue biopsy is required for definitive diagnosis.^[6,7]

Thyroidectomy through cervical approach as initial step is appropriate, mobilising the neck gland completely, devascularising the gland by ligating all the pedicles in the neck especially the inferioir thyroid artery, from which the retrosternal goitre derives its blood supply.^[7] Special care should be taken to avoid injury of the recurrent laryngeal nerves during the delivery of retrosternal goiter.^[5,6,7] A median sternotomy or lateral thoracotomy is required to deliver the intra thoracic goitre depending upon the site and extent.^[8]

Finally, the specimen of cervico- mediastinal goitre will be delivered either by transecting the connection between neck and thoracic components or pushing the cervical portion down into the thoracic cavity. Recently, surgeons prefer to do minimal invasive procedures like thorocoscopic procedures for dissection of intrathoracic goitres, to avoid thoracotomy.^[8]

REFERENCES:

1. Jameson J. L, WAP. Disorders of the thyroid gland. In: Fauci AS BE, Kasper DL, Hauser SL, Longo DL, Jameson JL, Loscalzo J, editors. Harrison's principles of internal medicine 17th ed. New York, NY: McGraw-Hill.
2. Bennedbaek FN, Hegedus L. Management of the solitary thyroid nodule: results of a North American survey. J Clin Endocrinol Metab 2000 Jul; 85(7): 2493-98.
3. Rios A, Rodriguez JM, Balsalobre MD, Tebar FJ, Parrilla P. The value of various definitions of intrathoracic goiter for predicting intra-operative and postoperative complications. Surgery 2010 Feb; 147(2): 233-8.
4. Thomas K, Varghese Jr. M, Christine L. Lau. The mediastinum. In: Courtney M. Townsend Jr., RDBM, Mark Evers B, Kenneth L. Mattox, editors. Townsend: Sabiston textbook of surgery 18th ed. Philadelphia, Pennsylvania: W.B. Saunders 2007.
5. Zambudio AR, Rodriguez J, Riquelme J, Soria T, Canteras M, Parrilla P. Prospective study of postoperative complications after total thyroidectomy for multinodular goiters by surgeons with experience in endocrine surgery. Ann Surg 2004 Jul; 240(1): 18-25.

CASE REPORT

6. Mohd. shamoon, rakesh bhargav, zubirahmed, etal. Intrathoracic goitre presenting as posterior mediastinal mass. JIACM2005; 6(4): 343-4.
7. Malcolm h wheeler, the surgical management of retrosternal goitre (intra thoracic) world journal of endocrine surgery 2005; 10.5005/ jp-journals-1002-1121.
8. Agarwal G, Aggarwal V. Is total thyroidectomy the surgical procedure of choice for benign multinodular goiter? An evidence-based review. World J Surg 2008 Jul; 32(7): 1313-24.

AUTHORS:

1. Jakkula Kishore
2. J. Anuradha
3. P. S. Srinivas

PARTICULARS OF CONTRIBUTORS:

1. Associate Professor, Department of Surgery, Rangaraya Medical College.
2. Assistant Professor, Department of Obstetrics and Gynaecology, Andhra Medical College.
3. Assistant Professor, Department of Surgery, Andhra Medical College.

NAME ADDRESS EMAIL ID OF THE CORRESPONDING AUTHOR:

Dr. Jakkula Kishore,
10-5-21, 20A, Navya,
Facor Layout, A. U. Post,
Visakhapatnam – 530003,
Andhra Pradesh.
E-mail: jakkula_kishore@yahoo.com

Date of Submission: 17/03/2015.
Date of Peer Review: 18/03/2015.
Date of Acceptance: 20/03/2015.
Date of Publishing: 30/03/2015.