

LAPROSCOPIC REPAIR OF UMBILICAL HERNIA BY EXTRACORPOREAL KNOTTING - AN INNOVATIVE SUCCESSFUL NON MESH TECHNIQUE: LOW RECURRENCE RATES ON LONG TERM FOLLOW UP

S. R. Dhamotharan¹, R. Vinoth Prabu², J. K. Karthick³

¹Professor, Department of General Surgery, Madurai Medical College, Madurai.

²Post Graduate, Department of General Surgery, Madurai Medical College, Madurai.

³Post Graduate, Department of General Surgery, Madurai Medical College, Madurai.

ABSTRACT: BACKGROUND: This study evaluates the feasibility of laparoscopic transfascial suture and extracorporeal knotting repair of umbilical hernias.

METHODS: From August 2005 to August 2015, 45 patients underwent laparoscopic umbilical suture repair. The repair was performed with the Carter-Thomason suture passer and cobbler's needle.

RESULTS: Of the 45, 36 patients with more than 1-year follow-up were included in the study. The mean diameter of the umbilical hernia defect was 1.30 cm (range, 0.5 to 2). At a mean follow-up of 34 months (range, 12 to 60), there were only 1 recurrence (2.77%) which happened in patients with hernia defects larger than 1.5 cm in diameter. Apart from 2 wound infections, no other complications occurred.

CONCLUSION: Laparoscopic suture repair of umbilical hernias with the suture passer method is effective and durable. The cobbler's needle proved a simple and cosmetically acceptable device with which to close the umbilical hernia defect extracorporeally. This technique can be done simultaneously during other laparoscopic procedures such as laparoscopic cholecystectomy, laparoscopic appendectomy where mesh placement is not feasible in view of contamination. We tried this new innovative method and proved successful on long term followup.

KEYWORDS: Umbilical hernia, Laparoscopic technique, Cobblers needle, Carter-Thomason suture passer.

HOW TO CITE THIS ARTICLE: S. R. Dhamotharan, R. Vinoth Prabu, J. K. Karthick. "Laparoscopic Repair of Umbilical Hernia by Extracorporeal Knotting - An Innovative Successful Non Mesh Technique: Low Recurrence Rates on Long Term Follow Up". Journal of Evidence based Medicine and Healthcare; Volume 2, Issue 48, November 16, 2015; Page: 8417-8420, DOI: 10.18410/jebmh/2015/1148

INTRODUCTION: Open umbilical hernioplasty by primary closure of the fascial defects, considered the standard repair by most surgeons, is plagued by a high recurrence rate, particularly after suture repair (11%).¹ Synthetic mesh has a more favorable recurrence rate (1%), but Laparoscopic transfascial suture repair of these defects, an approach that allows wider fascial closure, may offer an attractive alternative as simple, short procedure time, short learning curve for the operator and less expensive. This article reports our experience with laparoscopic umbilical hernia suture repair by extracorporeal knotting technique.

METHODS: Between August 2005 and August 2015, 45 patients underwent laparoscopic umbilical suture repair in association with another laparoscopic procedure. The procedures were performed by or under the direct supervision of a single attending surgeon. Of these, 36 patients had a follow-up period of more than 1 year and were selected as the study population. Thus, 9 patients were excluded due to a short follow-up. Data were collected retrospectively and included patient age, sex,

concomitant laparoscopic procedure, number of previous repairs, size of fascial defect, and postoperative complications. Patients were evaluated for hernia recurrence and complications by the attending surgeon in the immediate postoperative period and 1 to 2 weeks postoperatively. Long-term surveillance for recurrence was performed by a surgeon every 3 months by physical examination. Data are presented as mean and range. Statistical analysis was performed with the Student t test for 2 variables. P 0.05 was considered significant.

In the course of the primary operation, if incarcerated omentum was encountered, blunt dissection was performed to reduce it. A 2-mm stab incision was performed over the umbilicus to allow the insertion of the tip of the suture passer. Using the device, and under direct vision, a nonabsorbable suture was introduced into the abdominal cavity on one side of the defect and retrieved back on the other side of the defect after once more passing the Carter-Thomason device. At least two times same procedure repeated. After all sutures were laid, the pneumoperitoneum pressure was released and the sutures were then tied extracorporeally using cobbler's needle. The suture knots were buried under the skin, and the incision was closed with a subcutaneous suture. Steps were shown in order.

Submission 02-11-2015, Peer Review 03-11-2015,

Acceptance 07-11-2015, Published 14-11-2015.

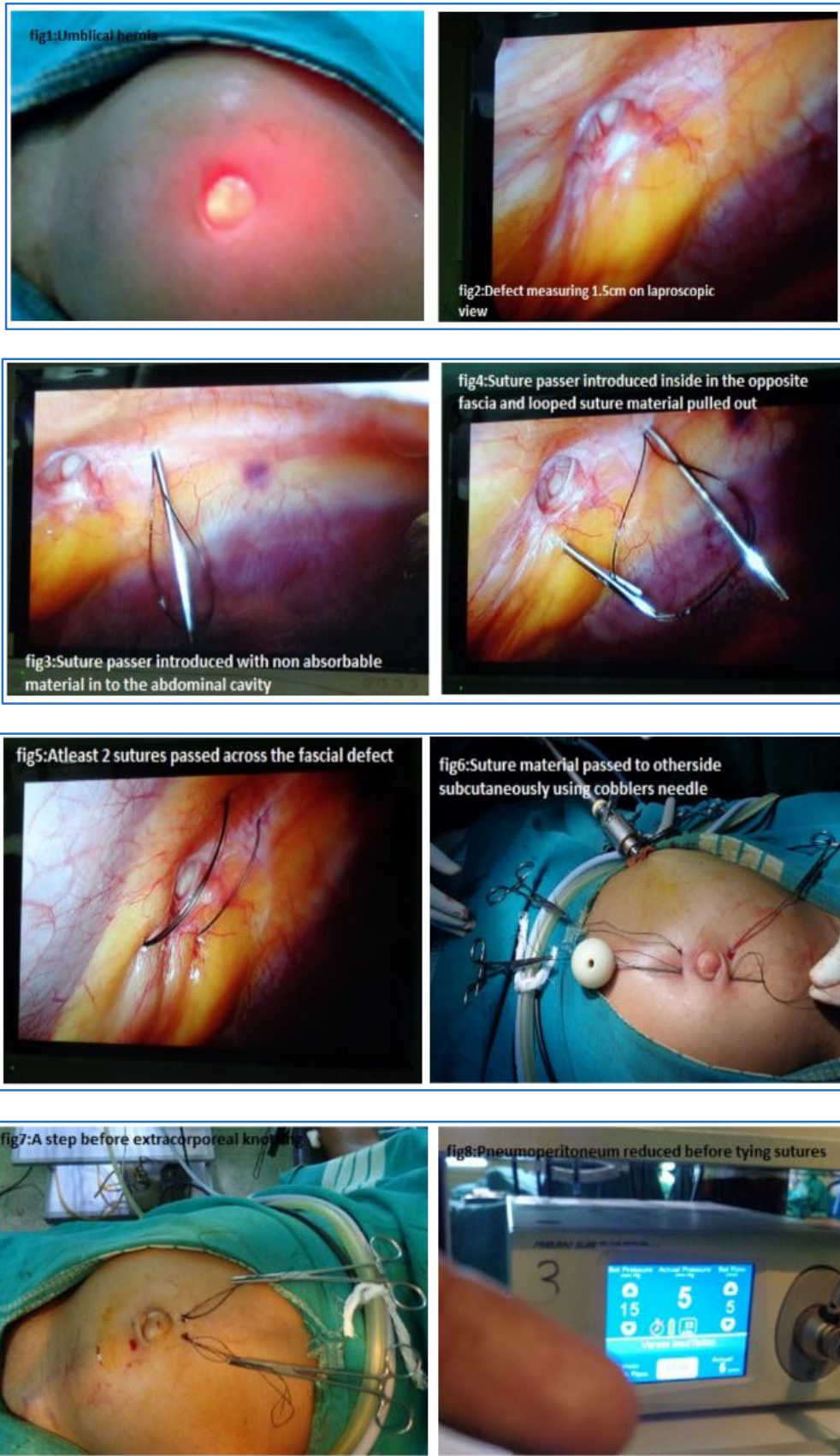
Corresponding Author:

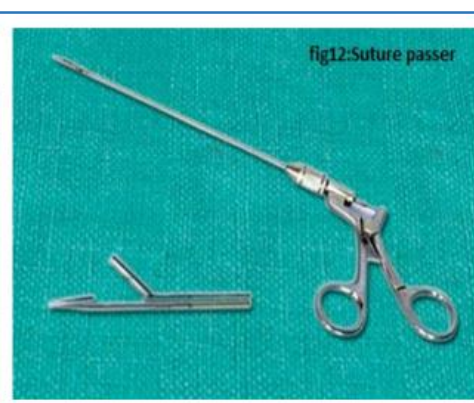
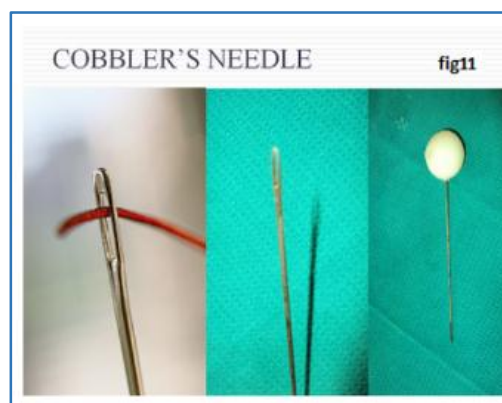
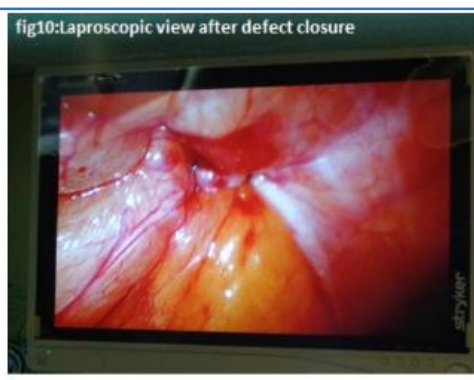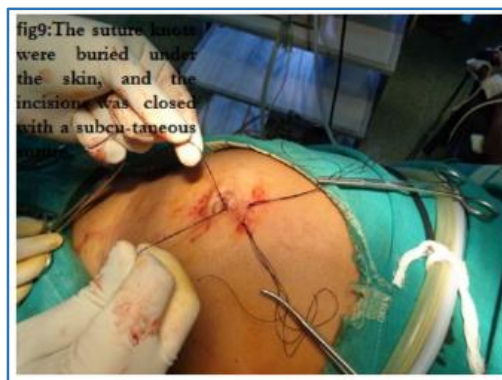Dr. R. Vinoth Prabu,

No. 6, Gandhi Nagar Cross street,
Madurai-625020.

E-mail: drvinothprabu@gmail.com

DOI: 10.18410/jebmh/2015/1148





RESULTS: Patient and hernia characteristics are summarized in Table 1. Thirty-six patients had a follow-up of 1 year or longer. Twenty two were males (60%), and the mean age was 42 years (range, 30 to 65). The mean diameter of the hernia defects was 1.45 cm (range, 0.5 to 2). Thirty percent of all the patients were found to have hernias with incarcerated omentum. None of the patients required conversion to open repair. The average follow-up was 34 months (range, 12 to 60). Postoperative complications, which included wound cellulitis and hernia recurrence, are shown in Table 2.

Open umbilical herniorrhaphy with the suture technique has been widely used over the last century. Despite attempts to vary suturing techniques, primary repair of umbilical hernias has yielded unfavorable results with recurrence rates of 10% to 20%.^{1,4} These rates have been markedly reduced to 1% with the use of mesh to achieve a tension-free repair.¹

The laparoscopic approach for umbilical hernia repair offers an advantage over the open technique. It allows for a wide fascial closure under direct vision and eliminates the need for anterior tissue dissection. These factors probably lead to a lower recurrence rate and complication rate. In our small series, the rate of recurrence (2.77%) was smaller when compared with that in previously published series on open techniques. And the recurrence rate was reduced to zero in patients who have defects smaller than 1.5 cm in diameter.

This technique, previously described by Carter⁵ for closure of trocar sites, is relatively easy to perform. Surgeons with basic laparoscopic skills should be able to implement this technique. The technique is no different from that involved in the closure of 10-mm port sites and adds no more than 5 minutes to 10 minutes to the procedure. Although postoperative pain was not formally studied, it was anecdotally only marginally greater than that from a normal 10-mm trocar closure site and did not affect hospital stay.

This 1-stage repair of the umbilical hernia has several advantages. With a reoperation rate of 2.77% (at 34 months), this saves on the cost of a second procedure in over 97% of patients. Furthermore, the material costs of a prosthetic mesh are considerably more than the costs of the suture material used in the technique described here.

Mean age(years)	42(30 to 65yrs)
Sex ratio(M:F)	22:14
Omental incarceration	11(30%)
Hernia defect	
<1.5cm	28(72.2%)
>1.5cm	8(27.8%)

TABLE 1

Hernia Diameter	Recurrences	Wound Infection
<1.5 cm	0/28	1/28 (3.6%)
>1.5 cm	1/8 (12.5%)	1/8 (12.5%)
Totals	1/36 (2.8%)	2/36 (7.7%)

Table 2

DISCUSSION: Umbilical hernia is an acquired defect in over 90% of adults.² Such hernias are relatively common and most likely occur in the fifth and sixth decades of life.³ Many of these lesions remain undetected until discovered in the course of laparoscopic procedures.

Despite the fact that the recurrence rate for defects over 1.5 cm was 12.5%, there would still be an argument for undertaking a primary suture closure of these larger defects in the presence of potential contamination. Given this increased recurrence rate when the facial defect measures greater than 1.5 cm, we now typically include an underlay of bio-absorbable mesh, in addition to suture closure, when repairing the larger hernia defects.

CONCLUSION: Laparoscopic umbilical repair with the cobblers needle and suture passer method is effective and durable. Our experience demonstrates a lower recurrence and complication rate compared with the published data on the open approach in a similar clinical setting. Better outcomes achieved with umbilical hernia defects smaller than 1.5 cm in diameter in terms of statistical significance. To adequately compare the proposed laparoscopic transfascial suture repair with the standard open suture closure, a prospective, randomized study is required. This technique can be done simultaneously during other laparoscopic procedures such as laparoscopic cholecystectomy, laparoscopic appendectomy where mesh

placement is not feasible in view of contamination being another advantage. We tried this new innovative method and proved successful on long term followup.

REFERENCES:

1. Arroyo A, Garcia P, Perez F, Andreu J, Candela F, Calpena R. Randomized clinical trial comparing suture and mesh repair of umbilical hernia in adults. *Br J Surg.* 2001; 88: 1321–1323.
2. Morgan WW, White JJ, Stambaugh S, Haller JA. Prophylactic umbilical hernia repair in childhood to prevent adult incarceration. *Surg Clin North Am.* 1970; 50: 839–845.
3. Harmel RP. Umbilical hernia. In: Nyhus LM, Condon RE, eds. *Hernia*. 3rd ed. Philadelphia, Pennsylvania: JB Lippincott, 1989; 347–352.
4. Celdran A, Bazire P, Garcia-Urena MA, Mariguam JL. Hernioplasty: A tension-free repair for umbilical hernia. *Br J Surg.* 1995; 82: 371–372.
5. Carter JE. A new technique of fascial closure for laparoscopic incisions. *J Laparoendoscopic Surg.* 1994; 4: 143–148.