

LAPAROSCOPIC TREATMENT OF CAESAREAN SCAR PREGNANCY

Purvi Khatri¹, Saunitra Inamdar², Mehul Salve³

¹Resident, Department of Obstetrics and Gynaecology, JNMC, DMIMS, Sawangi, Meghe, Maharashtra.

²Professor, Department of Obstetrics and Gynaecology, JNMC, DMIMS, Sawangi, Meghe, Maharashtra.

³Assistant Professor, Department of Obstetrics and Gynaecology, JNMC, DMIMS, Sawangi, Meghe, Maharashtra.

HOW TO CITE THIS ARTICLE: Khatri P, Inamdar S, Salve M. Laparoscopic treatment of caesarean scar pregnancy. J. Evid. Based Med. Healthc. 2018; 5(21), 1667-1669. DOI: 10.18410/jebmh/2018/349

PRESENTATION OF CASE

Caesarean scar pregnancy (CSP) is a rare form of ectopic pregnancy in which the gestational sac is implanted in a caesarean scar of the lower uterine segment.¹ The first case of CSP was reported by Larsen and Solomon in 1978.² Its incidence has risen in the past 5-6 years due to the rise in caesarean section rates worldwide. The incidence is estimated at 1:1,800 to 1:2,216 pregnancies.³⁻⁵ The increase use of imaging studies such as ultrasonography and magnetic resonance imaging (MRI) helps in early detection of these cases. Early diagnosis would help avoid complications such as scar rupture and excessive haemorrhage, which may require a hysterectomy. Caesarean scar pregnancy can endanger the woman's life and also affect future fertility.³ Patients who are vitally stable have more treatment options including conservative management. Hence, obstetricians/gynaecologists and radiologists must be highly vigilant of this potentially fatal complication.⁴

CASE REPORT

A 28-year-old woman with past history of two lower segment caesarean section was presented to the emergency department of AVBRH hospital, Sawangi Meghe with a history of 7 week 4 days of amenorrhea with complaints of backache and mild vaginal bleeding. She was G4P2L1D1A1 with previous one foetal demise. Patient was referred from a private hospital where she was treated with injection methotrexate i/v/o ectopic pregnancy.

On admission a transabdominal ultrasonography revealed single gestation sac of 6-week 3 days gestation age in lower uterine segment embedded to 4-5 mm in the previous scar site. Yolk sac was present, foetal pole present, cardiac activity absent. (Image 1&2). Beta human chorionic gonadotropin (beta- hCG) level on the day of admission was 10463 IU/L. In view of the scan findings and high beta- hCG level, a differential diagnosis of an ectopic pregnancy with myometrial invasion or scar pregnancy was made. The patient and her family were counselled about the management options and they opted for a laparoscopic

Financial or Other, Competing Interest: None.

Submission 30-04-2018, Peer Review 03-05-2018,

Acceptance 19-05-2018, Published 21-05-2018.

Corresponding Author:

Dr. Purvi Khatri,

Resident, Department of Obstetrics and Gynaecology,

Kapil Bidi Works, Shahpura Mohalla,

Beawar, Rajasthan – 305901.

E-mail: khatri.purvi@yahoo.com

DOI: 10.18410/jebmh/2018/349

removal. Baseline investigations and chest X-ray were done. Hysteroscopy was done to see the extent of gestation sac. A diagnostic laparoscopy confirmed the protrusion into the anterior wall of uterus near the isthmus, covered by the vesico-uterine fold of the peritoneum. Sharp dissection of the vesico-uterine peritoneal fold, and visualisation of ectopic pregnancy after giving sharp incision on the scar. Extirpation of the ectopic pregnancy located in the scar was performed, followed by bipolar coagulation, cutting and laparoscopic suturing of the defect in two layers followed by peritonisation (Image 3-5). Beta hCG on day 5 of laparoscopic removal was 645.18 IU/L. the patient was discharged on 6th day following the intervention and a histologic examination confirmed the existence of the ectopic pregnancy in the caesarean scar tissue.

She was counselled about contraception. Except for occasional mild vaginal bleeding, the patient was well. The patient was followed-up with serial vaginal scans fortnightly. Beta hCG after 1 month came to be of non-pregnant level.

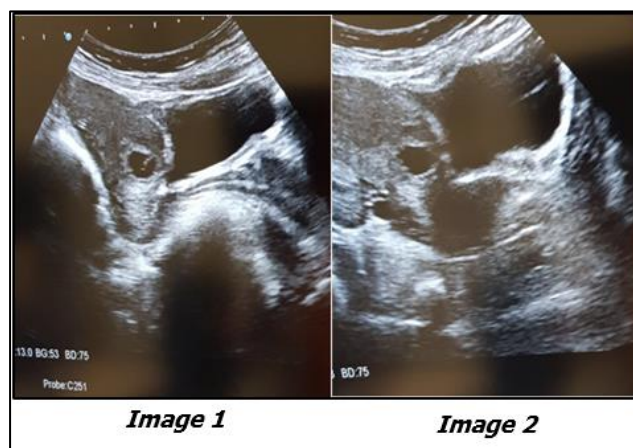


Image 1 & 2 - Transabdominal sagittal view of a gestational sac within a caesarean scar with myometrium anterior to the sac appears thin. 3-4 mm invasion into the myometrium.

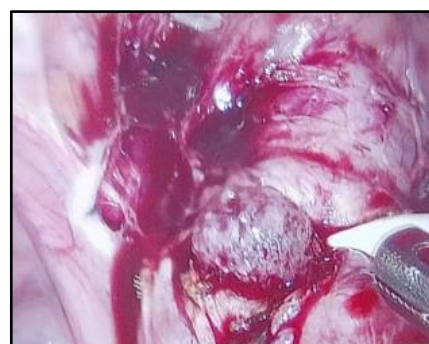


Image 3. Gestation Sac Seen After Giving Sharp Incision on Scar Tissue



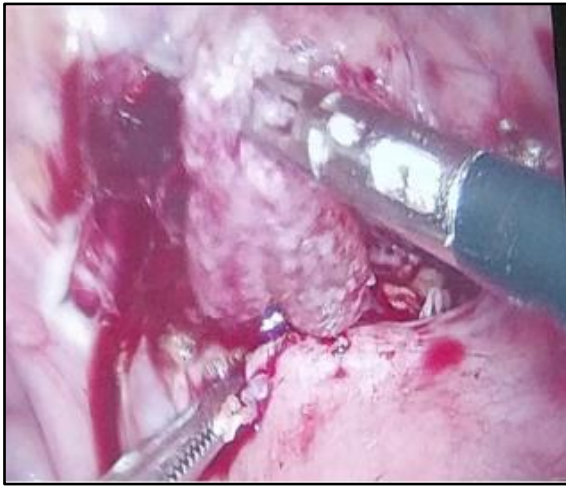

Image 4. Laparoscopic Removal of Gestation Sac with Product of Conception

CLINICAL DIAGNOSIS

On clinical history and examination, the diagnosis of scar pregnancy was made, which was supported by USG and Beta Hcg values.

PATHOLOGICAL DISCUSSION

The first case of CSP was reported by Larsen and Solomon in 1978.² The exact cause of CSP is not clear. The incidence has been reported to be 1: 1800 to 1: 2200 pregnancies.⁵ It is assumed that blastocyst nidates in the endometrium or myometrium in an area with microscopic dehiscence.⁶ Initial symptoms may be few but at a later stage, a CSP may result in uterine rupture, accompanied by massive haemorrhage, hemoperitoneum and haemorrhagic shock. Risk factor implicated in the development include the number of caesarean sections, the time interval between the previous caesarean section and the subsequent pregnancy, and the indications for the previous caesarean section, but it is not clear whether these factors are directly related to CSP.⁷ CSP were incidental ultrasonography finding in an asymptomatic woman while some present with mild painless vaginal bleeding. In a lesser percentage of patients, it was accompanied with mild to moderate abdominal pain. During examination if the CSP is in the process of rupture then uterus may be tender. A patient with a ruptured CSP may present in a state of collapse or hemodynamically unstable.⁷ Rarely CSP progressed beyond the first trimester. If pregnancy in a caesarean scar progressed to the second or third trimester, there would be an increased risk of uterine rupture with massive haemorrhage, with a high risk of hysterectomy causing serious maternal morbidity it can also affect future fertility.⁷

DIFFERENTIAL DIAGNOSIS

It can be early placenta accrete, incomplete abortion, cervical pregnancy, cornual pregnancy.

DISCUSSION OF MANAGEMENT

Clinical examination along with diagnostic modality like ultrasonography and MRI are useful in diagnosing scar pregnancy. Transvaginal sonography could soon be the gold

standard for the diagnosis of scar implantation.⁵ Diagnostic criteria are as follows:

- 1) An empty uterine cavity and an empty cervical canal.
- 2) A gestational sac in the anterior part of the uterine isthmus.
- 3) An absence of healthy myometrium between the bladder and gestational sac.⁵
- 4) Circular blood flow surrounding the sac must also be clearly visible.⁸⁻¹⁰ CSPs were noted to be well perfused on Doppler examination.⁵
- 5) Usually a transvaginal scan combined with color flow Doppler can be a reliable tool in diagnosing a CSP. MRI may be used as an adjunct to ultrasound scan. There are no specific guidelines available for the management of CSP. The main aim of treatment of CSP is to prevent massive blood loss and conserve the uterus to maintain future fertility, women's health, and quality of life.¹¹ Management is based on the gestational age, hCG levels, and presence of cardiac activity. It may be either medical or surgical. Various treatment options include local and/or systemic MTX administration, dilatation and curettage and excision of trophoblastic tissues using laparotomy or laparoscopy, bilateral hypogastric artery ligation, associated with dilatation and evacuation under laparoscopic guidance, and selective uterine artery embolization (UAE) in combination with curettage and/or MTX injections.^{1,12}

Conservative management is considered as an option has shown results of a shorter time of treatment and a more favourable effect.¹³ Some studies used UAE to reduce the blood loss. Lower bleeding volumes and hospitalization time were noted in the UAE group compared to the MTX group. No major side effects were noted in both groups. UAE followed by suction evacuation were recommended as a priority option.

Laparoscopy for CSP treatment is recommended for cases that have a deeply implanted gestational sac growing towards the abdominal cavity and bladder and are hemodynamically stable. Laparoscopy may be converted to a laparotomy if there is difficulty in achieving haemostasis.¹¹ Surgical treatment is recommended when medical management fails or when a patient is hemodynamically unstable. Presence of a large amount of free fluid in the pelvic cavity on ultrasound scan will require surgery. Internal iliac ligation with partial lesion resection and uterine neoplasty has significant advantages in the surgical treatment of CSPs.¹⁴ Huanxiao et al,¹⁵ reported 40 cases of CSP and recommended a transvaginal hysterotomy approach for removal of the ectopic tissue and repair of the uterine defect. The approach is safe, cost effective, less postoperative pain and blood loss and shorter hospital stay.¹⁶ The advantage of surgical; treatment is that the gestational mass can be removed, and the defect can be repaired simultaneously, however, none of the treatment modalities can guarantee uterine integrity.⁵

Jurkovic et al,⁵ recommended surgical repair of the scar either as a primary treatment or as a secondary operation after the initial treatment in women who desire further pregnancies. It could decrease the risk of recurrence of CSP. Once the gestational mass is surgically excised, it has been noted that hCG returns to normal much more quickly within one to two weeks. Dehiscence and repeat scar pregnancy have been reported following successful medical treatment with local MTX injections.

FINAL DIAGNOSIS

With history, clinical evaluation, radiological evidence and finally laparoscopic evaluation, final diagnosis of cesarean scar pregnancy was made. Here, laparoscopic surgical management was done which is technically simple and followed by good recovery.

REFERENCES

- [1] Rotas MA, Haberman S, Levгур M. Cesarean scar ectopic pregnancies: etiology, diagnosis, and management. *Obstet Gynecol* 2006;107(6):1373-1381.
- [2] Larsen JV, Solomon MH. Pregnancy in a uterine scar sacculus--an unusual cause of postabortal haemorrhage. A case report. *S Afr Med J* 1978;53(4):142-143.
- [3] Jurkovic D, Hillaby K, Woelfer B, et al. First-trimester diagnosis and management of pregnancies implanted into the lower uterine segment cesarean section scar. *Ultrasound Obstet Gynecol* 2003;21(3):220-227.
- [4] Seow KM, Huang LW, Lin YH, et al. Cesarean scar pregnancy: issues in management. *Ultrasound Obstet Gynecol* 2004;23(3):247-253.
- [5] Yela DA, Marchiani N. Conservative management of ectopic pregnancy in cesarean scar: case report. *Rev Bras Ginecol Obstet* 2013;35(5):233-237.
- [6] Seow KM, Hwang JL, Tsai YL, et al. Subsequent pregnancy outcome after conservative treatment of a previous caesarean scar pregnancy. *Acta Obstet Gynecol Scand* 2004;83(12):1167-1172.
- [7] Ash A, Smith A, Maxwell D. Cesarean scar pregnancy. *BJOG* 2007;114(3):253-263.
- [8] Godin PA, Bassil S, Donnez J. An ectopic pregnancy developing in a previous caesarian section scar. *Fertil Steril* 1997;67(2):398-400.
- [9] Seow KM, Hwang JL, Tsai YL. Ultrasound diagnosis of a pregnancy in a cesarean section scar. *Ultrasound Obstet Gynecol* 2001;18(5):547-549.
- [10] Vial Y, Petignat P, Hohlfeld P. Pregnancy in a cesarean scar. *Ultrasound Obstet Gynecol* 2000;16(6):592-593.
- [11] Litwicka K, Greco E. Cesarean scar pregnancy: a review of management options. *Curr Opin Obstet Gynecol* 2011;23(6):415-421.
- [12] Hwu YM, Hsu CY, Yang HY. Conservative treatment of caesarean scar pregnancy with transvaginal needle aspiration of the embryo. *BJOG* 2005;112(6):841-842.
- [13] Wang JH, Xu KH, Lin J, et al. Methotrexate therapy for cesarean section scar pregnancy with and without suction curettage. *Fertil Steril* 2009;92(4):1208-1213.
- [14] Ben Nagi J, Helmy S, Ofili-Yebovi D, et al. Reproductive outcomes of women with a previous history of caesarean scar ectopic pregnancies. *Hum Reprod* 2007;22(7):2012-2015.
- [15] Huanxiao Z, Shuqin C, Hongye J, et al. Transvaginal hysterotomy for cesarean scar pregnancy in 40 consecutive cases. *Gynecol Surg* 2015;12(1):45-51.
- [16] Hasegawa J, Ichizuka K, Matsuoka R, et al. Limitations of conservative treatment for repeat cesarean scar pregnancy. *Ultrasound Obstet Gynecol* 2005;25(3):310-311.