

## LAPAROSCOPIC SURGERY IN THE MANAGEMENT OF EARLY GASTRIC CANCER

Abhijit Sarma<sup>1</sup>

<sup>1</sup>Assistant Professor, Department of General Surgery, Gauhati Medical College, Guwahati, Assam, India.

### ABSTRACT

#### INTRODUCTION

This study was performed to check Laparoscopic Surgery in the management of early Gastric Cancer. For that we choose laparoscopic and laparoscopic Assisted Gastrectomies for 119 cases. It was performed during the period from June 1996 to February 2002 in Kameda Medical Center, Kamogawa, Japan. Male and female ratio was 2.78:1. The age range was 48-88 years (65.5).

#### MATERIALS AND METHODS

1. Laparoscopic Intra-gastric Mucosal Resection (LIMR).
2. Local Resection by Lesion Lifting Method (LLM).
3. Laparoscopy-Assisted Distal Gastrectomy (LADG).
4. Intra-gastric Mucosal Resection through laparotomy.

#### RESULTS OF THIS STUDY AFTER USING SURGICAL TECHNIQUES ARE AS FOLLOWS-

1. The tear was successfully closed by intra-gastric hand suturing technique.
2. All the planned laparoscopic procedures were completed in all the cases and the operation was finished after the confirmation of tumor free margins on frozen section biopsy specimen.
3. All resected specimen underwent detailed histopathologic examination. Subsequent diagnosis includes stomach cancer in 106 cases, duodenal cancer in 1 case and stomach adenoma in 5 cases. 8 cases of stromal tumors were resected laparoscopically.
4. We have not lost even a single patient in follow up or due to mortality. Five year follow up is present in the first year group.
5. 06 patients who were diagnosed with EGC have been successfully treated with 4 laparoscopic techniques at our institute from June 1996 to February 2002.

#### CONCLUSION

We, in our study had no mortality or local recurrence to date but our follow up is obviously too short to draw any conclusions. If patients are selected properly, we on the basis of our study propose that laparoscopic procedures are curative.<sup>1,2</sup> When performed by a skilled surgeon, laparoscopic resection is a safe and useful technique in the management of Early Gastric Cancer.

#### KEYWORDS

Early Gastric Cancer (EGC), Laparoscopic Surgery, Laparoscopic Intra-gastric Mucosal Resection (LIMR), Laparoscopic Assisted Distal Gastrectomy (LADG), Lesion Lifting Method (LLM).

**HOW TO CITE THIS ARTICLE:** Sarma A. Laparoscopic surgery in the management of early gastric cancer. J. Evid. Based Med. Healthc. 2016; 3(18), 728-732. DOI: 10.18410/jebmh/2016/165

**INTRODUCTION:** Early gastric cancer (EGC) is defined as a gastric cancer confined to the mucosa/submucosa layer regardless of the presence of lymph node metastasis. In Japan, where the incidence of gastric cancer is very high, this early form represents more than 40% of cancer that are diagnosed by means of mass survey.

The use of laparoscopic surgery in the treatment of gastric cancer has not yet met with widespread acceptance, thus, it should be regarded as still in the developmental phase.

**MATERIALS AND METHODS:** Herein, we present the results of our experience with laparoscopic and laparoscopic assisted gastrectomies for 119 cases of EGC performed during the period from June 1996 to February 2002 in Kameda Medical Center, Kamogawa, Japan. Male to female ratio was 2.78: 1. The age range was 48-88 years (65.5).

Among the 119 patients, stomach cancer were 106, submucosal tumor 8 and adenoma were 5 (Table 1). Only cases of stomach cancer are included in the present study.

No. of Patients	119
Stomach Cancer	106
Submucosal tumour (SMT)	8
Adenoma	5
Male: Female Ratio (78 Males and 28 females)	2.78:1
Age: 49-88 years (Mean age: 65.5 years)	
<b>Table 1: Laparoscopic surgery for stomach cancer</b>	

Submission 27-01-2016, Peer Review 10-02-2016,  
Acceptance 17-02-2016, Published 03-03-2016.

Corresponding Author:

Dr. Abhijit Sarma,

Assistant Professor, Department of General Surgery,  
Gauhati Medical College, Guwahati, Assam, India.

E-mail: drabhijitsarmaghy@yahoo.in

DOI: 10.18410/jebmh/2016/165

Patients were carefully selected by intensive preoperative workup consisting of all routine lab and radiological investigations. In our center, all patients of EGC are first admitted in the Gastroenterology unit where panendoscopy and dye study are done. Due to the vast experience and expertise, gastroenterologist at KMC could fairly accurately (96%) classify the type of EGC and also the depth of invasion as M or SM1/SM2 on upper GI endoscopy. Elevated mucosal cancer <25mm differentiated depressed mucosal cancer <15mm are dealt with EMR (Endoscopic mucosal resection). Thus about 60-70 patients are managed by EMR every year in the Gastroenterology department.

For laparoscopic surgery, we have chosen preoperatively diagnosed mucosal cancer >25mm elevated and <15mm depressed lesion without ulcer formation and submucosal lesion (SM1).<sup>3,4,5,6</sup>

We, have performed laparoscopic intragastric mucosal resection (LIMR) in 8 cases, local resection using lesion lifting method (LLM) in 33 cases, laparoscopy-assisted distal gastrectomy (LADG) in 59 cases and intragastric mucosal resection through laparotomy in 6 cases (Table 2).

Sl. No.	Procedures done	
1.	LIMR	8
2.	LLM	33
3.	LADG	59
4.	IMRL	6

**Table 2**

**INDICATIONS:**

1. Local resection using Lesion Lifting Method (LLM)-for patients with suspected mucosal cancer which cannot be lifted up by saline injection.
2. Laparoscopic Intragastric Mucosal Resection (LIMR)-for mucosal cancer which is located at the cardia and is not a good candidate for EMR.
3. Laparoscopic Intragastric Mucosal Resection through Laparotomy-for early cancer of the remnant stomach ( for the patients with previous gastrectomy), and for the case with an early cancer at the upper stomach and combined advanced cancer at the antrum which requires open distal gastrectomy, and the case with a malignant tumor such as a pancreatic head tumor associated with mucosal cancer located near the oesophago-cardiac junction, avoiding total gastrectomy combined with pancreaticoduodenectomy (PD):the aim being to avoid total gastrectomy.
4. Laparoscopy Assisted Distal gastrectomy (LADG)-for early cancer with unclear margins which cannot be successfully managed by local resection using lesion lifting.

LADG was included in the series of laparoscopic surgery in January 1998. It has become popular despite late adoption as it includes mucosal cancer with unclear margins and submucosal cancer without massive submucosal invasion (sm1) as D1/D2 lymph node dissection can be done in LADG.

**SURGICAL TECHNIQUE<sup>7</sup>:**

**1. Laparoscopic Intragastric Mucosal Resection (LIMR)<sup>4,8</sup>:** Three working ports using 5mm radially expandable sleeve (RES) are placed in the stomach under gastrofibroscopic vision. The stomach is then insufflated with CO<sub>2</sub>, and surgical instruments are introduced. The mucosal and submucosal layers around the lesion are resected with sufficient margins. Using RES in LIMR is a simpler, less invasive procedure and repair of the port sites on the gastric wall is not required.

**2. Local Resection by Lesion Lifting Method (LLM)<sup>4,9</sup>:** The cancerous lesion, which was previously tagged by marker clips is visualised endoscopically and the gastric wall around the cancerous lesion is exposed laparoscopically. The abdominal wall and gastric wall in the vicinity of the lesion are pierced using a 12G sheathed needle. A small metal rod with a fine wire which can be transformed to T-bar is introduced into the stomach through the outer sheath. By retracting the T-formed metal rod, the lesion can be lifted precisely (i.e., lesion lifting method). Wedge resection at a sufficient distance is carried out using an endoscopic stapler. The indication of this technique are lesions of anterior wall, lesser and greater curvature of the stomach. For posterior wall lesions,<sup>10</sup> we describe a novel method. We, divide the omentum and enter in the omental bursa. Thus, posterior wall is rotated and then resection by LLM can be done in the same manner.

**3. Laparoscopy-Assisted Distal Gastrectomy (LADG)<sup>11,12,13</sup>:** The stomach is resected like in conventional distal gastrectomy. The operation is performed by 4 or 5 portal system including a Hasson cannula at the umbilical site placed by open technique. The omentum is divided first using Harmonic Scalpel (laparoscopic coagulating shears, LCS). The right-gastroepiploic (GE) vein is clipped and divided at the lower margin of the pancreas. The GE artery arising from the gastroduodenal artery is exposed and resected. The stomach is elevated to expose the posterior of the stomach and the lesser sac is opened. The right gastric artery and vein are exposed, clipped and divided. The bulb of the duodenum is skeletonized. The cutting of the duodenum is extended to the lower pole of the spleen, and the left GE artery and vein are clipped and divided. The attachment between the posterior of the stomach and the pancreas is cut and the left gastric vein and artery are identified. The serosa at the upper border of the pancreas is cut to expose the left gastric and vein and artery. The left gastric vein is skeletonized and clipped and divided. Then the left gastric artery is exposed and ligated doubly by clips and divided. The lower esophagus is exposed and the vagus nerves are divided. The lymph nodes along the lesser curvature are dissected to expose the lesser curvature of the stomach. The procedure described here mobilizes the stomach sufficiently. The small incision about 5 cm long is placed

at the subxiphoidal site and the mobilized stomach is pulled out. Then resection of the stomach and reconstruction are performed like in conventional distal gastrectomy. In this procedure, D1+ a lymph node dissection is possible.

For mucosal early gastric cancer of 4cm or submucosal lesions (sm<sub>1</sub>), LADG is performed. This allows resection of D1/D2 lymph node dissection with reconstruction by Billroth I/II or intestinal interposition. The tumor is excised with a non-cancerous rim of 2cm.

**4. Intra gastric Mucosal Resection through laparotomy<sup>14</sup>:** Laparotomy is performed first, followed by placement of 3 trocars under open direct vision. The resection of the lesion is done as described in LIMR.

**RESULTS:** Intraoperative complication Unexpected incidences were experienced in two patients. In one patient who underwent laparoscopic intra gastric surgery, the stomach was ruptured because of excessive intra gastric pressure when fibrin glue was sprayed using mechanical injection. The tear was successfully closed by intra gastric hand suturing technique.

In another patient, who underwent local resection using lesion lifting method, the tip of the scissors was broken and a fragment fell into the abdominal cavity. This happened when the scissors was applied on the marking clips and approximated. The lost fragment was successfully retrieved. These two incidences were experienced early in the series.

Postoperative complication to date includes wound infection (2), anastomotic leakage (2), stenosis (2), port site recurrence (1), pancreatic fistula (1), pulmonary embolism (1) and vomiting (1) (Table 3). Gastric outlet stenosis that developed in two patients after local resection using lesion lifting method was temporary. The symptoms developed because resection was performed near the pyloric ring in one patient and in another resection was along the lesser curvature which included nerve fibers. The symptoms disappeared on conservative treatment, though balloon dilation was done in one.

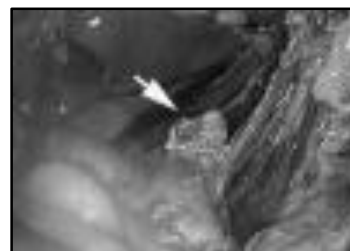Wound infection	2
Anastomotic Leakage	2
Gastric outlet Stenosis	2
Port Site recurrence	1
Pancreatic fistula	1
Pulmonary Embolism	1
Vomiting	1
<b>Table 3: Complications</b>	

All the planned laparoscopic procedures were completed in all the cases and the operation was finished after the confirmation of tumor free margins on frozen section biopsy specimen. One of the patients was diagnosed by frozen section histological examination as having submucosal invasion and another as having cancer positive margin. These 2 patients underwent additional distal gastrectomy in the same operation series.

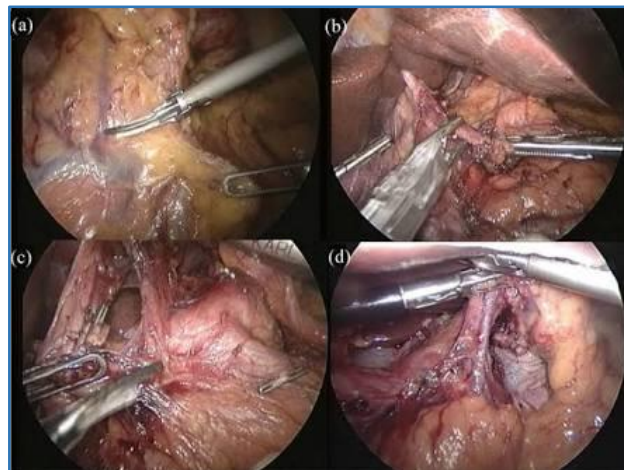
All resected specimen underwent detailed histopathologic examination. Subsequent diagnosis includes stomach cancer in 106 cases, duodenal cancer in 1 case and stomach adenoma in 5 cases. 8cases of stromal tumors were resected laparoscopically. Yearly distribution of procedures shows a rising trend in LADG. In 13 cases we performed staging laparotomy. These cases are not included in the present study.

The reported cumulative mortality rate due to recurrence of EGC ranges from 2-4% in the literature.<sup>14</sup> In our study, we have 1 case of port site recurrence. The tumor has spread to anterior abdominal wall involving all the port sites.

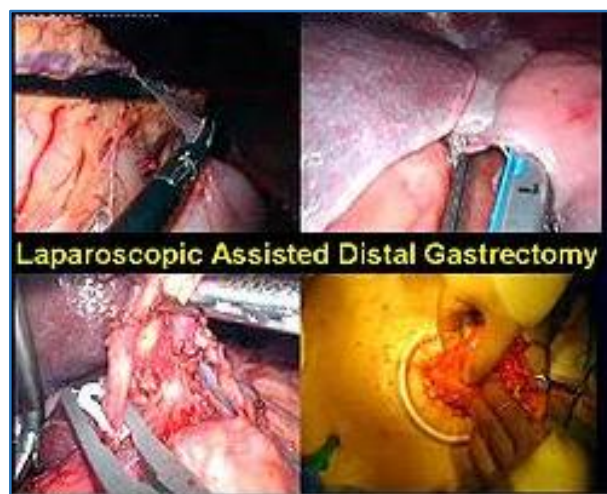We have not lost even a single patient in follow up or due to mortality. Five year follow up is present in the first year group.



**Fig. 1**



**Fig. 2**



**Fig. 3**

**DISCUSSION:** The trends in the management of EGC are different between Japan and the West. European surgeons have been employing more aggressive surgery for early gastric cancer while in Japan, less invasive methods (EMR/functioning preserving gastrectomies) are performed. It depends on different treatment experiences and diagnostic techniques.

Careful patient selection is a must to reduce local recurrence.<sup>15</sup> Multifocal lesions, either synchronous/metachronous are not uncommon in the stomach. Patients at risk for multicentricity of EGC are male, over 60 years of age, depressed type of well-differentiated adenocarcinoma (indicate the literature here).

Nowadays, limited surgery in EGC is recommended because the rate of lymph node metastases is 2.4% for tumors limited to the mucosa, and preservation of regional lymph nodes may enhance postoperative immunocompetence.<sup>16</sup> But extended lymphadenectomy appears to prolong the survival of patients whose tumors invades the submucosa or for EGC located in distal third of the stomach.<sup>17,18</sup>

Laparoscopic surgery for stomach cancer is useful to patients with early cancer which cannot be cured by endoscopic mucosal resection.

In KMC, all the patients with stomach cancer are sent to the department of gastroenterology first. Most of the mucosal cancer are resected by the technique of endoscopic mucosal resection (EMR) by gastroenterologists.

In the department of gastroenterology of KMC, about 50 patients with early (mucosal) stomach cancer are managed by EMR a year, and the number of cases which are excluded from the indication of EMR is 130-140 a year and these patients are sent to the department of surgery for open or laparoscopic surgery. Accuracy of endoscopic diagnosis about depth invasion in patients with mucosal cancer is 96% in the dept. of gastroenterology in KMC, which has been confirmed by post EMR histopathological examination.

Patients with suspected mucosal cancer which cannot be lifted up by saline injection are sent to surgeons for laparoscopic partial resection using lesion lifting method. Mucosal cancer which is located at the cardia and is not a good candidate for EMR can be managed by laparoscopic intragastric mucosal resection. Laparoscopic intragastric mucosal resection through laparotomy are indicated for early cancer of the remnant stomach (for the patients with previous gastrectomy), and the case with early cancer at the upper stomach and combined advanced cancer at the antrum which requires open distal gastrectomy. The aim of this procedure is to avoid total gastrectomy. This was also performed in the case with a malignant tumour of the pancreatic head tumour associated with mucosal cancer located near the oesophago-cardiac junction, avoiding total gastrectomy combined with pancreaticoduodenectomy (PD). LADG can be indicated for early cancer with unclear margin that cannot be successfully managed by local resection using lesion-lifting method. Basically lesion-lifting method and mucosal resection are indicated only for mucosal cancer. However LADG can be indicated not only for mucosal cancer

with unclear margin but also for submucosal cancer without massive submucosal invasion (sm1-2) because D-1 + or D-2 lymph node dissection can be performed in LADG. That is why the number of cases of LADG has been increasing rapidly in spite of late adoption in this series.

Some authors are expanding the indication of LADG for stomach cancer. However, we are adhering to the conservative policy considering higher malignancy of stomach cancer than colon cancer. Besides, the more complicated anatomy of the stomach makes laparoscopic gastric surgery more difficult.

We are limiting the indication of laparoscopic gastric surgery only to the cases in which D1+ $\alpha$  dissection is sufficient. Patients who are excluded from the indications for EMR and laparoscopic surgery are candidates for open surgery.

To expand the indication of laparoscopic surgery for stomach cancer, we need more discussion and accumulation of reports of experiences.

**CONCLUSION:** 106 patients who were diagnosed with EGC have been successfully treated with 4 laparoscopic techniques at our institute from June 1996 to February 2002. We, in our study had no mortality or local recurrence to date but our follow up is obviously too short to draw any conclusions. If patients are selected properly, we on the basis of our study propose that laparoscopic procedures are curative.<sup>1,2</sup> When performed by a skilled surgeon, laparoscopic resection is a safe and useful technique in the management of EARLY GASTRIC CANCER.

#### REFERENCES:

1. Azagra JS, Goergen M, De-Simone P, et al. Minimally invasive surgery for gastric cancer. *Surg Endosc* 1999;13(4):351-7.
2. Huscher CG, Anastasi A, Crafa F, et al. Laparoscopic gastric resections. *Semin Laparosc Surg* 2000;7(1):26-54.
3. Ohgami M, Kumai K, Otani Y, et al. Laparoscopic wedge resection of the stomach for early gastric cancer using a lesion-lifting method. *Dig Surg* 1994;11:64-67.
4. Ohgami M, Otani Y, Furukawa T, et al. Curative laparoscopic surgery for early gastric cancer: eight years experience. *Nippon Geka Gakkai Zasshi* 2000;101(8):539-45. Review.
5. Ohgami M, Otani Y, Kitajima M. Laparoscopic surgery for early gastric cancer—its advantage and pitfall. *Gan To Kagaku Ryoho* 1997;24(5):532-7. Review.
6. Ohgami M, Otani Y, Kumai K, et al. Laparoscopic surgery for early gastric cancer—its advantages and pitfalls. *Gan To Kagaku Ryoho* 1998;25(4):484-92. Review.
7. Kitano S, Shimoda K, Miyahara M, et al. Laparoscopic approaches in the management of patients with early gastric carcinomas. *Surg Laparosc Endosc* 1995;5:359-362.

8. Taniguchi E, Ohashi S, Takiguchi S, et al. Laparoscopic intragastric surgery using a radially expandable sleeve. *Surg Endosc* 2000;14(5):505-7.
9. Ohgami M, Otani Y, Kumai K, et al. Curative laparoscopic surgery for early gastric cancers: five years experience. *World J Surg* 1999;23(2):187-92.
10. Sekimoto M, Tamura S, Hasuike Y, et al. A new technique for laparoscopic resection of a submucosal tumour on the posterior wall of the gastric fundus. *Surg Endosc* 1999;13(1):71-4.
11. Kitano S, Iso Y, Moriyama M, et al. Laparoscopy-assisted billroth i gastrectomy. *Surg Laparosc Endosc* 1994;4:146-148.
12. Shimizu S, Uchiyama A, Mizumoto K, et al. Laparoscopically assisted distal gastrectomy for early gastric cancer: is it superior to open surgery? *Surg Endosc* 2000;14(1):27-31.
13. Yano H, Monden T, Kinuta M, et al. The usefulness of laparoscopy-assisted distal gastrectomy in comparison with that of open distal gastrectomy for early gastric cancer. *Gastric Cancer* 2001;4(2):93-7.
14. Yamashita Y, Maekawa T, Sakai T, et al. Transgastrostomal endoscopic surgery for early gastric carcinoma and submucosal tumor. *Surg Endosc* 1999;13(4):361-4.
15. Cuschieri A. Laparoscopic gastric resection. *Surg Clin North Am* 2000;80(4):1269-84, viii.
16. Namieno T, Koito K, Higashi T, et al. General pattern of lymph node metastasis in early gastric cancer. *World J surg* 1996;20(8):996-1000.
17. Adachi Y, Mori M, Maehara Y, et al. Prognostic factors of node-negative gastric carcinoma: univariate and multivariate analyses. *J Am Coll Surg* 1997;184:373-377.
18. Asao T, Hosouchi Y, Nakabayashi T, et al. Laparoscopically assisted total or distal gastrectomy with lymph node dissection for early gastric cancer. *Br J Surg* 2001;88(1):128-32.