

# CASE REPORT

## KEROS TYPE 3 OLFACTORY FOSSA: A CASE REPORT

Feroz Hussain<sup>1</sup>, Mir Alam Siddique<sup>2</sup>

### HOW TO CITE THIS ARTICLE:

Feroz Hussain, Mir Alam Siddique. "Keros Type 3 Olfactory Fossa: A Case Report". Journal of Evidence based Medicine and Healthcare; Volume 2, Issue 17, April 27, 2015; Page: 2628-2633.

**ABSTRACT:** A 45 year old lady presented with spontaneous onset CSF rhinorrhoea. There was no history of any head injury, nasal surgery or past history of any intra-cranial tumour. Clinical procedures like CSF analysis and CT brain were done and was diagnosed as a case with keros type 3 olfactory fossa with a small hole in right cribriform plate. Later MR cisternography was performed for confirmation. Olfactory fossa is a variable depression in the cribriform plate that is bounded medially by the perpendicular plate of ethmoid and laterally by the lateral lamella. It contain olfactory nerves and a small artery.

**KEYWORDS:** Olfactory fossa, Lateral lamella, Cribriform plate.

**INTRODUCTION:** Keros classification is a method of classifying the depth of olfactory fossa. Olfactory fossa is a variable depression in the cribriform plate that medially is bounded by the perpendicular plate of ethmoid and laterally by the lateral lamella. It contain olfactory nerves and a small artery.<sup>(1)</sup>

The very thin horizontal cribriform plate of ethmoid bone is bounded laterally by the vertical lateral lamella. The lateral lamella joins the cribriform plate to the fovea ethmoidalis.<sup>(2, 3, 4, 5)</sup>

Fovea ethmoidalis is an extension of frontal bone orbital plate that primarily separates the ethmoidal cells from anterior cranial fossa. Fovea ethmoidalis forms the roof of ethmoidal labyrinth. Medially, the fovea ethmoidalis attaches to the lateral lamella of cribriform plate, that is part of ethmoid bone.<sup>(2, 3, 4, 5)</sup>

The depth of olfactory fossa is determined by the height of lateral lamella of cribriform plate.<sup>(1)</sup>

Keros in 1962 classified the depth of olfactory fossa into 3 categories:

- I. Type 1: has a depth of 1-3 mm. (26.3% population).
- II. Type 2: has a depth of 4-7 mm. (73.3% population).
- III. Type 3: has a depth of 8-16 mm. (0.5% population).

The type 3 essentially exposes more of the very thin cribriform plate to potential damage from trauma, tumour erosion, CSF erosion (In benign intracranial hypertension) & local nasal surgery or orbital decompression.<sup>(6)</sup>

Thin bone in the skull base, especially the cribriform plate, is susceptible to erosion, encephalomeningocele herniation and CSF leaks.<sup>(6)</sup>

The most common sites of erosion or defects in the skull base are:

- I. Cribriform plate- (51%).
- II. Sphenoid lateral pterygoid recess - (31%).
- III. Ethmoid roof- (8%).
- IV. Perisella - (10%).

# CASE REPORT

---

**CASE REPORT:** A lady, 45 years of age, presented with spontaneous onset CSF rhinorrhoea for which she was admitted in the Department of ENT, Fakhruddin Ali Ahmed Medical College and Hospital, Barpeta. There was no significant history of CSF leak in the past. Later CT-brain and MR cisternography was done, which diagnosed this to be a case of keros type 3 olfactory fossa with a tiny hole in the right cribriform plate of ethmoid, which was the cause for CSF leak. She had no past history of hypertension but was showing a constant blood pressure of around 160/90 mm of Hg during her hospital stay for which she was prescribed antihypertensive. She was treated conservatively for around 4 weeks and then advised surgery when the conservative measures failed. Later fascial grafting was done endoscopically through the nasal route to seal the hole in the right cribriform plate under GA.

**DISCUSSION:** Keros type 3 olfactory fossa is very rare and is present in 0.5 % of population only. Cribriform plate is very thin in this cases which therefore becomes the potential site for damage from trauma, tumour erosion and benign raised intra-cranial pressure and therefore present with CSF rhinorrhea.

CSF rhinorrhea is a rare but potentially devastating condition that can lead to significant morbidity and mortality for the patient. Disruption of barriers between the sinonasal cavity and anterior and middle cranial fossa is the underlying factor leading to the discharge of CSF into the nasal cavity. The resulting communication with the CNS can result in a multitude of infectious complications that impart significant morbidity and potentially disastrous long-term deficits for the patient.

Spontaneous onset CSF rhinorrhea in this case is attributed to raised intra-cranial pressure and account for about 29% of all cases of CSF rhinorrhea.

Raised intra-cranial pressure in cases of Keros type 1 and 2 usually does not present with spontaneous onset CSF rhinorrhea.

Besides this there are some other causes for CSF rhinorrhea like:

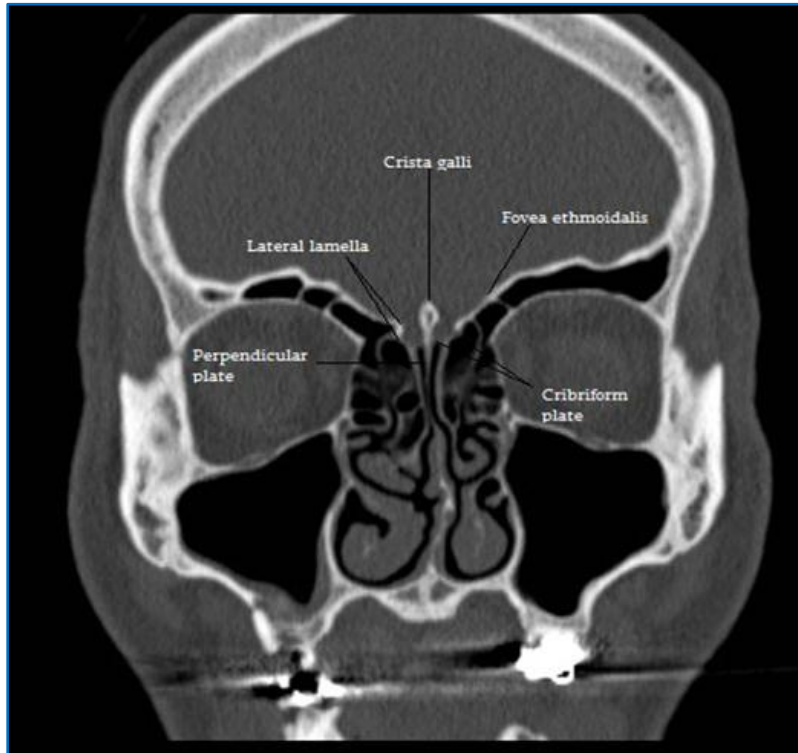
- a) Iatrogenic (11) (e.g. sinus surgery, trans-sphenoidal hypophysectomy, craniotomy etc.)-37%.
- b) Trauma-10-30%.
- c) Congenital (e.g. congenital hydrocephalus, congenital skull base defects, persistent craniopharyngeal canal) -11%.
- d) Tumour-3%.

The exact cause of spontaneous onset CSF leaks largely remain unknown but an underlying weakness of spinal meninges is generally suspected and a more or less trivial traumatic event often precedes the onset of symptoms.<sup>(7)</sup>

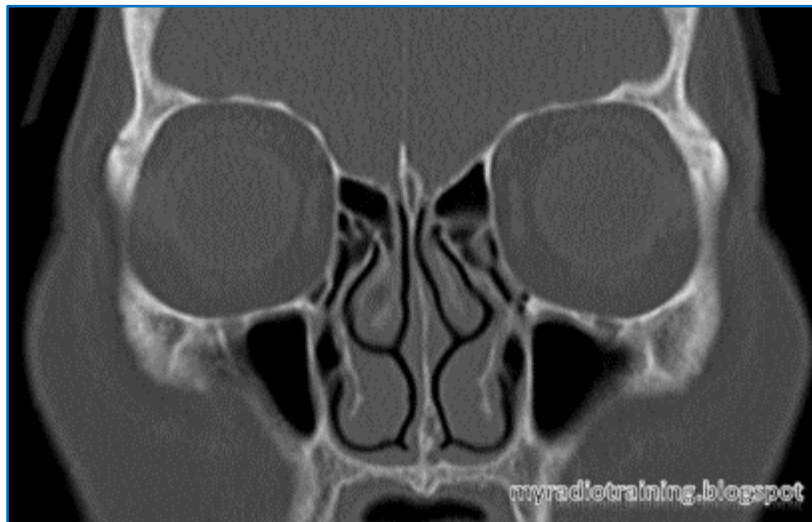
In approximately 1/5<sup>th</sup> of patients with spontaneous onset CSF rhinorrhoea, spontaneous retinal detachment at an early age and subtle skeletal abnormalities like Marfan syndrome is commonly observed.<sup>(7)</sup> but no evidence of the above abnormalities are found in this patient.

## CASE REPORT

**CONCLUSION:** The knowledge about the depth and types of olfactory fossa and the anatomic relations between fovea ethmoidalis and lateral lamella is essential in the prevention of complications in endoscopic nasal surgeries.

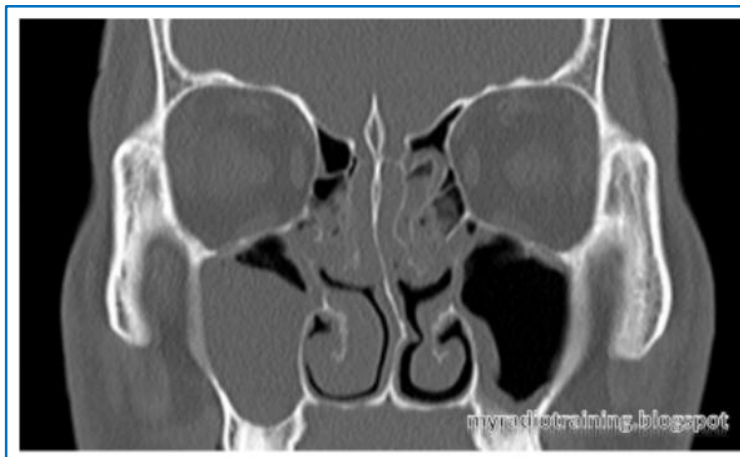


**Fig. 1: CT-Radiograph showing boundaries of olfactory fossa**

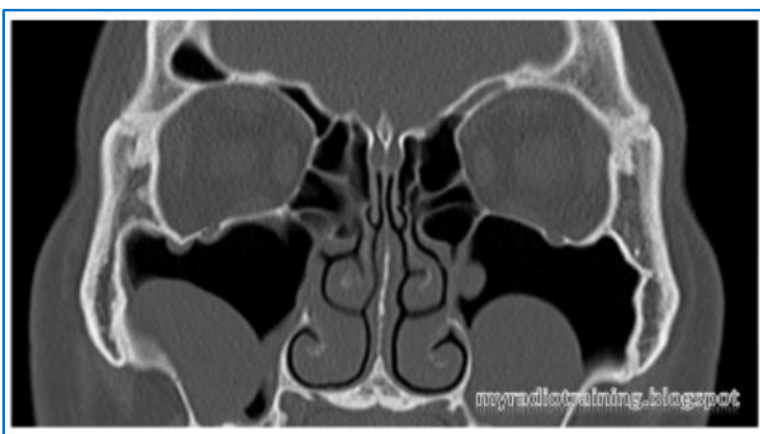

**Fig. 2: CT-Radiograph showing Keros type-I olfactory fossa**

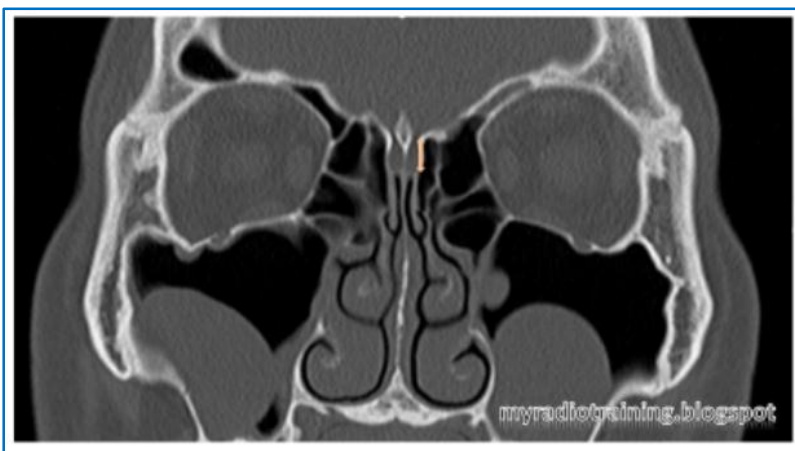## CASE REPORT



**Fig. 3: CT Radiograph showing Keros type-II Olfactory Fossa**

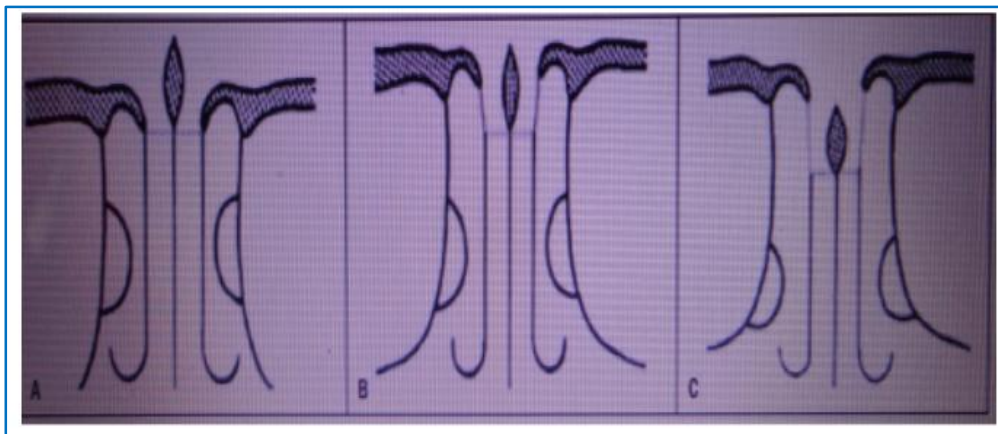


**Fig. 4: CT Radiograph showing Keros type-III Olfactory Fossa**

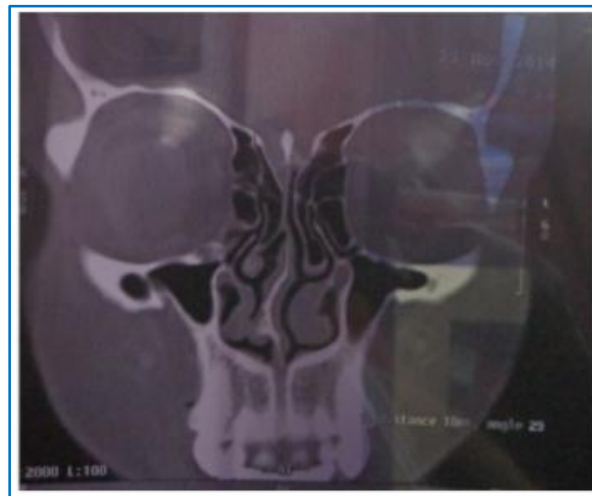

**Fig. 5: Type of Olfactory fossa according to Keros Classification is determined by height of lateral lamella(As shown by the arrow)**

# CASE REPORT



**Fig. 6: Schematic representation of the three Types of olfactory fossa according to keros Classification: A, type I: B, type II: C, type III**



**Fig. 7: Present case with Keros Type- III Olfactory Fossa**

## ACKNOWLEDGEMENT:

- This work has been honoured by the blessings of a number of people. It would therefore be incomplete if mention is not made of all those.
- My utmost gratitude goes to one of my relative Mrs. Forzina Ahmed without which this work would have been impossible.
- My utmost gratitude goes to Ms Gunjana Gayatri Bora for her unswerving support and constructive suggestions throughout the work.
- I express my deep sense of gratitude to my father Mr. Samsul Hussain, my mother Mrs. Serina Hussain, my brother Mr Aftab Hussain and my friend Ms Asreen Suhana for their blessings.

# CASE REPORT

## REFERENCES:

1. Keros P. On the practical value of differences in the level of the lamina cribrosa of the ethmoid. Z Laryngol Rhinol Otol. 1962; 41:809-813.
2. Ohnishi T, Bony defects and dehiscences of the roof of the ethmoid cells. Rhinology, 1981; 19(4): 195-202.
3. Stammberger H. Endoscopic anatomy of lateral wall and ethmoidal sinuses. In: Stammberger H, Hawke M, editors. Essentials of functional endoscopic sinus surgery. St. Louis: Mosby-Year Book; 1993. Pp. 13-42.
4. Ohnishi T, Tachibana T, Kanekoy, et al. High risk areas in endoscopic sinus surgery and prevention of complications. Laryngoscope. 1993; 103: 1181-5.
5. Ohnishi T, Yanagisawa E (1995). Lateral lamella of the cribriform plate- an important high risk area in endoscopic sinus surgery. Ear Nose Throat J 74: 688-690.
6. Grevers G. Anterior skull base trauma during endoscopic sinus surgery for nasal polyposis preferred sites for iatrogenic injuries. Rhinology. 2001; 39: 1-4.
7. Stammberger HR, Kennedy DW, Paranasal sinuses, anatomic terminology and nomenclature. The Anatomic Terminology group: Ann Otol Rhinol Laryngol Suppl. 1995; 167: 7-16.

## AUTHORS:

1. Feroz Hussain
2. Mir Alam Siddique

## PARTICULARS OF CONTRIBUTORS:

1. Demonstrator, Department of Anatomy, Fakhruddin Ali Ahmed Medical College & Hospital, Barpeta.
2. Assistant Professor, Department of Ophthalmology, Guwahati Medical College, Guwahati.

## NAME ADDRESS EMAIL ID OF THE CORRESPONDING AUTHOR:

Dr. Feroz Hussain,  
Sarumotoria, Dr. Zakir Hussain Path,  
Bye-Lane 10, House/No. 928, P.O.,  
Hengarabari, Guwahati-781036, Assam.  
E-mail: drferoz\_786@rediffmail.com

Date of Submission: 05/04/2015.  
Date of Peer Review: 06/04/2015.  
Date of Acceptance: 08/04/2015.  
Date of Publishing: 27/04/2015.