

JEJUNAL ADENOCARCINOMA: A RARE CASE REPORT

Ruthrendra Ethirajulu¹, Chidambaram Joth², Peter Manoharan Chellappa³, Santhosh Kumar⁴, Yesudas⁵

¹Postgraduate, Department of General Surgery, Pondicherry Institute of Medical Sciences, Puducherry.

²Associate Professor, Department of General Surgery, Pondicherry Institute of Medical Sciences, Puducherry.

³Professor, Department of General Surgery, Pondicherry Institute of Medical Sciences, Puducherry.

⁴Postgraduate resident, Department of General Surgery, Pondicherry Institute of Medical Sciences, Puducherry.

⁵House Surgeon, Department of General Surgery, Pondicherry Institute of Medical Sciences, Puducherry.

ABSTRACT

BACKGROUND: Small bowel tumours occur rarely with an average annual incidence rate of 9.9 per million people.⁽¹⁾ Jejunum accounts for only 20-30% of all small bowel cancers. Jejunum cancer is rare accounting for only 3% of all gastrointestinal cancers.⁽¹⁾ We report this case of Jejunal adenocarcinoma for the rarity. We discuss the diagnosis and management of this case briefly.

KEYWORDS

Jejunal Adenocarcinoma, Clinical features.

HOW TO CITE THIS ARTICLE: Ruthrendra E, Chidambaram J, Manoharan P, et al. Jejunal adenocarcinoma: A rare case report. J. Evid. Based Med. Healthc. 2016; 3(75), 4094-4098. DOI: 10.18410/jebmh/2016/875

INTRODUCTION: Malignant tumours of the small intestine are among the rarest type of gastrointestinal cancer. Nonspecific presentation and infrequent occurrence often lead to a delay in diagnosis and consequent poor prognosis. The delay of diagnosis is responsible for the presentation of these patients at advanced tumour stages.^(1,2)

Prognostic Factors: Age, Tumour size, Histological grade, Depth of invasion, Nodal involvement.

Risk Factors: The risk factors for small bowel cancer include dietary factors, cigarette smoking, alcohol intake, animal fat, red meat intake and other medical conditions including pre-existing Crohn's disease treated with 6-mercaptopurine, familial adenomatous polyposis, post cholecystectomy status, peptic ulcer disease and cystic fibrosis.⁽³⁾

CASE REPORT: A 60 year female presented with lower abdominal pain and vomiting for 10 days duration. H/o loss of appetite and loss of weight for 6 months. H/o recurrent episodes of fullness of abdomen/dyspepsia and ball rolling movement present.

Past/family/personal history was not significant.

General Examination:

- Patient was poorly-built and nourished.
- PR: 72 beats/min., BP: 110/70 mm of Hg.
- Pallor present and no clubbing, cyanosis, icterus, lymphadenopathy or oedema.

*Financial or Other, Competing Interest: None.
Submission 20-08-2016, Peer Review 30-08-2016,
Acceptance 06-09-2016, Published 19-09-2016.*

Corresponding Author:

*Dr. E. Ruthrendhra,
#18, 10th Cross St., Indranagar, Adyar,
Chennai – 600020.*

*E-mail: forya0245@gmail.com
DOI: 10.18410/jebmh/2016/875*

**Systemic Examination:**

- **Per-Abdomen:** She had tenderness over the lower abdomen and umbilicus on deep palpation. No guarding, rigidity or rebound tenderness. No visible gastric peristalsis.
- **Per Rectal Examination:** Showed a normal sphincter tone with collapsed rectum wall and faecal stain was present.
- **On Investigation:**
 - Patient had anaemia,
 - Hb: 10.4 gm/dL. WBC count of 5,200/cumm,
 - Platelet-2.33 lakhs/cumm,
 - Blood sugar random of 84 mg/dL, Blood urea 21 mg/dL,
 - Creatinine of 0.7 mg/dL, HIV and HbsAg was negative.
 - LFTs were within normal limits. Electrolytes were normal. USG abdomen and pelvis showed fatty liver. Rest of USG abdomen was normal.

CECT Abdomen: Showed jejunum wall thickening with a lesion present about 8-10 cms. away from the DJ flexure.

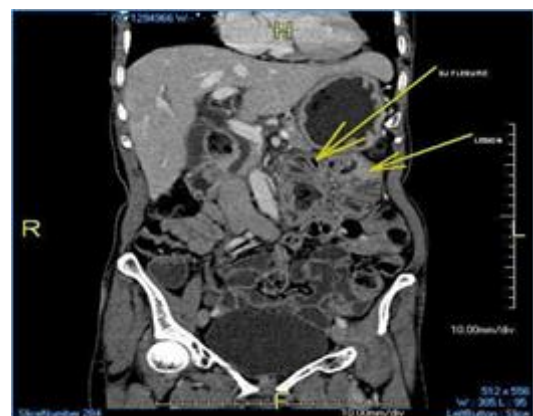

Figure 1

CECT: Jejunal wall thickening.

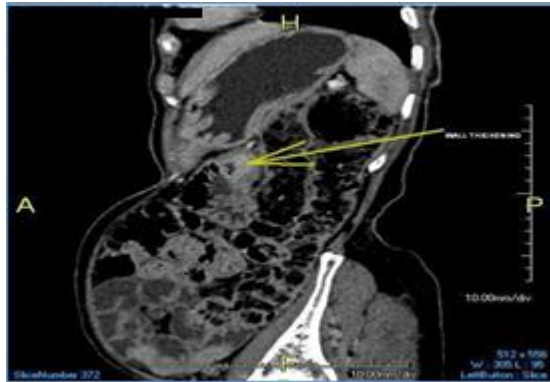


Figure 2

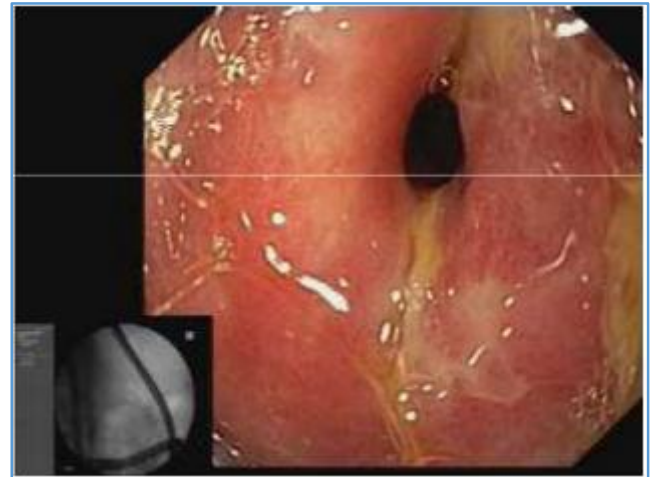

Figure 3

Push Enteroscopy: Showed a friable concentric growth with ulceration about 8-10 cms. away from DJ flexure in the jejunum and biopsy was taken.

Patient Name:	Ref By:
Patient ID:	Date:
Age/Sex:	Procedure:

PUSH ENTEROSCOPY REPORT

Instrument : OLYMPUS GIF- H 180 & SIF Q180
Sedation : By Anaesthetist
Indication : Proximal jejunal thickening

Esophagus : Normal mucosa
 No varices
 No hiatus hernia

Stomach :

Fundus : Normal
Body : Normal
Antrum : Normal

Pylorus : Normal

Duodenum:

I Part : Normal mucosa - some food debris seen
II Part : Normal
III & IV Parts : Normal

Jejunum: Mucosa of the proximal 4 to 5 cms appeared normal. Some tablets and food debris were seen in the lumen. Beyond this there was a friable concentric growth with some ulceration and marked luminal narrowing. The enteroscope could not be advanced distally.

Impression : ?Jejunal Adenocarcinoma

Biopsies taken

Debris in Proximal jejunum

Growth

Stenotic growth

Fluoroscopy

Information Management of Endo Clinic By: www.jebmh.com

Figure 4

HPE of Push Enteroscopy Biopsy Specimen:

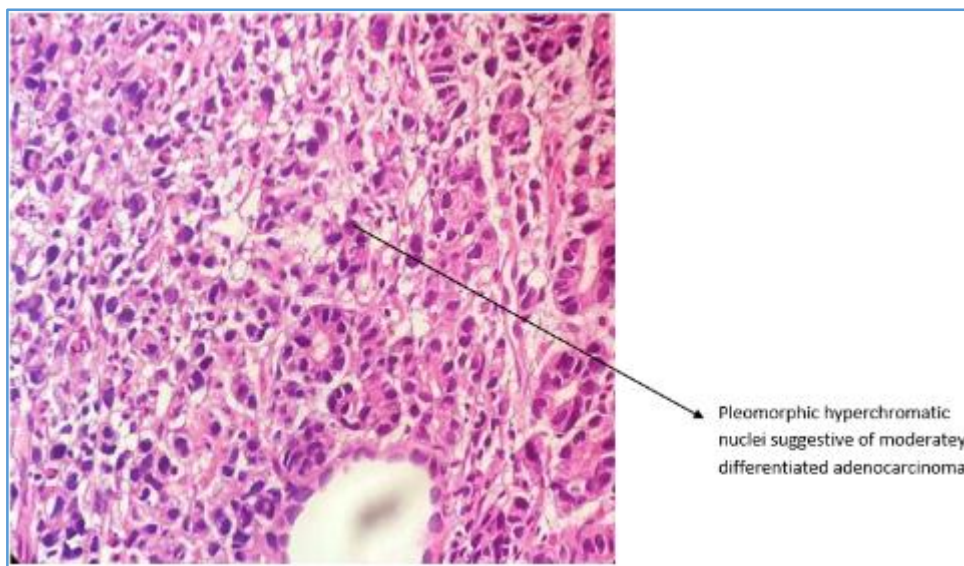


Figure 5

- Patient was taken up for resection anastomosis of jejunum and specimen sent for HPE.
- Gastrostomy was done with Ryle’s tube passing distal to the anastomosis site through the gastrostomy tube.
- Postoperative period was uneventful.
- Gastrografin study done on POD-9 showed no evidence of anastomosis leak.
- Gastrostomy tube removal was done on POD-9.
- Suture removal done on POD-14.

HPE of Resected Part of Jejunum: Moderately-differentiated adenocarcinoma extending up to subserosal tissue with surgical ends free from tumour.

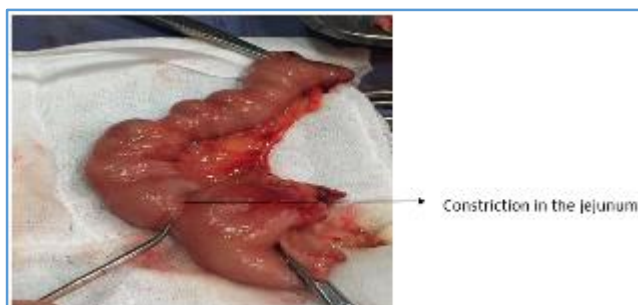


Figure 6

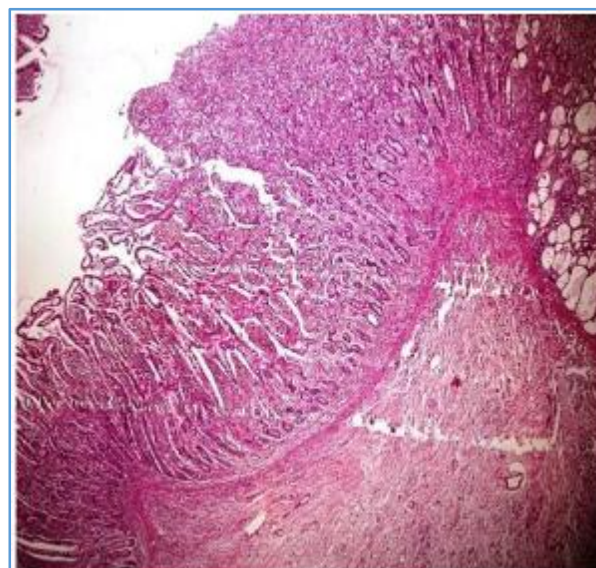


Figure 8

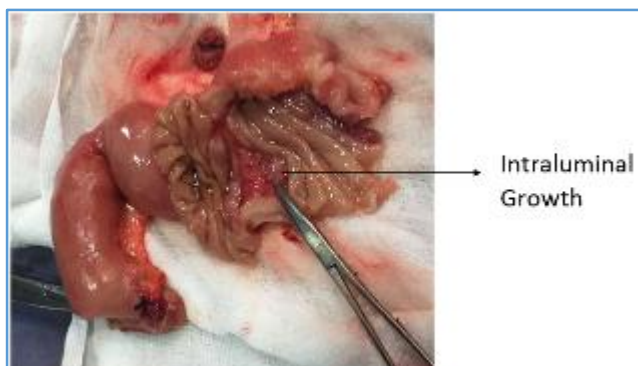


Figure 7

Postoperative:

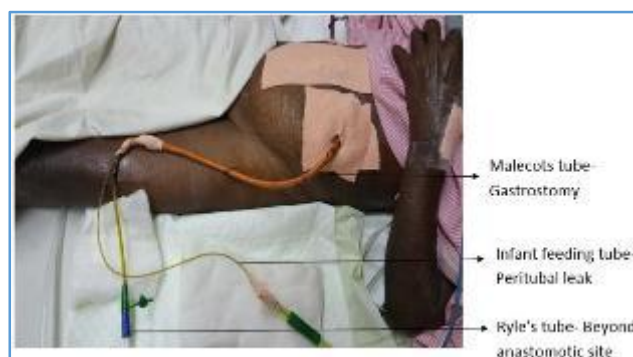


Figure 9

Gastrografin Study- No Evidence of Leak from Anastomotic Site on POD-9.

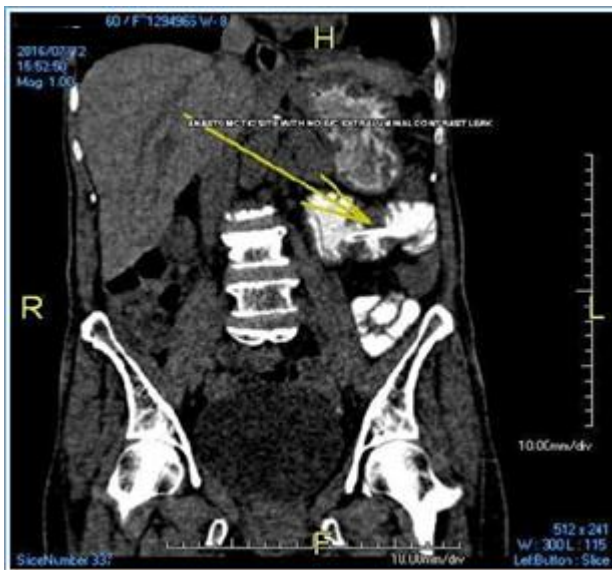


Figure 10

DISCUSSION: Small bowel carcinoma is rare when compared with gastric and colorectal cancer. Small bowel carcinoma is rare compared with gastric and colorectal cancer. Although, the small bowel comprises 75% of the GI tract length and 90% of mucosal surface area less than 2% of GI malignancies arise from the small intestine.⁽⁴⁾

Many theories have been postulated regarding the low incidence of small bowel carcinomas. They apparently have an neoplastic resistance by the large amount of alkaline fluid secretion and highly concentrated enzymes like benzopyrene, hydroxylase and high immunoglobulin level A, which dilutes and detoxifies the potential carcinogens and also preventing the prolonged exposure of carcinogens to the mucosa.⁽²⁾

Small bowel also has a very limited number of bacteria as compared to the colon that are capable of transforming potential procarcinogens into their active breakdown products.

As the small bowel carcinoma is rare, not much of information is available regarding the molecular aspects of these tumours, which could be of help in the planning, prevention, diagnosis and management of these tumours.⁽²⁾ Males have a higher inclination for these malignancies. Increasing age is associated with higher incidence of small intestinal cancers. Adenocarcinoma accounts for 40% of small bowel malignancies, others include carcinoids, lymphomas, GI stromal tumours as well as metastasis from melanoma, breast and lung cancers. The frequency of small bowel tumour is higher in the duodenum (38-55.2%) and decreases distally with 17.6-33.3% cases localised in jejunum and 13-23.8% in the ileum.⁽⁵⁾

The reasons for diagnostic delay include the nonspecific presentation and also lack of awareness of the diagnosis and the unapproachable of small bowel to investigation. Laboratory tests may show mild anaemia due to chronic blood loss.⁽⁵⁾

The diagnosis of small bowel carcinoma maybe mysterious. Upper GI series with small bowel follow through shows abnormalities in 53-83% of patients with small bowel cancers. Abdominal CT scan will reveal exact site and extent of local disease as well as the presence of liver metastasis. Upper GI endoscopy with small bowel enteroscopy may allow identification and biopsy of lesions in duodenum and jejunum. CT is frequently used to assess the abdominal cavity. The accuracy of abdominal CT in detecting primary small bowel tumours is poor-reported as 57% in one study of 85 patients.⁽⁶⁾ Bettim et al found that the FOLFOX-4 regimen (which is a combination of infusional 5-FU, oxaliplatin and leucovorin) could be safely administered as adjuvant chemotherapy in three subjects with resected small bowel adenocarcinoma associated with celiac disease.⁽⁷⁾

Veyrieres et al reported an overall 5-year survival of 38%; while it was 54% after curative resection. 56% when the tumour was well or moderately well-differentiated and 40% when it was undifferentiated. Other factors influencing long-term survival were the emergency presentation, the site, the multiplicity and the size of the tumour.⁽⁸⁾ Radiotherapy does not seem to be effective or benefit survival. It is technically difficult to localise the target field due to the mobile nature of the small intestine mesentery.⁽⁵⁾

CONCLUSION: Our case intends to highlight the fact that small bowel tumours are always a diagnostic challenge and frequently present with nonspecific clinical symptoms. Diagnosis requires high index of suspicion in patients who have high-risk factors. Small bowel malignancy should be considered when more common causes have been excluded, especially if there are general features suggestive of malignancy such as anorexia, abdominal pain and vomiting or weight loss along with features of small bowel obstruction (subacute).

REFERENCES

1. Chow JS, Chen CC, Ahsan H, et al. A population-based study of the incidence of malignant small bowel tumours: SEER, 1973-1990. *International Journal of Epidemiology* 1996;25(4):722-728.
2. Shah PP, Kothari S. Jejunal adenocarcinoma-a case report with review. *Indian J Surg* 2013;75(Suppl 1):82-85.
3. Aparicio T, Zaanani A, Svrcek M, et al. Small bowel adenocarcinoma: epidemiology, risk factors, diagnosis and treatment. *Dig Liv Dis* 2014;46(2):97-104.
4. Neugut AI, Marvin MR, Rella VA, et al. An overview of adenocarcinoma of the small intestine. *Oncology* 1997;11(4):529-536.
5. Figueira-Coelho J, Lourenço S, Costa M, et al. Blood loss anemia due to adenocarcinoma of the jejunum: case report and review of the literature. *Cases J* 2009;2:6237.

6. Costamagna G, Shah SK, Riccioni ME, et al. A prospective trial comparing small bowel radiographs and video capsule endoscopy for suspected small bowel disease. *Gastroenterology* 2002;123(4):999-1005.
7. Bettini AC, Beretta GD, Sironi P, et al. Chemotherapy in small bowel adenocarcinoma associated with celiac disease: report of three cases. *Tumori* 2003;89(2):193-195.
8. Veyrières M, Baillet P, Hay JM, et al. Factors influencing long term survival in low cases of small intestine primary adenocarcinoma. *Am J Surg* 1997;173(3):237-239.