

INTRAVITREAL DEXAMETHASONE IMPLANT FOR MANAGEMENT OF SYMPATHETIC OPHTHALMIA – CASE REPORT

Nishikant Jaywant Borse¹, Vinay Prasad², Veena Nishikant Borse³

¹Director, Vitreoretinal Services, Insight Eye Clinic, Mumbai.

²Consultant, Vitreoretinal Services, Insight Eye Clinic, Mumbai.

³Director, Vitreoretinal Services, Insight Eye Clinic, Mumbai.

HOW TO CITE THIS ARTICLE: Borse NJ, Prasad V, Borse VN. Intravitreal dexamethasone implant for management of sympathetic ophthalmia – case report. J. Evid. Based Med. Healthc. 2018; 5(22), 1728-1730. DOI: 10.18410/jebmh/2018/362

PRESENTATION OF THE CASE

A 50-year-old male presented to us with the chief complaints of progressive diminution of vision in the left eye since the past one year. He had a past history of open globe injury to his right eye in 2007 while working. No specific systemic illness was reported by him nor any significant drug history or allergy to any drug.

CLINICAL DIAGNOSIS

Visual Acuity on presentation was finger counting @ 2 meters in the left eye, and no perception of light in the right eye. Intraocular pressure was 16 mm Hg measured by Perkins Tonometer. On slit lamp examination the right eye was phthisical. (Legend 1) Left eye examination showed, keratic precipitates on the endothelium, deep anterior chamber with cells 2+, and pigment dispersion on anterior surface of the lens, with cortical cataract. Posterior segment examination with indirect ophthalmoscope and 20 D lens showed dense vitritis, choroiditis and optic neuritis (Legend 2). Dalen Fuch's nodules were seen on temporal aspect of the macular area. (Legend 3).

Since there was a history of open globe injury in the right eye for which appropriate treatment was not taken, and posterior uveitis with Dalen Fuchs nodules were seen, a clinical diagnosis of sympathetic uveitis was made. The patient was started on oral prednisolone 1 mg/kg body weight and topical difluprednate 4-times a day and topical homatropine eye drops were started. Patient was reviewed after 4 days and visual acuity had improved to 6/120 in left eye, with reduced vitritis and optic neuritis.

He was continued on oral prednisolone in tapering doses over 4 weeks and was continued on topical difluprednate and homatropine eye drops. On follow up after 3 weeks his visual acuity was finger counting at 7ft, with the posterior segment examination showing healed choroiditis.

To further improve his visual acuity, he was given intravitreal Ozurdex implant after 5 weeks of starting treatment. On further follow ups over the next month patient had gradual improvement in visual acuity to 6/36, with

Financial or Other, Competing Interest: None.

Submission 28-03-2018, Peer Review 31-03-2018,

Acceptance 18-04-2018, Published 28-05-2018.

Corresponding Author:

Dr. Nishikant Jaywant Borse,

Director,

Vitreoretinal Services,

Insight Eye Clinic, Mumbai.

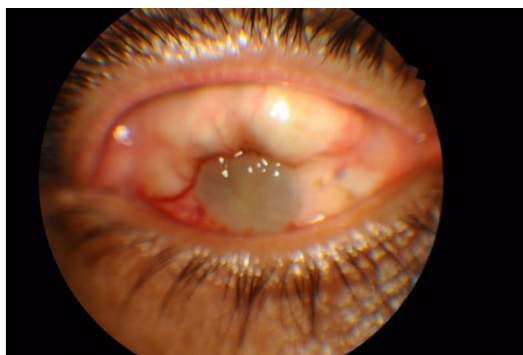
E-mail: nishikantborse@yahoo.com

DOI: 10.18410/jebmh/2018/362

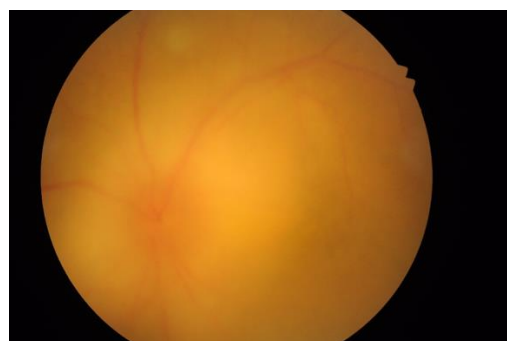

normal IOP. After 1 month of Ozurdex Implant, patient underwent cataract surgery since signs of posterior uveitis had quietened.

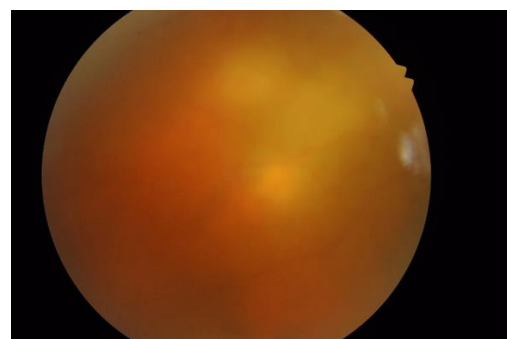
On the latest follow up, 1 month after cataract surgery, his best corrected visual acuity was 6/18, and intraocular pressure was 20 mm Hg. Posterior segment examination showed resolved posterior uveitis and optic neuritis (Legend 4).



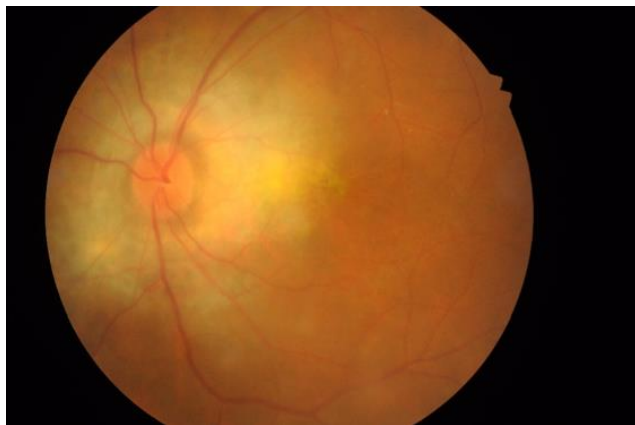Legend 1. The Phthisical Right Eye of the Patient



Legend 2. Fundus Photograph Showing Dense Vitritis, Choroiditis and Optic Neuritis



Legend 3. Dalen Fuch's Nodules seen on Temporal Aspect of the Macular Area



**Legend 4. Resolved Vitritis,
Optic Neuritis & Posterior Uveitis**

DIFFERENTIAL DIAGNOSIS

The differential diagnosis of sympathetic ophthalmia (SO) includes almost all diseases that can present as granulomatous panuveitis.

However the patient history will reveal previous penetrating ocular injury or intraocular surgery. Occasionally, it may be difficult to distinguish sympathetic ophthalmia from Vogt Kayanaki Harada (VKH) disease. However, patients with VKH have no history of surgery or trauma and VKH presents as bilateral granulomatous panuveitis with prominent choroidal involvement. Typically, patients with VKH have serous retinal detachment and optic nerve involvement, not seen in SO.

Also, VKH is associated neurological symptoms, like headache & tinnitus & also dermal symptoms like vitiligo & poliosis.

Lymphoma, syphilis, tuberculosis, and sarcoidosis have to be ruled out as these diseases demonstrate multiple small foci of choroiditis with vitreal cells. If lymphoma is suspected, careful systemic workup, including neurological evaluation, should be performed. If necessary, a vitreous sample must be obtained for diagnostic purposes. Tuberculosis, sarcoidosis, and syphilis are usually accompanied by constitutional signs and symptoms of the underlying systemic disease.

DISCUSSION OF MANAGEMENT

Sympathetic Ophthalmia is a bilateral, diffuse granulomatous panuveitis that occurs following penetrating trauma or surgery in one or both eyes.¹ The condition was first recognized by Hippocrates, but was first described and named by Mackenzie in the mid-1800s. William Mackenzie provided the first full clinical description of the disease, coining the term 'sympathetic ophthalmitis' in 1840.² Onset occurs within 1 month in approximately 17% of cases; within 3 months in 50%; within 6 months in 65%, and within the first year after injury in 90%. After the inciting event, traumatic or surgical, bilateral intraocular inflammation has been reported between 1 week and 66 years.³ The ocular complications most often associated with decreased vision were cataract and optic nerve abnormality. Exudative retinal detachment and active intraocular inflammation were

significantly associated with poorer VA in the sympathizing eye. The presence of an exudative retinal detachment and active intraocular inflammation correlated with poorer vision in the sympathizing eye.⁴ The sequelae of inflammation noted in sympathetic ophthalmia (SO) are quite variable, depending on the severity of the ocular inflammation and whether therapy has been initiated. Secondary glaucoma as well as cataract can be present. In addition, retinal and optic atrophy may occur in association with retinal detachment, subretinal fibrosis, and underlying choroidal atrophy.⁵ Mahajan et al, proposed that fluocinolone acetonide implant provides inflammatory control and reduces the dependence on systemic immunosuppression in patients with SO.⁶ The treatment of SO is primarily medical. The mainstay of treatment is systemic immunomodulatory therapy. Systemic corticosteroids are the first-line therapy for SO. They may be given topically, by sub-tenon or transseptal injection, and systemically. Oral prednisone is most frequently employed in the treatment of SO. Treatment is initiated with high dosage oral prednisone (1.0 to 2.0 mg/kg/day) and tapered slowly over 3 to 4 months. In severe cases, intravenous pulse steroid therapy can be employed (methylprednisolone 1.0 g/day for 3 days).⁷ Corticosteroids have served as the mainstay of treatment following onset.⁸ While systemic anti-inflammatory therapy has been the mainstay of sympathetic ophthalmia treatment for some time, the long-term use of corticosteroids has been called into question. Corticosteroid treatment is associated with cataracts and glaucoma, and systemic adverse effects such as diabetes mellitus, adrenal insufficiency, arterial hypertension, and osteoporosis must be considered carefully.⁹

In our report, the patient on presentation had an active posterior uveitis with papillitis and macular involvement also. It is the first time that Ozurdex implant was given in a case of Sympathetic ophthalmitis. The initial treatment was delayed in this patient since the patient presented almost 1 year later after the symptoms started. Treatment was started in the form of oral steroids which helped in the initial immunosuppression and anti-inflammatory action, and later sustained release dexamethasone implant was done to control inflammation for long term and further improvement in visual acuity. The result showed the importance of a sustained release steroid implant in successfully treating Sympathetic ophthalmia, since oral steroids cannot be continued to have the desired effects without side effects. Though it has been reported by Galor A1, Davis JL, Flynn HW Jr et al,³ that active intraocular inflammation has poor results in terms of visual acuity gain, in our case report, Ozurdex was potent in dealing with the choroiditis, retinal vasculitis and also papillitis, which was present in this patient for over a year.

Dependence of the patient on oral steroids and other immunosuppressive agents can be reduced with the use of Ozurdex.

FINAL DIAGNOSIS

This case report shows that Ozurdex can be used successfully in treating challenging long standing

sympathetic ophthalmia with papillitis, choroiditis and retinal vasculitis.

REFERENCES

- [1] Marak GE. Recent advances in sympathetic ophthalmia. *Surv Ophthalmol* 1979;24(3):141-156.
- [2] Mackenzie W. A practical treatise on the diseases of the eye. 3rd edn. London: Longmans 1840:523-534.
- [3] Zaharia MA, Lamarche J, Laurin M. Sympathetic uveitis 66 years after injury. *Can J Ophthalmol* 1984;19(5):240-243.
- [4] Galor A, Davis JL, Flynn HW, et al. Sympathetic ophthalmia: incidence of ocular complications and vision loss in the sympathizing eye. *Am J Ophthalmol* 2009;148(5):704-710.
- [5] Lim WK, Chee SP, Sng I, et al. Immunopathology of progressive subretinal fibrosis: Variant of sympathetic ophthalmia. *Am J Ophthalmol* 2004;138(3):475-477.
- [6] Mahajan VB, Gehrs KM, Goldstein DA, et al. Management of sympathetic ophthalmia with the fluocinolone acetonide implant. *Ophthalmology* 2009;116(3):552-557.
- [7] Arevalo JF, Garcia RA, Al-Dhibi HA, et al. Update on sympathetic ophthalmia. *Middle East Afr J Ophthalmol* 2012;19(1):13-21.
- [8] Chan CC, Roberge RG, Whitcup SM, et al. 32 cases of sympathetic ophthalmia. A retrospective study at the National Eye Institute, Bethesda, Md., from 1982 to 1992. *Arch Ophthalmol* 1995;113(5):597-600.
- [9] Jonas JB, Spandau UH. Repeated intravitreal triamcinolone acetonide for chronic sympathetic ophthalmia. *Acta Ophthalmol Scand* 2006;84(3):436.