

# Intrastromal Injection of Voriconazole in the Treatment of Deep Fungal Keratitis - A Prospective Study in a Tertiary Care Centre in South India

Bindu Madhavi R.<sup>1</sup>, Manjula Y.M.<sup>2</sup>, Suma C.<sup>3</sup>, Soumya Basanth<sup>4</sup>, Nibedita Acharya<sup>5</sup>

<sup>1, 2, 3, 4, 5</sup> Department of Ophthalmology, BGS Global Institute of Medical Sciences, Bangalore, Karnataka, India.

## ABSTRACT

### BACKGROUND

Treatment of fungal ulcers is one of the most challenging tasks. Various topical antifungal drugs have poor corneal stromal penetration. Voriconazole is a broad spectrum drug and is an effective agent for the treatment of fungal keratitis as a topical preparation. It is potent against a broad range of clinically significant fungal infections both in the eye as well systemically. In tropical climatic conditions filamentous fungi commonly cause eye infections and are associated with poor visual outcomes. The treatment options for mycotic ulcers are limited, therefore direct intrastromal injections are helpful in the management of these deep mycotic keratitis. We wanted to evaluate the role of intrastromal injection of voriconazole in the management of deep fungal keratitis not responding to conventional therapy.

### METHODS

This an interventional case series study done at a tertiary care centre in south India from the year April 2019 to August 2020. Eight eyes of eight patients with microbiologically proven deep stromal recalcitrant mycotic keratitis not responding to topical antifungal medications were evaluated. Voriconazole 50 microgram / 0.1 ml was injected around the infiltrate in the corneal stroma as an adjunctive to the topical antifungal treatment. Main outcome measure was a reduction of the size of the infiltrate and ulcer and decrease in infection on regular follow ups.

### RESULTS

Before injecting voriconazole, all the cases were of either gradually worsening of lesions on topical treatment, or not responding to topical treatment. After the injection a rapid decrease in the size of corneal ulcer, hypopyon, and infiltration was seen within 3 weeks.

### CONCLUSIONS

Targeted delivery of intrastromal voriconazole may be a safe and effective way in the management of deep seated fungal ulcers which respond poorly to conventional treatment procedures, thus reducing the need for further surgical treatment.

### KEYWORDS

Intrastromal Injection, Voriconazole, Fungal Keratitis, Deep Mycotic Keratitis

*Corresponding Author:*

*Dr. Bindu Madhavi R.,  
#002, Sowmya Springs Apartments,  
Diwan Madhav Roa Road,  
Basvangudi, Bangalore - 560004,  
Karnataka, India.*

*E-mail: madhavibindu50@gmail.com*

*DOI: 10.18410/jebmh/2021/285*

*How to Cite This Article:*

*Madhavi RB, Manjula YM, Suma C, et al.  
Intrastromal injection of voriconazole in  
the treatment of deep fungal keratitis - a  
prospective study in a tertiary care centre  
in South India. J Evid Based Med Healthc  
2021;8(20):1505-1509. DOI:  
10.18410/jebmh/2021/285*

*Submission 08-01-2021,*

*Peer Review 16-01-2021,*

*Acceptance 30-03-2021,*

*Published 17-05-2021.*

*Copyright © 2021 Bindu Madhavi R. et al. This is an open access article distributed under Creative Commons Attribution License [Attribution 4.0 International (CC BY 4.0)]*

**BACKGROUND**

Fungal keratitis is one of the leading causes of blindness in the world.<sup>1</sup> Fungal infections are responsible for majority of corneal ulcers of the eye in developing countries. The incidence of fungal keratitis is higher in developing countries. Fungal eye infections are common in tropical climates and have been difficult to diagnose and treat. The most common fungi that causes keratitis includes fusarium and aspergillus. Risk factors for fungal keratitis are trauma with organic matter, long term use of topical steroids, ocular surface disorders, contact lens use and refractive surgeries. Most incidences of fusarium keratitis are caused by an eye injury with vegetative matter but infections through contact lens wear are less prevalent. Currently antifungal drugs are divided into four groups mainly: polyenes, imidazoles, triazoles and fluorinated pyrimidines. Voriconazole is an extended spectrum of triazole which specifically acts against filamentous fungi.

Voriconazole is effective in treating both yeast and filamentous fungi. Mechanism of action of triazoles include the alteration of synthesis of ergosterol in the cell membrane. These are mainly metabolized in the liver; therefore liver function testing is recommended. It is contraindicated in pregnancy. The In-vitro minimum inhibitory concentration of voriconazole is highest against fusarium and least against candida. Its advantages compared to polyenes include its greater stability to light and temperature, remaining effective for up to 30 days. The different clinical presentation of Fungal keratitis includes epithelial defect with infiltrate, endothelial plaque, stromal abscess, endophthalmitis, panophthalmitis secondary to keratitis. Voriconazole has been found to be efficacious in treating all these conditions with different routes. Fungal keratitis is usually difficult to treat. The treatment of fungal keratitis is difficult due to several limitations of topical drugs like poor penetration and limited spectrum.<sup>2</sup> Use of Amphotericin-B for deep stromal fungal keratitis not responding to conservative treatment have been described. Intrastromal Amphotericin-B has been used to treat refractory fungal keratitis before. But several complications have been observed with Amphotericin-B like surface toxicity, retinal toxicity and others. Traditionally surgical treatment like therapeutic keratoplasty is usually required for deep seated mycotic ulcers that are not resolving with topical drugs.

However therapeutic keratoplasty has its own limitations like graft rejection, reinfections, deficiency of donor corneas in developing countries.<sup>3</sup> Voriconazole has been reported to be effective in the treatment of fungal keratitis. It has been effective in the treatment of ulcers caused by candida, aspergillus, scedosporium, fusarium and paecilomyces. It is a very safe drug for ocular use and well tolerated. Targeted drug delivery in the form of intrastromal injection of voriconazole has been described in few studies and this can achieve adequate drug concentration at required sites.<sup>4,5,6</sup> In a prospective clinical study, Hariprasad et al. demonstrated that systemic voriconazole achieved good penetration into the aqueous and vitreous humour of the eye. Even though it has good intraocular penetration, systemic voriconazole

may result in side effects.<sup>7</sup> And hence targeted drug delivery of voriconazole in the form of intrastromal injection is required.

Here in this study, we have evaluated the role of intrastromal voriconazole in refractory deep mycotic corneal ulcers not resolved with conventional treatment.

**METHODS**

In this prospective interventional study which was conducted at a tertiary centre in south India from April 2019 to August 2020, 8 cases of fungal corneal ulcers involving deep corneal stroma that were unresponsive to topical antifungal treatment were given intrastromal injection of voriconazole 50 microgram / 0.1 ml. Informed consent was obtained from the participants in the study for medical management. All patients underwent a detailed clinical evaluation which included elaborate history, slit lamp biomicroscopy, Snellen's visual acuity. Corneal scrapings were taken under topical anaesthesia and were sent for microbiological investigation which included potassium hydroxide (KOH) wet mount, gram stain, blood agar, chocolate agar, and Sabourauds dextrose agar (SDA). Topical treatment was started as soon as fungus was identified by KOH mount.

Topical treatment included 5 % of natamycin hourly, 1 % of homatropine twice daily. If no response to treatment was seen or if the signs worsened in 2 weeks, then patients were started on topical voriconazole 1 % eye drops hourly. If no response to this, combined therapy was observed after 10 days, then intrastromal injection was given around the infiltrate. All the 8 patients had no clinical evidence of perforation.

**Technique of Intrastromal Injection**

Voriconazole injection (VOZOLE PF, Aurolab, India) is available as 1 mg white powder in a glass vial. This is then mixed with 2 ml of distilled water to make it into a solution with a concentration of 0.5 mg / ml (50 microgram / 0.1 ml). The reconstituted solution was loaded into a 1 ml insulin syringe with a 30 G needle. The preloaded drug was administered under operating microscope under full aseptic precautions after peribulbar anaesthesia. With the bevel down, the needle was inserted obliquely around the infiltrate and the transparent uninvolved mid stroma. The drug was injected into the corneal stroma and the amount of whitening of cornea in the form of hydration of the cornea was used as a guide to determine the area covered. Injecting circumferentially established the formation of a barrier of intrastromal drug surrounding the entire corneal infiltrate. The total quantity of drug injected ranged from 0.05 ml to 0.1 ml. Intra procedural complications if any were noted.

Postoperatively all patients were maintained on topical antifungal treatment. Patients were examined every 2<sup>nd</sup> day and the response to the treatment was recorded which included measurement of size of infiltrate using Castroviejo caliper, slit lamp biomicroscopy and decrease in size of hypopyon.

The infection was considered as resolved when there was complete healing of epithelial defect, corneal infiltrate and scar formation. The patients were continued on topical antifungal treatment for at least 10 days after the complete healing of ulcer.

In case of worsening or of response to the previous infection, the intrastromal injection was repeated after 5 days. Patients were considered as treatment failure if the ulcer progressed despite 3 injections.

**Statistical Analysis**

All the data were entered to Microsoft excel and complied. Descriptive Statistics were calculated, as shown in Table 3.

**RESULTS**

During the study 8 patients were included, out of which 6 (75 %) were males and 2 (25 %) were females. Age of the patients ranged from 40 to 65 years, mean being 52.75 years. All patients had anterior to mid stromal involvement of cornea on slit lamp examination. On examination, the mean infiltrate size was 35.88 mm<sup>2</sup> with hypopyon present in 6 patients (75 %). The mean duration of onset of symptoms was 10 days. All the 8 cases were positive for KOH mount. The predominant pathogen isolated was fusarium in 7 (87.5 %) cases and one case (12.5 %) showed aspergillus species. The fungi species isolated are mentioned in Table 1. Out of 8 patients, 2 patients required 2 injections. The infection resolved completely in all the 8 cases after intrastromal injections. Average healing time was 28.5 days. Few examples of clinical resolution of fungal corneal ulcers are shown in Fig 1 and Fig. 2. The size and depth of infiltrate were found to be significant risk factors. We didn't notice any procedure related complications or drug related local or systemic side effects.

Number of Cases	Type of Fungus
1	Fusarium
2	Fusarium
3	Fusarium
4	Aspergillus
5	Fusarium
6	Fusarium
7	Fusarium
8	Fusarium

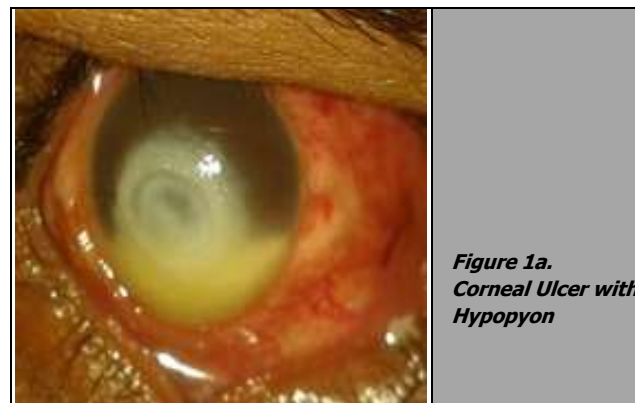
*Table 1. Fungal Species Isolated*

Number of Cases	Age (years)	History	Infiltrate Size (mm)	Mean Size (mm <sup>2</sup> )	Hypopyon	Duration of Onset of Symptoms	Number of Injections	Resolution Time (days)
1	40	Veg	6.5 * 5.4	35.1	+	15	1	25
2	52	Unclear	7.6 * 5.4	41.04	+	10	1	30
3	65	Veg	4.7 * 5.5	25.85	-	20	2	31
4	56	Veg.	6.4 * 4.1	26.24	-	12	1	27
5	47	Veg	7.7 * 6.7	51.59	+	14	2	28
6	53	Veg	6.3 * 7.2	45.36	+	10	1	26
7	60	Unclear	4.5 * 7.4	33.3	+	07	1	29
8	49	Veg	6.8 * 4.2	28.56	+	07	1	30

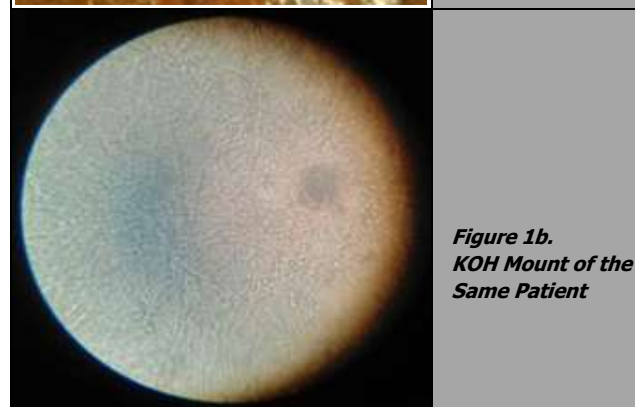*Table 2. Characteristics of the Cases with Deep Mycotic Keratitis Treated with Intrastromal Voriconazole 50 microgram/0.1 ml as an Adjunctive Treatment*

	Min	Max	Mean	SD	Median	Mode	IQR
<b>Size</b>	<b>25.85</b>	<b>51.59</b>	<b>35.88</b>	<b>9.394</b>	<b>34.2</b>	<b>25.85</b>	<b>266.82-44.28</b>
Duration of onset of symptoms (days)	7	20	11.87	4.39	11	7	7.75 - 14.75
Resolution time (days)	25	31	28.25	2.12	28.5	30	26.25 - 30.0

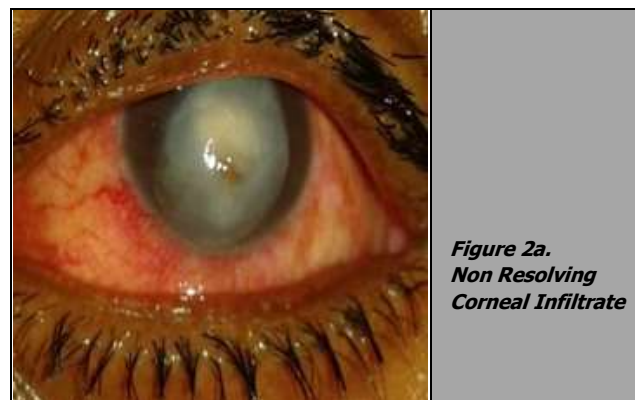
*Table 3. Descriptive Statistics*



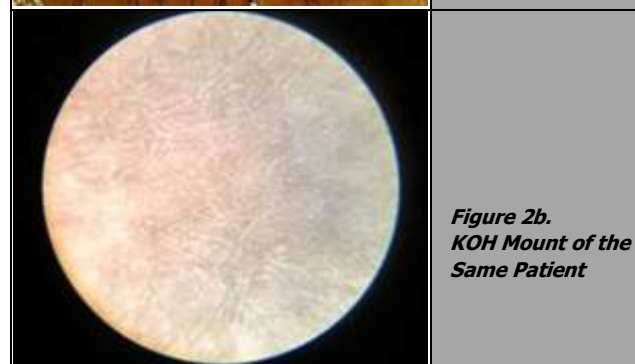
*Figure 1a. Corneal Ulcer with Hypopyon*



*Figure 1b. KOH Mount of the Same Patient*



*Figure 2a. Non Resolving Corneal Infiltrate*



*Figure 2b. KOH Mount of the Same Patient*

## DISCUSSION

Mycotic keratitis is an important cause of corneal blindness. The incidence of mycotic ulcers varies around the world and is more prevalent in areas with hot humid climatic regions. Many species of fungi exist as part of the normal ocular surface commensals. However, under certain circumstances such as steroid treatment and injury to eye ball, these fungi might invade the eyeball and cause fungal infections. *Fusarium solani* species can cause severe types of mycotic keratitis because of its high virulence and its resistance to antifungal drugs. Corneal ulcers caused by these species may lead to serious complications such as endophthalmitis, perforation and blindness. Several drugs have been used to treat filamentous mycotic ulcers. The commonly available antifungal agents are natamycin, amphotericin-B, itraconazole. Few studies found that all *Fusarium* species were sensitive to natamycin invitro but that did not convert to good clinical outcome irrespective of early or late presentation. The spectrum of common antifungal drugs available for fungal eye infections are limited and is associated with poor outcome.

However, resistance to amphotericin - B is increasing. Management of deep fungal corneal ulcers is difficult with topical antimicrobial drugs because of limited spectrum of topical antifungal agents,<sup>2</sup> poor penetration of the currently available drugs. Previous studies have shown that oral and topical antifungal agents have poor ocular penetration and hence suboptimal drug level are achieved at the site of infection. Current treatment options are far from optimal. Voriconazole, a second generation triazole derived from fluconazole, offers broad spectrum activity against various fungi affecting the eye. Invitro susceptibility data showed that voriconazole has the best efficacy against pathogenic fungi compared with other drugs.<sup>8,9</sup>

The clinician should judge the route of voriconazole administration depending on the type and presentation of fungal keratitis. Causative organisms might have an impact on the final outcome. Few studies are available about the efficacy of these drugs on fungal keratitis and the route of administration. One of the recently suggested route of administration is intrastromal injection of voriconazole. In order to achieve adequate drug concentration at the site of infection, intrastromal injections have been tried in the form of targeted drug delivery.<sup>10,11</sup> Intracameral voriconazole has been used in humans with no toxic effects when the aqueous concentration is 10 microgram / ml to 1.5 microgram / ml. Voriconazole has shown promising results in topical and systemic routes.<sup>12,13</sup> And moreover voriconazole has good safety profile.<sup>14</sup> When a fungal aetiology is known voriconazole may be considered as a first line therapy or used as an adjunct to other antifungal treatment. Recent studies indicate the intrastromal injection of antifungal drugs could better control infection by increasing drug concentration at the ulcer site. Kalaiselvi et al. reported a success rate of 72 % in Tamilnadu, India.<sup>6</sup> Sharma N et al. study reported a success rate more than 80 %.<sup>11</sup> The sensitivity of intrastromal voriconazole to different fungal species is yet to be determined.

In our study all the ulcers were deep and were not responding to topical antifungal drugs and therefore we decided to give intrastromal drug delivery of voriconazole at the site of infiltrate. The intrastromal injections of voriconazole helped in early and complete healing of the fungal ulcers with no side effects. If combined with topical therapy, intrastromal administration of voriconazole may be of immense use in such cases and avoid further complications and postpone surgical treatment. Even though intrastromal voriconazole has shown encouraging results, the dose and frequency of injections are yet to be ascertained. We did not notice any procedure related complications in our study, complications due to drug toxicity, damage to the corneal endothelium, creation of new infection and corneal perforation during injection can occur.

## CONCLUSIONS

Intrastromal injection of voriconazole might be a safe and inexpensive method of providing higher concentration of the drug especially in deep keratitis where topical antifungal drugs are unable to penetrate. But larger clinical trials and long term follow up are required to determine the dose, frequency and effects of intrastromal voriconazole.

Data sharing statement provided by the authors is available with the full text of this article at jebmh.com.

Financial or other competing interests: None.

Disclosure forms provided by the authors are available with the full text of this article at jebmh.com.

## REFERENCES

- [1] Whitcher JP, Srinivasan M, Upadhyay MP. Corneal blindness: a global perspective. *Bull World Health Organ* 2001;79(3):214-221.
- [2] Muller GG, Kara-Jose N, de Castro RS. Antifungals in eye infections: drugs and routes of administration. *Rev Bras Oftalmol* 2013;72(2):132-141.
- [3] Panda A, Vajpayee RB, Kumar TS. Critical evaluation of therapeutic penetrating keratoplasty in cases of keratomycosis. *Ann Ophthalmol* 1991;23(10):373-376.
- [4] Konar P, Joshi S, Mandhare SJ, et al. Intrastromal voriconazole: an adjuvant approach for recalcitrant mycotic keratitis. *Indian J Ophthalmol* 2020;68(1):35-38.
- [5] Prakash G, Sharma N, Goel M, et al. Evaluation of intrastromal injection of voriconazole as a therapeutic adjunctive for the management of deep recalcitrant fungal keratitis. *Am J Ophthalmol* 2008;146(1):56-59.
- [6] Kalaiselvi G, Narayana S, Krishnan T, et al. Intrastromal voriconazole for deep recalcitrant fungal keratitis: a case series. *Br J Ophthalmol* 2015;99(2):195-198.
- [7] Hariprasad SM, Mieler WF, Holz ER, et al. Determination of vitreous, aqueous and plasma concentration of orally administered voriconazole in humans. *Arch Ophthalmol* 2004;122(1):42-47.

- [8] Marangon FB, Miller D, Giaconi JA, et al. In vitro investigation of voriconazole susceptibility for keratitis and endophthalmitis fungal pathogens. *Am J Ophthalmol* 2004;137(5):820-825.
- [9] Sabo JA, Abdel-Rahman SM. Voriconazole: a new triazole antifungal. *Ann Pharmacother* 2000;34(9):1032-1043.
- [10] Tu EY. *Alternaria* keratitis: clinical presentation and resolution with topical fluconazole or intrastromal voriconazole and topical caspofungin. *Cornea* 2009;28(1):116-119.
- [11] Sharma N, Agarwal P, Sinha R, et al. Evaluation of intrastromal voriconazole injection in recalcitrant deep fungal keratitis: case series. *Br J Ophthalmol* 2011;95(12):1735-1737.
- [12] Freda R. Use of oral voriconazole as adjunctive treatment of severe corneal fungal infection: case report. *Arq Bras Oftalmol* 2006;69(3):431-434.
- [13] Pollizzi A, Siniscalchi C, Mastromarino A, et al. Effect of voriconazole on a corneal abscess caused by *fusarium*. *Acta ophthalmol Scand* 2004;82(6):762-764.
- [14] Pfaller MA, Messer SA, Hollis RJ, et al. In vitro activities of ravuconazole and voriconazole compared with those of four approved systemic antifungal agents against 6970 clinical isolates of candida species. *Antimicrob Agents Chemother* 2002;46(6):1723-1727.