

ORIGINAL ARTICLE

INCIDENCE OF SHORTENING IN PATIENTS WITH DISTAL RADIAL FRACTURES TREATED WITH EXTERNAL FIXATOR

Sanjoy Chakravarty¹, Manjuri Katakai², Ujjawal Pradhan³

HOW TO CITE THIS ARTICLE:

Sanjoy Chakravarty, Manjuri Katakai, Ujjawal Pradhan. "Incidence of Shortening in Patients With Distal Radial Fractures Treated With External Fixator". Journal of Evidence based Medicine and Healthcare; Volume 2, Issue 41, October 12, 2015; Page: 6961-6966, DOI: 10.18410/jebmh/2015/950

ABSTRACT: Distal Radial fractures are a very common fracture especially in patients above 40 years of age. Most fractures result in shortening of more than 4 to 5 mm of the radius. The study was done on records of 32 patients attending a tertiary and teaching hospital in Sikkim. The study is a retrospective one. This study was taken up to study the shortening that results in cases where external fixator was used as a mode of treatment combined with ligamentotaxis. A bridging external fixator was used in all cases. The results were recorded in the immediate postoperative x-ray film. Results were also recorded in follow up x-rays taken after 6 weeks of removal of external fixator.

KEYWORDS: Distal Radius Fracture, External Fixator, Ligamentotaxis, Shortening.

INTRODUCTION: Distal radial fractures are very common fractures especially in patients above the 40 years.⁽¹⁾ Different modes of treatment are used in the treatment of such fractures like Pop cast after manipulation of fracture, internal fixation with T-plate and screw, pin fixation augmented with plaster, external fixator with ligamentotaxis.⁽²⁾ Shortening is a complication which is observed in most cases after treatment.⁽³⁾ In our study we have tried to see the amount of shortening which arises in patients treated with a Bridging external fixator with ligamentotaxis.⁽⁴⁾

MATERIAL AND METHOD: 32 patients were studied retrospectively. All had fractures of the distal radius and was treated with bridging external fixator with ligamentotaxis.⁽⁵⁾ The study was taken up between the months of April 2014 to April 2015. The initial postoperative radiographs were studied and the shortening recorded if any. Shortening was compared with radiograph from the normal wrist of the same patient. External fixators were removed after 4 weeks or 6 weeks according to the union seen in x-rays. The x-rays were taken after 6 weeks after removal of external fixator and the shortening recorded. The result of the immediate postoperative and the later x-rays taken at 10 to 12 weeks after operation and 6 weeks after removal of external fixator were compared.⁽⁶⁾ The results of different age groups were compared. The results in patients with associated osteoporosis and of associated comminution were also studied.

INCLUSION CRITERIA: All patients with fractures of the lower end of the radius within one inch from the distal radio ulnar joint were taken up. Patient with intraarticular comminution were also included. All patients included in the study were above 30 years of age.

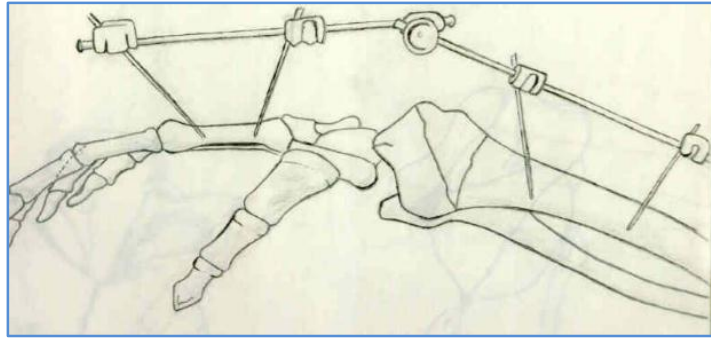


Fig. 1: Diagram representing the mode of external fixator used in fixation of distal radial fractures

RADIOGRAPHIC MEASUREMENT: For precise measurement, a true anteroposterior radiograph of both wrists is taken for comparison. Two lines are marked perpendicular to the long axis of the radius. The first line is at the level of the tip of the radial styloid process and the second line intersects the distal articular surface of the ulnar head. The distance between the two lines is the radial length and is usually 11 to 12 mm.⁽⁴⁾

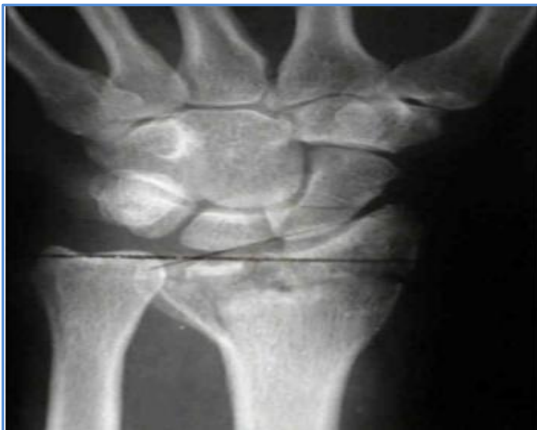

Fig. 2

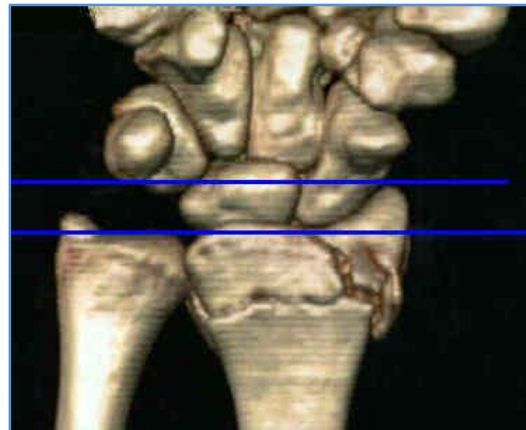

Fig. 3

RESULTS:

- Out of the 32 patients studied 21 were female and 11 were male.
- Out of the 32 patients studied 19 patients had associated osteoporosis.
- Out of the 32 patients studied 11 patients had comminution in their fracture.
- Out of the 32 patients studied the 3 were between 30 to 40 years of age, 19 were between 40 to 50 years of age, 7 were between 50 to 60 years of age and 3 were above 60 years of age.
- Average shortening noted at immediate postoperative period was 0 to 2 mm.
- Average shortening noted at 6 weeks after removal of fixator was about 1 to 4 mm.

ORIGINAL ARTICLE

- Shortening was more in patients in the age after 50 years.
- Shortening was more in patients with comminution of their fractures.
- Shortening was more in patients with associated osteoporosis.

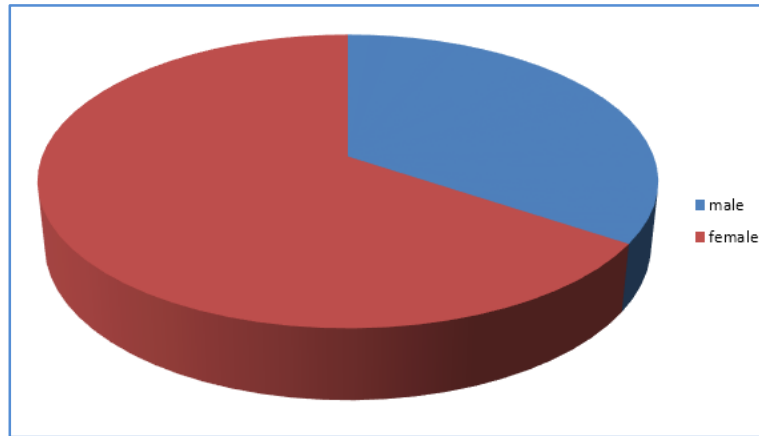


Fig. 4: Sex ratio in the patients studied: Females – 65.6%, Males – 34.4%

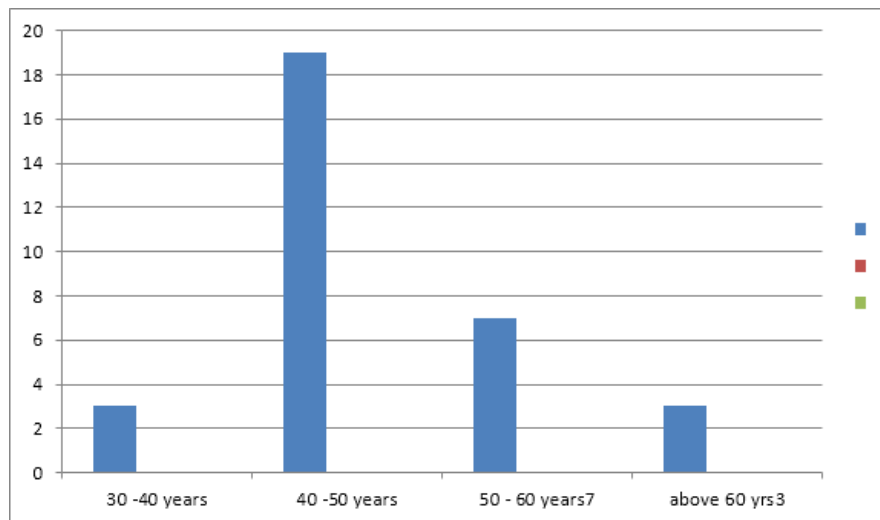


Fig. 5: Age wise distribution of patients taken up in the study

Associated Comminution of Fracture	Age	No. of Patients.	Associated Osteoporosis	Average Shortening in Immediate Post-Operative X-ray	Average Shortening in X-ray at 10 Week After Operation
	30–40 years	3	0	0mm	1mm
3	40–50 years	19	10	1mm	2mm

ORIGINAL ARTICLE

5	50–60 years	7	6	1mm	3mm
3	Above 60 years	3	3	2mm	4mm
11	TOTAL	32	19		

Table showing the Results of the study

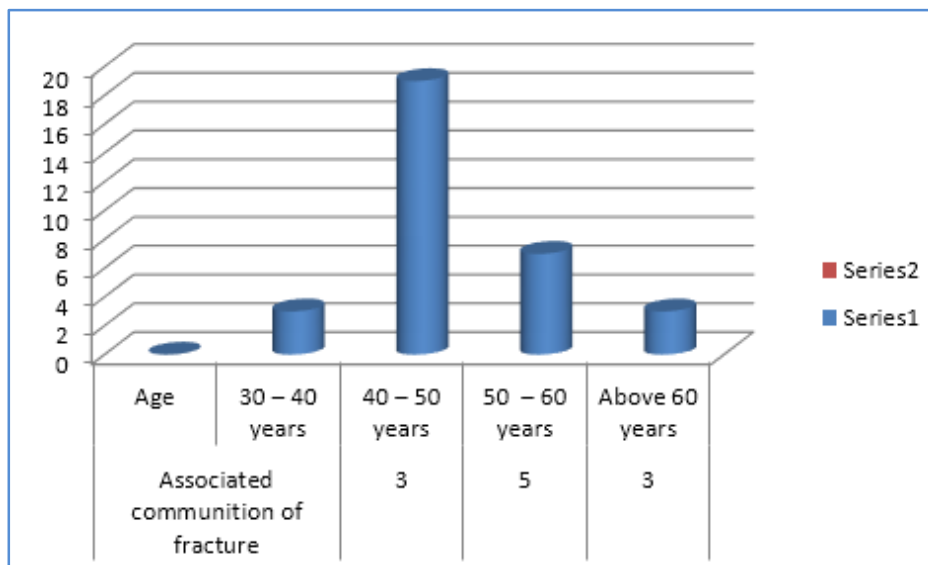


Fig. 6: Bar diagram depicting the percentage of patients with associated comminution of the fracture

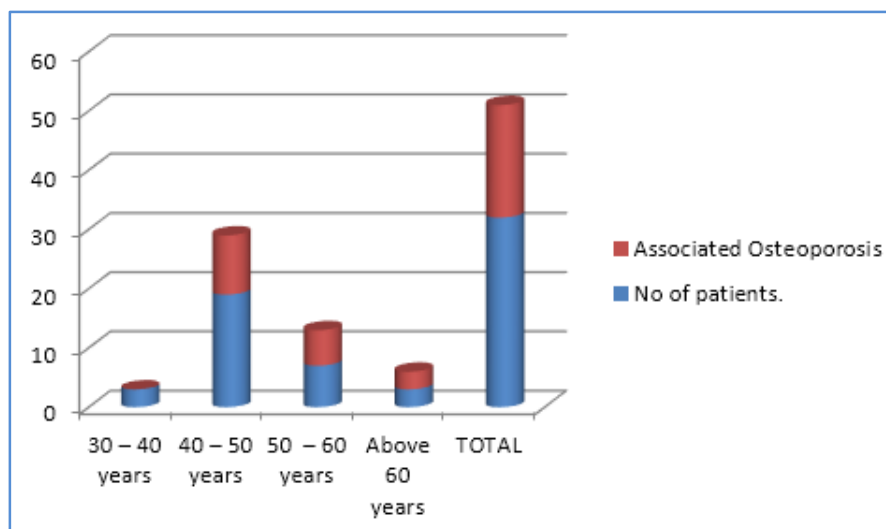


Fig. 7: Bar diagram depicting the ratio of patients with osteoporosis

ORIGINAL ARTICLE

DISCUSSION: Fractures of the distal end of the radius is a common entity in a referral hospital in Sikkim. These fractures are treated in different methods like Plaster immobilisation after manipulation and correction of deformity, Percutaneous pin and plaster, internal fixation with plate and screws⁽⁷⁾ and external fixation with external fixator. Whatever the method of treatment used shortening is a common complication that is found in all treated cases. Our study shows similar results to Hannu T Aro.⁽⁸⁾

We have found that external fixator with ligamentaxis is a good method of treating such fractures in our set up. The patients are all usually above 40 years and not suitable for long operative procedure under Anesthesia.⁽⁹⁾ We have calculated the average shortening that results from treatment with external fixator. We have found that the shortening that is occurring is due to osteoporosis and associated comminution of the fracture which results in late collapse of the fracture.

CONCLUSION: Thus we conclude that on treating fractures of the distal end of the radius with external fixator we had encountered an average shortening of 0mm to 2 mm in the immediate postoperative period, and a shortening of 1 mm to 4 mm at 10 weeks postoperative period. It is seen that shortening is more common in patients with associated osteoporosis and associated comminution of the fracture.

REFERENCES:

1. John T Anderson, MD, Resident in Orthopedic Surgery, George L Lucas, Bruce R Buhr, Iowa Orthop J, 2004;24: 53-59, Complications of treating Distal Radius Fractures with External Fixation: A Community Experience.
2. Warwick D¹, Prothero D, Field J, Bannister G. J Hand Surg Br. 1993 Feb; 18(1): 50-2. Radiological measurement of radial shortening in Colles' fracture. J Hand Surg Br. 1993 Feb; 18(1):50-2.
3. Clifford R. Wheelless' Distal radial fractures. Text book of Orthopedics,2015
4. S. Terry canale, James H.Beaty. Campbell's Operative Orthopaedics, 12th edition, 2012
5. Cooney Wiallim P, Ronald L linschild and James H Dobyns, Rochester Minnesota, Mayo clinics and foundation. The jurnal of Bone and Joint surgery, 1979.
6. John J Gartland Jr, Charles W. Werley, LBJs AM 1951 Oct 33. Evaluation of Healed Colles Fractures.
7. Peter R Carter, Hugh A Frederich, Gerogian F Laseter, Open reduction and internal fixation of unstable distal radius fractures. JBJSm Vol 23, Issue 2, 1998.
8. Hannu T Aro, Terhi Koivunen, Minor axial shortening of radius outcome of Colles Fracture treatment. Journal of Hand Surgery Vol 16, issue 3, 1991.
9. David L Nelson, Indications for reduction in Distal Radius Fractures, AAos, sumer Institute, Sand diego, Sept 1996.

ORIGINAL ARTICLE

AUTHORS:

1. Sanjoy Chakravarty
2. Manjuri Kataki
3. Ujjawal Pradhan

PARTICULARS OF CONTRIBUTORS:

1. Assistant Professor, Department of Orthopedics, Sikkim Manipal Institute of Medical Science, Tadong, Sikkim.
2. Assistant Professor, Department of Microbiology, Gauhati Medical College, Guwahati.
3. Assistant Professor, Department of Orthopedics, Sikkim Manipal Institute of Medical Science, Tadong, Sikkim.

NAME ADDRESS EMAIL ID OF THE CORRESPONDING AUTHOR:

Dr. Sanjoy Chakravarty,
Flat No. B2S,
Landmark Apartment,
Anil Nagar, Rajgarh Link Road,
P. O. Ulubari, Guwahati-781007.
E-mail: sanjoy.chakravarty88@gmail.com

Date of Submission: 29/08/2015.
Date of Peer Review: 30/08/2015.
Date of Acceptance: 03/09/2015.
Date of Publishing: 08/10/2015.