

FOLLICULAR THYROID CARCINOMA PRESENTING AS SCALP METASTATIC NODULE*Kanwardeep Kaur Tiwana¹, Sarita Nibhoria², Manmeet Kaur Punia³, Jagpreet Kaur Brar⁴*¹Associate Professor, Department of Pathology, GGS Medical College, Faridkot.²Associate Professor, Department of Pathology, GGS Medical College, Faridkot.³Assistant Professor, Department of Pathology, GGS Medical College, Faridkot.⁴Postgraduate Student, Department of Pathology, GGS Medical College, Faridkot.**ABSTRACT****BACKGROUND**

Thyroid malignancies generally present as neck masses. Occult malignancies presenting with metastasis is a rare finding. This case report highlights the rare presentation of thyroid follicular carcinoma as scalp nodule.

KEYWORDS

Thyroid, Follicular carcinoma, metastasis

HOW TO CITE THIS ARTICLE: Tiwana KK, Nibhoria S, Punia MK, et al. Follicular thyroid carcinoma presenting as scalp metastatic nodule. *J. Evid. Based Med. Healthc.* 2016; 3(78), 4253-4254. DOI: 10.18410/jebmh/2016/906

INTRODUCTION: Cutaneous metastasis from internal malignancies are rare and often a marker of advanced disease with poor prognosis. Thyroid carcinoma is the most common endocrine malignancy. It usually presents as a thyroid nodule but occasionally patient manifests with unusual features.^[1,2] Cutaneous metastasis from thyroid carcinoma is rare. It occurs in disseminated cases or may be the initial manifestation of an asymptomatic occult neoplasm of thyroid gland. Metastatic scalp lesions can vary in appearance and might be misdiagnosed as benign or primary skin tumours. Therefore a high index of suspicion is necessary to reach the exact diagnosis. In this report, we aim to present a case report of 76 years old female presenting with scalp metastasis of follicular thyroid carcinoma as the presenting sign.

CASE REPORT: A 76 year old woman presented with a brown coloured nodule on the scalp, enlarging in size. There was no other complaint of the patient. The nodule was resected with a provisional diagnosis of a skin adnexal tumour/cyst and submitted for histopathological examination. Histological examination revealed the presence of follicular arrays of thyroid follicle epithelial cells. No nuclear overcrowding, grooving, clearing or intranuclear inclusions identified. Fig. 1, 2 and 3 (40x, 100x and 400x). As per the findings, diagnosis of metastatic follicular thyroid carcinoma was made. The patient was investigated for thyroid nodule. CT scan was done and a small nodule was identified in the left lobe of thyroid. The patient was advised excision of thyroid nodule but was lost in follow up.

DISCUSSION: Cutaneous metastasis from thyroid carcinoma is rare. Dahl et al reported 43 cases of thyroid carcinoma with skin metastasis in their review of the literature between 1964 and 1987. Papillary thyroid carcinoma was the most common histological type representing 41% of cases.^[3] In contrast Koller et al reported that follicular thyroid carcinoma is more likely to have cutaneous metastasis.^[4] Scalp was the most common site of cutaneous metastasis in *both reports. Another study by Arslan S, Arslan E reported 38 cases of scalp metastasis from thyroid carcinoma with follicular carcinoma being the most common type (46%) followed by papillary (35%) medullary (6%) and anaplastic (3%) of all cases.^[5] Metastatic thyroid carcinoma involving the skin can easily be mistaken for a primary adnexal tumour especially in cases of an occult primary, as was in our case. The correct diagnosis requires a high index of suspicion and use of immunohistochemical stains. Follicular carcinoma has a more aggressive course than PTC and it has a propensity for vascular invasion and haematogenous metastasis are more likely to occur to bones and lungs.^[6] The other common sites are brain, liver and adrenal gland. The occurrence of skin metastasis from FTC is extremely rare and scalp is the most effected site.^[7] Face, neck, chest, arm and pelvis are the other cutaneous sites affected.^[8] Eighteen cases of FTC metastasis to scalp were reported in the Literature. Lissak et al reported two cases of follicular microcarcinoma revealed by solitary scalp metastasis.^[1] Koller et al reported another case of solitary scalp metastasis from follicular thyroid carcinoma as the presenting symptom in an 81 year old woman.^[4] Metastatic thyroid carcinoma of scalp may be a diagnostic challenge. Clinically, the investigation of scalp nodule should include the possibility of metastatic thyroid carcinoma.

Financial or Other, Competing Interest: None.

Submission 03-09-2016, Peer Review 10-09-2016,

Acceptance 23-09-2016, Published 29-09-2016.

Corresponding Author:

Dr. Jagpreet Kaur,

VPO Tehna, Faridkot District, Punjab.

E-mail: brarjagpreet5@gmail.com

DOI: 10.18410/jebmh/2016/906



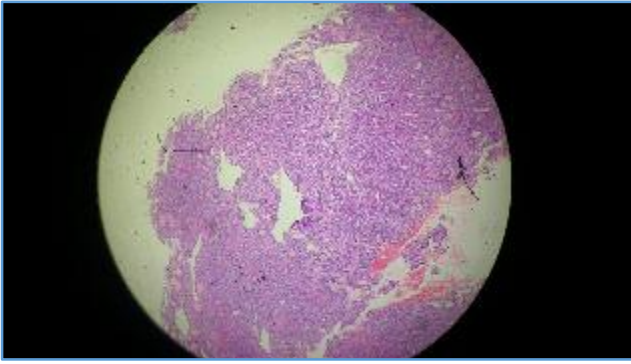


Fig. 1 (40x)

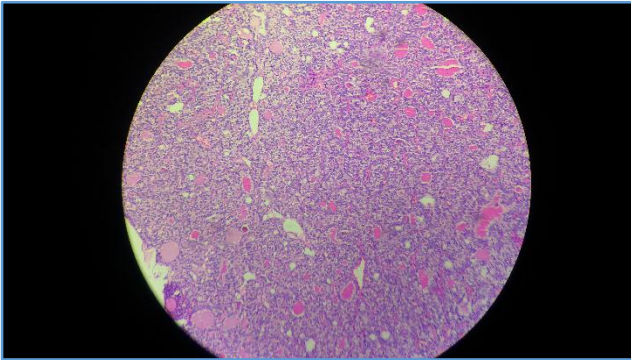


Fig. 2 (100x)

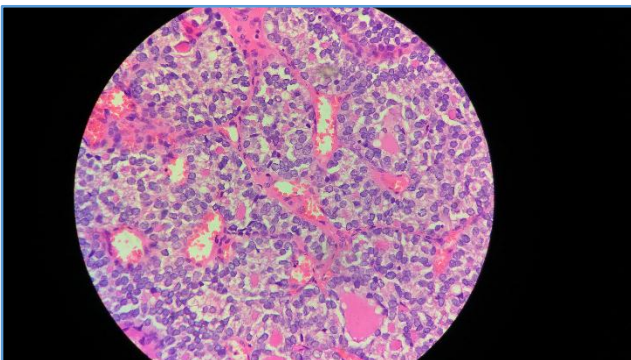


Fig. 3 (400x)

CONCLUSION: Occult Thyroid carcinoma may present with a metastatic skin nodule. Scalp nodules in particular should always be examined with this differential diagnosis.

REFERENCES

1. Lissak B, Vannetzel JM, Galiouedec N, et al. Solitary skin metastasis as the presenting feature of differentiated thyroid microcarcinoma: report of two cases. *J Endocrinol Invest* 1995;18(10):813-816.
2. Toyota N, Asage H, Hirokawa M, et al. A case of skin metastasis from follicular thyroid carcinoma. *Dermatology* 1994;188(1):69-71.
3. Dahl PR, Brodland DG, Goellner JR, et al. Thyroid carcinoma metastatic to the skin: a cutaneous manifestation of a widely disseminated malignancy. *J Am Acad Dermatol* 1997;36(4):531-537.
4. Koller EA, Tourtelot JB, Pak HS, et al. Papillary and follicular thyroid carcinoma metastatic to the skin: a case report and review of the literature. *Thyroid* 1998;8(11):1045-1050.
5. Arslan S, Arslan E. Scalp metastasis from thyroid carcinomas: review of clinical and pathological features. *J Med Updates* 2014;4(2):71-76.
6. Nashed C, Sakpal SV, Cherneykin S, et al. Medullary thyroid carcinoma metastatic to skin. *J Cutan Pathol* 2010;37(12):1237-1240.
7. Rodrigues G, Ghosh A. Synchronous bony and soft tissue metastasis from follicular carcinoma of the thyroid. *J Korean Med Sci* 2003;18(6):914-916.
8. Agarwal S, Rao S, Arya A, et al. Follicular thyroid carcinoma with metastasis to skin diagnosed by fine needle aspiration cytology. *Indian J Pathol Microbiol* 2008;51(3):430-431.