

FNAC SPECTRUM OF HEAD AND NECK LESIONS - A RETROSPECTIVE STUDY*Rashmi Rekha Goswami¹, Dipankar Baruah², Gitali Devi³*¹Assistant Professor, Department of Pathology, Fakhruddin Ali Ahmed Medical College & Hospital, Barpeta.²Associate Professor, Department of Pathology, Fakhruddin Ali Ahmed Medical College & Hospital, Barpeta.³Assistant Professor, Department of Pathology, Fakhruddin Ali Ahmed Medical College & Hospital, Barpeta.

ABSTRACT

BACKGROUND

Head and neck lesions are very commonly encountered superficial lump in cytopathology department and swellings in this region rarely go unnoticed. FNAC (fine needle aspiration cytology) is of great value in early diagnosis and differentiation of large number of infective, benign and malignant lesions in head and neck region.

AIMS AND OBJECTIVES

To study the spectrum of various head and neck lesions on the basis of FNAC in a tertiary care hospital.

MATERIAL AND METHODS

This retrospective study was done from outpatient as well as in-patient department with palpable head and neck swellings referred to dept. of pathology, Fakhruddin Ali Ahmed Medical College and Hospital, Barpeta, Assam. A total no of 933 cases were selected during a period of April 2011 to April 2015. The FNAC spectrum of various head and neck lesions are studied.

RESULTS

Out of 933 cases, 489 (52.4%) were male and 444 (47.5%) were female. Maximum number of patients were in the age group of 11 to 20 years (19.9%). 869 cases show satisfactory smears. In satisfactory smears of FNAC, involvement of lymph node is most common 53.8%, followed by soft tissue and miscellaneous lesions comprising 22.1%, thyroidal lesions 16.9% and salivary gland lesions 7.1%.

CONCLUSION

Our study found that FNAC can be recommended as a first line of investigation in the diagnosis of head and neck lesions.

KEYWORDS

Diagnosis, Head and Neck lesions, FNAC.

HOW TO CITE THIS ARTICLE: Goswami RR, Baruah D, Devi G. FNAC spectrum of head and neck lesions - a retrospective study. J. Evid. Based Med. Healthc. 2016; 3(13), 400-405. DOI: 10.18410/jebmh/2016/94

INTRODUCTION: Fine needle aspiration cytology is a relatively painless procedure, speedy and less costly with low risk of complications. FNAC was first used as diagnostic tool in 1904 by Greig and Gray and by Martin and Ellis, who developed its use in the diagnosis of malignancy.¹ Fine needle aspiration cytology (FNAC) is a valuable technique in investigation of nodules and masses arising within the head and neck. The diagnosis of head and neck swelling is a common clinical dilemma. A large number of diseases can manifest as visible lump in this region. So the purpose of this study is to see the frequency of distribution of various pathological conditions detected on FNAC in patients presenting with head and neck swelling and to evaluate the role of FNAC in their diagnosis in this area of Assam, as no such studies were done previously.

FNAC is particularly helpful because biopsy of this area can be avoided unless all other diagnostic modalities have

failed to establish a diagnosis. As such FNAC represent an accurate, inexpensive and rapid investigative technique of head and neck masses.² In diagnosing neoplastic from non-neoplastic lesion FNAC has great value of the multiplicity of accessible organs and heterogeneous pathologies encountered thus eliminating the need for surgical intervention and exposure to anaesthesia which can be managed conservatively and also guide clinicians for the next best step in patient management.

Head and neck swellings are of great clinical significance as underlying disease may range from a treatable infectious etiology to malignant neoplasm. Virtually any superficial organ or tissue can be sampled through FNAC. Easily targeted organs include thyroid, breast, or lymph nodes. Whereas deep organs like lungs, liver, kidney, mediastinum, and retro peritoneum are aspirated with the guidance of ultrasonography and computed tomography. Swellings in head and neck region can arise from various structures like, lymph nodes, salivary glands, thyroid, soft tissues, vessels and nerves and being easily accessible, the swellings can be aspirated without difficulty. FNAC is now a prerequisite for various neck swellings as the procedure is non-traumatic, easily accessible, inexpensive, excellent compliance and

Submission 22-01-2016, Peer Review 06-02-2016,

Acceptance 11-02-2016, Published 15-02-2016.

Corresponding Author:

Dr. Rashmi Rekha Goswami,

*C/o. Dr. Swarup Sarma Basistha, Alternative Road,
Nalbari Maternity Hospital, Nalbari-781335, Assam.*

E-mail: rashmi.patho@yahoo.co.in

DOI: 10.18410/jebmh/2016/94

avoids the anaesthetic complications and requirement of open surgical biopsy.^{3,4} There is no evidence that the tumour spreads through the skin track created by the fine hypodermic needle used in this technique.⁵ FNAC can be both diagnostic and therapeutic in cystic swellings.⁶ Fine needle aspiration cytology is helpful for the diagnosis of salivary gland tumours where it can differentiate between a malignant and a benign tumour with over 90% accuracy.⁷ FNAC is particularly helpful in the work-up of cervical masses and nodules because biopsy of cervical adenopathy should be avoided unless all other diagnostic modalities have failed to establish a diagnosis.⁸ Fine needle aspiration cytology does not give the same architectural detail as histology but it can provide cells from the entire lesion as many passes through the lesion can be made while aspirating.⁹ All neck masses should undergo FNAC and culture if necessary.¹⁰ An early differentiation of benign from malignant pathology greatly influences the planned treatment.¹¹

AIM AND OBJECTIVES: To study the spectrum of various head and neck lesions on the basis of FNAC in a tertiary care hospital.

MATERIAL AND METHODS: This retrospective study was done from outpatient as well as in patients department with palpable head and neck swellings referred to dept. of pathology, Fakhruddin Ali Ahmed Medical College and Hospital, Barpeta, Assam. A total no of 933 cases were selected during a period of 4 years (April 2011 to April 2015). After explaining the procedure to the patient, a formal informed consent was taken along with brief clinical history and information from other radiological and laboratory investigations were noted.

Fine needle aspiration cytology was done under aseptic condition using 22 -23 gauge needle fitted to 10 ml disposable syringe attached to plunger. Smears were prepared from the material. Air dried smears were stained with May Grunwald Giemsa stain. Alcohol fixed smears were stained with Papanicolaou (PAP) stain as and when necessary. The Ziehl-Neelsen stain for acid fast bacilli were done in suspected tubercular lesions. Repeat Fine needle aspiration was done in those cases where the yield was inadequate in the first aspiration. A minimum of three smears were prepared by cytopathologists following standard guidelines for FNAC. Aspirations taken from various sites include lymph nodes, thyroid, salivary glands and soft tissues.

RESULTS: The present study included 933 cases of palpable head and neck lesions from patients of various departments of F.A.A. Medical College & Hospital. FNAC was performed in the age group of 6 months to 90 years. Among 933 cases 489 (52.4%) were male and 444 (47.5%) were female. (Table -II). M:F ratio is 1.1:1. Out of 147cases of thyroid lesions 118 were female and 29 were male.

Maximum number of patients were in the age group of 11 to 20 years (19.9%) followed by 21 to 30 years (18.6%) and 31to 40 years (18.2%). Least number of patients were seen in the age group above 70 years.

In total 933 cases, 64 were excluded from the study as they were inconclusive or unsatisfactory. The percentage of unsatisfactory smears was 6.4%.

In satisfactory smears of FNAC, involvement of lymph node is most common 53.8%, followed by soft tissue and miscellaneous lesions comprising 22.1%, thyroidal lesions 16.9% and salivary gland lesions 7.1%. (Table I)

Organ involved	Number	Percentage
Lymph node	468	53.8%
Thyroid	147	16.9%
Salivary gland	62	7.1%
Soft tissue and miscellaneous	192	22.1%

Table 1: Distributions of various head and neck lesions according to site (Total satisfactory FNAC- 869)

Total number of cases	Male	Female
933	489 (52.4%)	444 (47.5%)

Table 2: Distribution of males and females in total head and neck lesions

Among 468 cases of lymph node lesions, reactive lymphoid hyperplasia (32.1%) was the predominant cause of lymphadenopathy followed by granulomatous/tubercular lymphadenitis (27.3%), malignant 23.3% and inflammatory lesions 17.3%. In malignant lesions, metastatic epithelial malignancy was the predominant finding (20.5%). 2.7% (13) cases of primary malignancy i.e. lymphoma were found (Table III). Amongst 13 cases 9 were Non Hodgkin Lymphoma and 4 were Hodgkin's lymphoma. For final diagnosis in all cases of lymphoma biopsy and histopathological examination was advised.

Lesions	No. of cases	Percentage
Reactive lymphoid hyperplasia	150	32.1%
Granulomatous/tubercular lymphadenitis	128	27.4%
Inflammatory lymphadenitis	81	17.3%
Metastatic	96	20.5%
Lymphoma(malignancy)	13	2.7%

Table 3: Distribution of various lymph node lesions (Total number-468)

Out of 147cases of thyroid lesion, colloid goitre were 67.3% and the incidence of colloid goitre was much higher in female (88.9%) than male (11.1%). Follicular neoplasm constitute about (8.2%) of cases. 5.4% were cystic lesion of thyroid and similar 5.4% were thyroglossal cyst. 6.1% cases show inflammatory lesions, including Hashimoto's thyroiditis and granulomatous thyroiditis. In our study malignant lesion of thyroid constitute about 7.4%. Among these malignant lesion 5.4% were papillary carcinoma and 2.0% were anaplastic carcinoma (table-IV).

Lesions	No. of Cases	Percentage
Inflammatory	9	6.1%
Colloid goitre	99	67.3%
Cystic lesions of thyroid	8	5.4%
Thyroglossal cyst	8	5.4%
Follicular neoplasm	12	8.2%
Papillary carcinoma	8	5.4%
Anaplastic carcinoma	3	2.0%

Table 4: Distribution of various thyroidal lesions (Total number-147)

In all thyroid lesions female outnumbered the male except in thyroglossal cyst (out of 8 cases 5 were male and 3 were female in our study).

Salivary gland lesions constitute 7.1% of head and neck swelling, out of which benign tumour pleomorphic adenoma is the commonest 43.5%, followed by inflammatory lesions 25.8%. Malignant lesions comprising of 17.7% cases. The most common malignant lesion of salivary gland in our study is mucoepidermoid carcinoma (11.3%) (Table-V).

Lesions	No.	Percentage
Inflammatory	16	25.8%
Benign non neoplastic cyst	6	9.6%
Pleomorphic adenoma	27	43.5%
Basal cell neoplasm	2	3.2%
Mucoepidermoid carcinoma	7	11.3%
Adenocarcinoma(NOS)	2	3.2%
Adenoid cystic carcinoma	2	3.2%

Table 5: Distribution of various salivary gland lesions (Total number-62)

FNAC of soft tissue and miscellaneous lesions constitute 192 cases (22.1%) with varied pathological lesions like epidermal cyst (40.6%) and lipoma (23.9%) being the predominant one. (Table-VI).

Lesions	No	Percentage
Epidermal cyst	78	40.6%
Lipoma	46	23.9%
Branchial cyst	2	1.0%
Inflammatory	3	1.5%
Vascular lesion including hematoma	13+3	8.3%
Spindle cell lesion	12	6.2%
Pilomatrixoma	1	0.52%
Schwannoma	1	0.52%
Dermoid cyst	1	0.52%
Basal cell carcinoma	1	0.52%
Benign adnexal tumour	1	0.52%
Other cystic lesions	30	15.6%

Table 6: Distribution of various Soft tissue and miscellaneous lesions (total number-192)

DISCUSSION: FNAC has been in practice since it was first introduced for the diagnosis of organ lesions in 1930 by Martin and Ellis.¹² FNAC is a valuable technique in

investigation of nodules and masses arising in head and neck region. This procedure can easily distinguish between non-neoplastic and neoplastic conditions like tuberculosis and reactive lymph node from malignant and metastatic thus preventing unnecessary surgery.

The study included patients of all age groups. The Maximum number of cases are observed below 50 years of age and least number of cases above 70 years of age which is similar to the study done by Setal Chauhan et al¹³ and Kishor H et al.¹⁴

In our study number of male patients are higher than female (52% male and 48% female with M:F ratio 1.1:1). This is comparable to Mohd Hazmi Mohamed et al¹⁵ (53% male and 47% were female), Palak Modi et al¹⁶ (52% male and 48% female M: F= 1:1.06) and Deval N Patel et al¹⁷ (52% male and 48% female) But some other studies show female preponderance (Kishor H et al, Fernandes H, Vijay Tilak et al and Ahmad T et al).^{14,18,19,20}

Out of 933 patients, only in 64 (6.40%) cases smears were unsatisfactory and remaining 93.6% smears were satisfactory. This is comparable to Nail Tariq et al 2005,²¹ where the rate of satisfactory smears was 96%. Savitri Chauhan et al²² in the year 2012 established the satisfactory smears as 92.2 %. Similar study was done by Vasudha M Bhagat et al²³ 2013, reported 90% aspirates were satisfactory.

In satisfactory smears maximum number of patients were of Lymph node origin (53.8%.) in our study, which is again comparable to Vasudha M Bhagat et al 2013²³ (53.50% were of lymph node origin), Deval N Patel et al¹⁷ (64% lymph node origin), Kishor et al¹⁴ (39.58% lymph node origin) and Chauhan Savitri et al²² (67.8% were of lymph node origin). But a few studies show thyroid preponderance (Gunavanti B Rathod et al²⁴ 52% were thyroid lesion). Lymph node lesions are the commonest cause of head and neck swelling in our study attributed to FNAC diagnosis. FNAC can diagnose inflammatory cases and unnecessary surgery can be avoided.

In our study Thyroid and salivary gland lesion were 16.9 % and 7.1 % respectively, which is comparable to study done by Palak Modi et al 2014¹⁶ of thyroid lesion 16.1 % and salivary gland lesion was 6.8%.

FNAC of soft tissue and miscellaneous lesions constitute 192 cases (22.1%) out of 869 total number of patients with satisfactory FNAC. This can be compared to study done by Palak Modi et al 2014¹⁶ (20.59 %), which is significantly similar to our study.

In lymph node lesions, the reactive lymphadenitis in our study is 32.1% which is comparable to Suryawanshi Kishor H et al¹⁴ 2015 (35.08%), Mohd Hazmi Mohamed et al¹⁵ (45.8%). El-Hag et al²⁵ supported their publication carried out in Saudi Arabia over a period of 5 years, out of 225 patients, reactive lymphadenitis was found to be 33%. According to El-Hag et al the commonest cause of neck swelling was reactive lymphadenopathy. Deval Patel et al also showed the most common cause of lymphadenopathy was reactive lymphoid hyperplasia (47%). However, the percentage of reactive lymphadenitis in studies done by

Gunvanti B Rathod²⁴ (18%) and Tariq et al²¹ (19.3%) is not similar to our studies. In their studies they found tubercular lymphadenitis as the most common lymph node lesion (42.12% and 36% respectively).

Tubercular lymphadenitis is the second most common occurrence in our study (27.4%) as comparable to Deval N Patel et al¹⁷ (25%) and El Hag et al²⁵ (21%), Mohd Hazmi Mohamed et al¹⁵ (29.5%).

Metastatic epithelial carcinoma to lymph node is quite high in our study (20.5%) which is comparable to Deval N Patel et al¹⁷ (27%), Gunavanti B Rathod et al²⁴ (21.05%) and Tariq et al²¹ (21.5%). While some other studies show low percentage of metastatic carcinoma (3.5% by Kishor et al,¹⁴ 7% by Savitri Chauhan et al²² and 8% by Vashudha M Bhagat et al.²³ Metastatic carcinoma shows epidemiological variations. In our study, metastatic squamous cell carcinoma was the most common metastasis to lymph node. This may be due to increased incidence of squamous cell carcinoma of upper aero-digestive tract in this part of Assam.

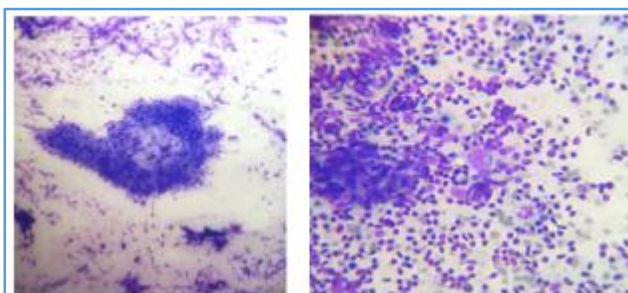
In our study the incidence of thyroid lesions are more common in female than male (29 cases of male and 118 cases are of female constituting male: female ratio 1:4.1) which is similar to Deval N Patel et al,¹⁷ YM spiral²⁶ and Nazma Agroz's study.²⁷ Female preponderance was also found by Gunavanti B Rathod et al (84.61%) and Praneshpradad²⁸ with male to female ratio 1:4 and 1:5 respectively. We have found less number of inflammatory cases of thyroid in our study (6.1%). Chauhan Savitri et al²² found 5% inflammatory lesions, 10% by Deval et al,¹⁷ 28.8% by Kishor et al.¹⁴ Colloid goitre including colloid nodular goitre is the predominant thyroid lesion (67.3%) in our study. Similar findings were found in studies done by Suryabanshi Kishor et al¹⁴ (47.77%), Muddegowda et al²⁹ (60%), Palak and Modi et al¹⁶ (83%), Savitri Chauhan et al²² (85%) and Gunavanti B Rathod et al (55.77%).²⁴ Female preponderance of thyroid lesions is observed in various studies. In our study only in case of thyroglossal cyst, males outnumbered the females. Among malignant lesions, papillary carcinoma is highest (5.4%) in our study which is comparable to Gunavanti B et al.²⁴

In salivary gland lesions, pleomorphic adenoma is the most common lesion in our study (43.5%) Similar findings are seen in various studies done by Gunavanti B Rathod et al,²⁴ Deval N Patel et al¹⁷ and Setal Chauhan et al.¹³ Mucoepidermoid carcinoma is found in 11.3% of cases in our study while Deval N Patel et al¹⁷ and Solanki piyush K et al³⁰ reported 8% & 10% respectively.

In our study soft tissue and miscellaneous lesions occupy the second position among all head and neck lesions. This may be due to high occurrence of epidermal cyst in this locality. Epidermal cyst is the most common lesion in soft tissues and miscellaneous group (40.6%) followed by lipoma (23.9%) which is similar to the findings of Kishor et al¹⁴ where epidermal cyst was 57.14% and lipoma was 23.8%.

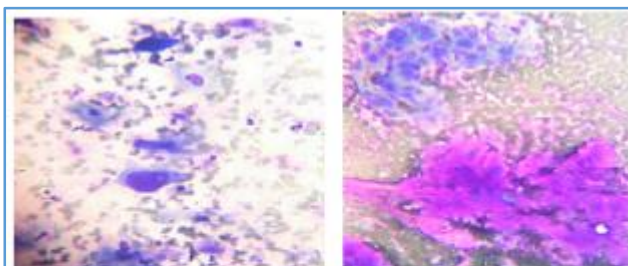
Bhagat et al²³ also found epidermal cyst (24%) as the most common soft tissue lesion followed by lipoma 12.4%). The higher incidence of epidermal cyst in this locality is an interesting subject for further research.

CONCLUSION: From our present study we have found wide range of diseases that can presents as head and neck swelling and can be diagnosed by fine needle aspiration cytology. It could differentiate the ineffective process from neoplastic one and avoid unnecessary surgeries. This procedure is well tolerated by patients without complications. It can be considered as the best initial work up in management of swellings of head and neck region. We have found lymph node lesions are the most common cause of head and neck swelling comprising mainly of reactive lymphadenitis and reactive hyperplasia. Metastatic squamous cell carcinoma occupied the major malignant lesion in this region may be due to increased incidence of squamous cell carcinoma of upper aero-digestive tract in this part of Assam. In our study we have also found very high number of epidermal cysts as soft tissue lesions. The predominance of epidermal cyst in this locality may be an interesting topic for further research.



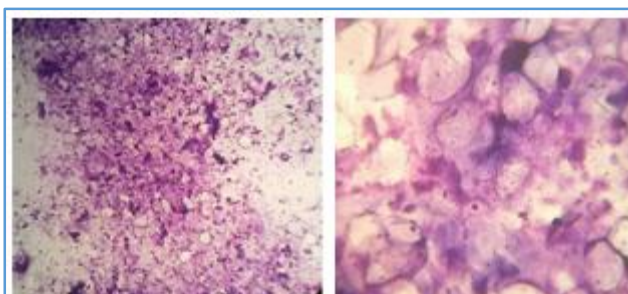
(MGG, x10)
Granulomatous
lymphadenitis

(MGG, x10)
Hodgkin's
lymphoma

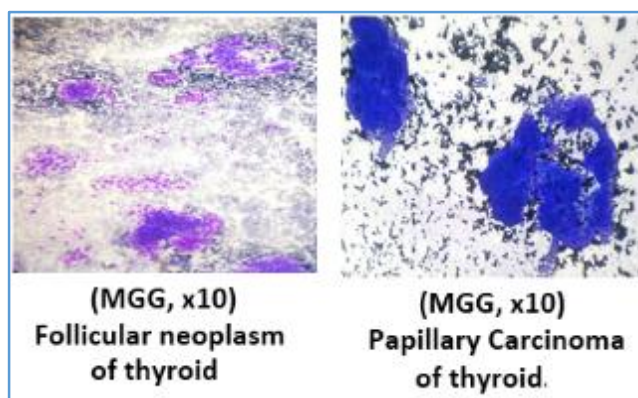
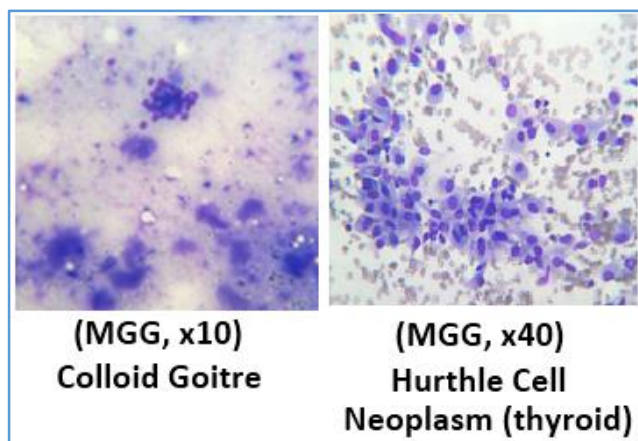


(MGG, x40)
Metastatic SCC to
lymph node

(MGG, x40)
Pleomorphic
adenoma



(MGG, x10)
Epidermal cyst



REFERENCES:

1. Tendon S, Shahab R, Benton JI, et al. Fine needle aspiration cytology in regional head and neck cancer center: comparison with a systematic review and meta-analysis. *Head Neck* 2008;30:1246-52.
2. Kocjan G. In introduction to clinical cytopathology of head and neck. editor. Clinical cytopathology of the head and neck, A text and atlas. London: Greenwich medical media Ltd 2001;3.
3. Abari A, Ahmad SS, Bakshi V. Cytology in the otolaryngologist's domain-a study of 150 cases, emphasizing diagnostic utility and pitfalls. *Indian journal Otolaryngolo Head Neck Surg* 2002;54(2):107-10.
4. Murthy P, Laing MR, Palmer TJ. Fine needle aspiration cytology of head and neck lesions: an early experience. *JR Coll Edinb* 1997;42:341-346.
5. Russel RCG, William NS, Bulstrode CJK. Bailey and love's short practice of surgery. London: Arnold 2004;24th edition.
6. Afridi S, Malik K, Wahed I. Role of fine needle aspiration biopsy and cytology in breast lumps. *J college of Physicians and Surgeons Pakistan* 1995;5:75-7.
7. Burnand KG, Young AE, Lucas J, et al. The new aird's companion in surgical studies. China: Elsevier 2005;3rd ed.
8. Layfield LJ. Fine-needle aspiration of the head and neck. *Pathology (Phila)* 1996;4:409-38.
9. Kirk RM, Ribbens WJ. Clinical surgery in general. Edinburgh: Elsevier 2004;4th ed.
10. Klingensmith ME, Amos KD, Green DW, et al. The washington manual of surgery. Philadelphia: Lippincott Williams and Wilkins 2005;5th ed.
11. Watkinson JC, Wilson JA, Gaze M, et al. Stell and Maran's head and neck surgery, butterworth-heinemann, Oxford, chapter 2, 2000;4th edition:20-21.
12. Martin HE, Ellis EB. Biopsy of needle puncture and aspiration. *Ann Surg* 1930;92:169-81.
13. Chauhan S, Rathod D, Joshi DS. FNAC of swellings of head and neck region. *Indian Journal of applied basic medical sciences* 2011;13:1-6.
14. Kishor SH, Damle RP, Dravid NV, et al. Spectrum of FNAC in palpable head and neck lesions in a tertiary care hospital in India-a 3 years study. *Indian J of pathology and oncology* 2015;2(1):7-13.
15. Moamed MH, Hitam S, Brito-Mutunayagam S, et al. Role of FNAC in evaluation of neck masses. *J Curr Surg* 2013;3(1):19-23.
16. Palak Modi, Haren Oza, Jignasa Bhalodia. Utility and adequacy of fine needle aspiration cytology in head and neck lesions: A hospital based study. *International journal of scientific study* 2014;2(8):100-105.
17. Deval N Patel, Parth B Patel, Himani V Patel, et al. Fine needle aspiration cytology role in head and neck lesions. *IAIM* 2015;2(8):99-104.
18. Farnades H, D'souza RS, Thejaswini BN. The role of fine needle aspiration cytology in palpable head and neck masses. *Journal of clinical and diagnostic research* 2009;3(5):1719-1725.
19. Vijay Tilak, Dhaded AV, Ragini Jain. Fine needle aspiration cytology of head and neck masses. *Indian journal of pathology, Microbiology* 2002;45(1):23-30.
20. Ahmad T, Naeem M, Ahmad S, et al. Fine needle aspiration cytology (FNAC) and neck swellings in the surgical outpatient. *J Ayub Med Coll Abbottabad* 2008;20(3):30-2.
21. Nail Tariq, Sadiq S, Kehar S. Fine needle aspiration cytology of head and neck lesions-an experience at Jinnah post graduate medical centre Karachi. *Pak J Otolaryngol* 2007;23:63-5.
22. Savitri C, Dimple D, Dholakia A. Fine needle aspiration cytology of neck lesion- an experience at tertiary care hospital in central Gujarat. *National journal of medical research* 2012;2(3):255-9.
23. Bhagat VM, Tailor HJ, Saini PK, et al. Fine needle aspiration cytology in nonthyroidal head and neck masses-a descriptive study in tertiary care hospital. *National Journal of Medical Research* 2013;3(3):273-76.
24. Rathod GB, Parmar P. Fine needle aspiration cytology of swellings of head and neck region. *Indian Journal of Medical Science* 2012;66(3):49-54.

25. El Hag IA, Chiedozi LC, al Reyees FA, et al. Fine needle aspiration cytology of head and neck masses. Seven years' experience in a secondary care hospital. *Acta Cytol* 2003;47(3):387-92.
26. Spiral YM. Efficacy of fine needle aspiration cytology in management of thyroid diseases. *Indian Journal of Pathology Microbiology* 1996;173-178.
27. Nazma Afroz. Role of fine needle aspiration cytology in diagnosis of palpable thyroid lesions. *Indian Journal of Pathology Microbiology* 2002;241-246.
28. Pranesh Prasad. Comparative study of FNAC and histopathology in diagnosis of thyroid swellings. *Indian journal of surgery* 1992;54:287-291.
29. Muddegowda PH, Srinivasan S, Lingegowda JB, et al. Spectrum of cytology of neck lesions: comparative study from two centres. *Journal of clinical and Diagnostic Research* 2014;8(3):44-45.
30. Solanki Piyush K, Patel Ankur P, Taviad Pankaj P, et al. Fine needle aspiration cytology as a diagnostic procedure in head and neck swellings. *National journal of community Medicine* 2012;3(3):433-436.