

FIBRIN ADHESIVE VERSUS SUTURES FOR CONJUNCTIVAL AUTOGRAFTING IN PTERYGIUM SURGERY- A PROSPECTIVE COMPARATIVE STUDY

Geetha Kumari Padinjarepattath Vasudevan¹, Rekha Pookkatt Sankaranarayanan²

¹Assistant Professor, Department of Ophthalmology, Government Medical College, Thrissur, Kerala.

²Assistant Professor, Department of Ophthalmology, Government Medical College, Thrissur, Kerala.

ABSTRACT

BACKGROUND

Pterygium is a common ocular surface lesion. High rates of recurrence make its management challenging. Use of fibrin bio-tissue adhesive (fibrin glue) for attaching the grafts may shorten operating time, improve postoperative comfort and avoid suture-related complications.

The aim of the study is to reveal the effectiveness and safety of using fibrin glue in place of sutures during conjunctival autograft surgery for primary pterygium.

MATERIALS AND METHODS

A randomised clinical trial of 132 patients (132 eyes) admitted at Regional Institute of Ophthalmology, Trivandrum, for excision of primary pterygium was selected for a period of 9 months (January 2010 - September 2010).

RESULTS

Mean duration of surgery was 15.80 ± 1.56 minutes in fibrin group compared to 36.17 ± 2.44 minutes in suture group and was found to be statistically significant. The postoperative inflammatory response, so the intensity of the postoperative complaints were significantly lower in patients treated with fibrin glue.

CONCLUSION

The duration of surgery was significantly shorter in the fibrin group than in the suture group. The postoperative discomfort was significantly low in the glue group compared to other group. Signs of postoperative inflammation subsided earlier in the glue group, while they lasted longer in the suture group. Rate of recurrence was observed to be statistically insignificant between the two groups.

KEYWORDS

Pterygium, Fibrin Bio-Adhesive, Autograft, Conjunctival autograft.

HOW TO CITE THIS ARTICLE: Vasudevan GKP, Sankaranarayanan RP. Fibrin adhesive versus sutures for conjunctival autografting in pterygium surgery- A prospective comparative study. J. Evid. Based Med. Healthc. 2017; 4(95), 5924-5929. DOI: 10.18410/jebmh/2017/1195

BACKGROUND

Pterygium is a very common ocular surface lesion in our country characterised by wing-shaped growth encroaching from conjunctiva on to the cornea. UV light-induced localised damage to limbal stem cells and its deficiency has been the most recent concept for its causation.^{1,2}

Although, simple to excise, high rates of recurrence make its management challenging. The transplant of conjunctival autograft seems to be a preferable method giving both low recurrence and high safety.³ The common method of autograft fixation by means of suturing has drawbacks of prolonged operating time, significant postoperative discomfort and potential suture-related

complications like buttonholes, tissue necrosis and granuloma formation. Hence, it is logical to search for a material that can be applied to the ocular surface just like a glue to substitute for sutures.

In this situation, the importance of fibrin glue, a bio-tissue adhesive as alternative means of attaching the grafts, which may shorten operating time, improve postoperative comfort and avoid suture-related complications. Here comes the relevance of the study to compare the above two methods. Fibrin glue is a two component material-fibrinogen and thrombin that initiates final stage of coagulation pathway. These are used in various ophthalmologic surgeries and other surgeries for tissue adhesion, blood coagulation and wound healing.⁴ The purpose of this study is to reveal the effectiveness and safety of using fibrin glue in place of sutures during conjunctival autograft surgery for primary pterygium.

Aims and Objectives

- To make a comparative study in excision of primary pterygium with conjunctival autograft using fibrin adhesive and sutures.

Financial or Other, Competing Interest: None.
Submission 30-11-2017, Peer Review 05-12-2017,
Acceptance 16-12-2017, Published 19-12-2017.

Corresponding Author:

Dr. Rekha Pookkatt Sankaranarayanan,
Plot No. 111, Priyadarsini Nagar,
Paravattani, Thrissur, Kerala-680005.
E-mail: drrekhaps@gmail.com
DOI: 10.18410/jebmh/2017/1195



- To evaluate effectiveness and safety of fibrin adhesive in conjunctival autograft fixation in pterygium surgery in terms of duration of surgery, postoperative comfort, postoperative inflammation and recurrence of pterygium.

MATERIALS AND METHODS

It is a randomised clinical trial of 132 patients (132 eyes) in the age group 18-80 years of both genders admitted for excision of primary pterygium. The study period is 9 months (January 2010 - September 2010).

Inclusion Criteria

- Primary pterygium encroaching ≥ 2 mm onto the cornea.
- Patients in the age group of 18-80 years of both genders.
- Patients willing to undergo excision and to participate in study and follow-ups.

Exclusion Criteria

- Pseudopterygium.
- Recurrent pterygium.
- Uncontrolled systemic diseases.
- Patients with history of ocular surgery or ocular trauma.

Methodology- After obtaining an informed written consent, a detailed history including past medical and ocular diseases are taken from selected patients. Ocular examination including Best Corrected Visual Acuity (BCVA) by Snellen's chart, ocular movements, fundus examination and slit-lamp examination of anterior segment are done.

These 132 patients (132 eyes) are allocated into 2 groups of 66 patients (66 eyes) each by block randomisation.

Group A- Patients with primary pterygium who has undergone excision with conjunctival autografts attached in scleral bed with fibrin adhesive.

Group B- Patients with primary pterygium who has undergone excision with conjunctival autografts attached in place with 10-0 nylon sutures.

Surgical Technique- All the surgical procedures were done by the same surgeon. The procedures were carried under a combination of topical proparacaine eye drop and subconjunctival lignocaine with adrenalin injection. Under aseptic precautions, following the insertion of lid speculum, pterygium was excised. An oversized, Tenon-free graft for 1 mm of length and width relative to the graft bed was harvested from the superotemporal limbus. The dissection of the conjunctiva is extended by 0.5 mm into clear cornea to include the limbal element of the graft. The graft was subsequently attached to the excised conjunctival edges and episclera with FG in one group and by using 10-0 silk in suture group. The operating time was measured starting from the placement of lid speculum to its removal at the end of surgery.

All patients were followed up on days 1, 7, 14 and at months 1, 3, 6 and 9 months. In suture group, sutures were removed by 14th week after surgery. Patients were asked to fill out a questionnaire on 1st postoperative day and during every follow up visit until the 1st month. Detailed slit-

lamp examination is performed on each occasion to observe and record the integrity of conjunctival autografts (graft oedema, graft loss or displacement), carefully looking for any evidence of recurrence and complications such as corneal defects, symblepharon formation, giant papillary conjunctivitis, allergic dermatitis, suture-related complications like suture granuloma, button holing and suture dehiscence.

- Postoperative Comfort** is analysed by 3 factors - Pain, foreign body sensation and watering. It is assessed on 1st postoperative day, 1st week, 2nd week and 1st month by a scoring system^{5,6}- 0, 1, 2, 3, 4 (by giving a questionnaire to fill up in each visit).
 - 0 No symptoms.
 - 1 Very mild (symptoms present, but easily tolerated).
 - 2 Mild (causes some discomfort, but not interfering with daily activities).
 - 3 Moderate (symptoms partially interfering with usual activities/sleep).
 - 4 Severe (interfere completely with usual activities/sleep).
- Surgery time-** Recorded from placement of lid speculum at start of operation to its removal at end of the operation.
- Postoperative inflammation-** Assessed by graft oedema and surrounding Conjunctival Congestion (CC) and SCH (subconjunctival haemorrhage).
- Graft survival/success-** Defined as an intact graft by 4th week after surgery.
- Graft failure-** Defined as absence of the graft by 4th week.
- Graft recurrence-** Defined as growth of fibrovascular tissue into the cornea by slit-lamp examination in a case after pterygium excision.

Statistical analysis was done using SPSS version 10. To elucidate the associations and comparison between different parameters, Chi-square was used. Student's t-test was used to compare the mean values between two groups. A probability value of <0.05 was considered significant for evaluation.

OBSERVATIONS AND RESULTS

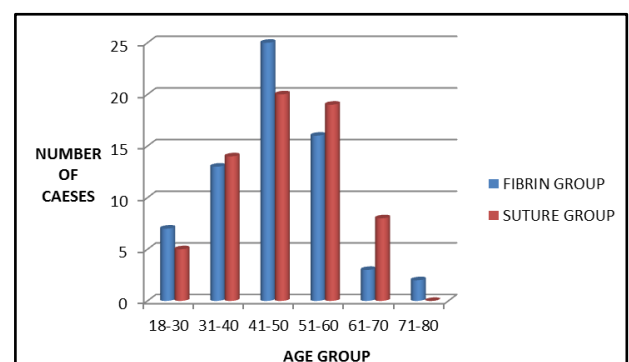


Figure 1. Analysis of Age Distribution in Both Groups

Most of the patients (34.1%) were in the 41-50 years age group in both groups. Mean age was 45.92 ± 10.95 in fibrin group and 47.27 ± 10.19 in suture group.

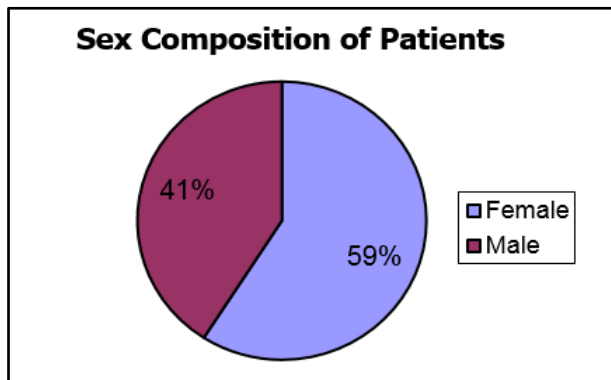


Figure 2. Analysis of Cases According to Sex

78 cases (59.09%) were females and 54 cases (40.91%) were males.

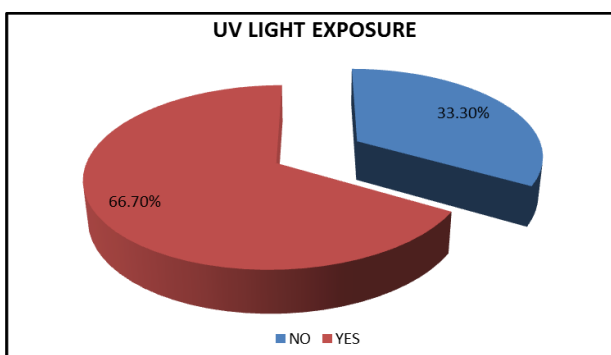


Figure 3. Analysis of Exposure of UV Light

87 patients were outdoor workers giving history of UV light exposure. Among these, 54 cases were females and 33 cases were males.

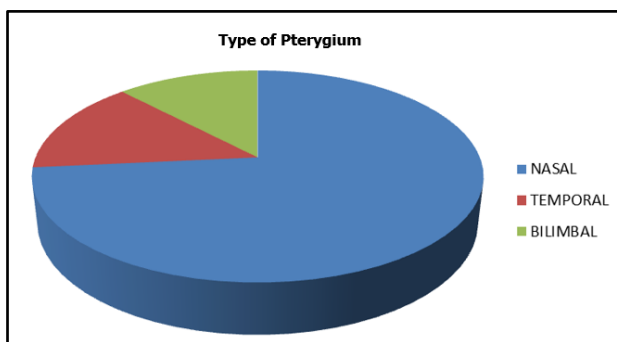


Figure 4. Analysis of Type of Pterygium

In both groups, pterygium on nasal side of bulbar conjunctiva was most common. 97 cases (73.5%) had nasal pterygium.

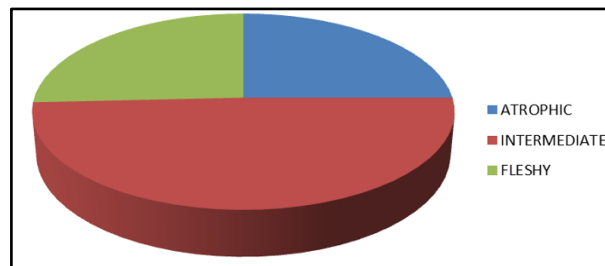


Figure 5. Analysis of Grades of Pterygium

In both groups, grade 2 (intermediate) pterygium was more common. Fleshy type of pterygium was more common among the cases <40 years.

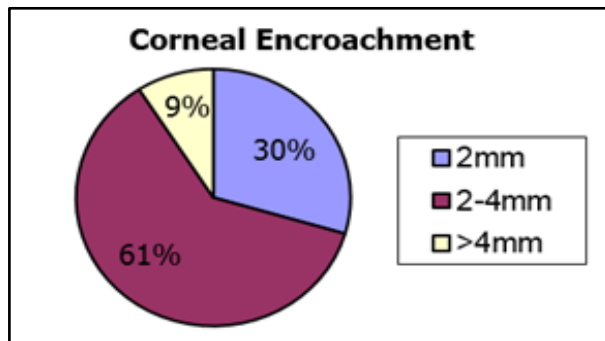


Figure 6. Analysis of Corneal Encroachment of Pterygium

81 eyes (61.4%) had 2-4 mm extension into the cornea. 12% eyes showed >4 mm extension into the cornea.

Group	Mean (in minutes)	N	Std. Deviation	Minimum	Maximum
Fibrin	15.80	66	1.561	12	20
Suture	36.17	66	2.441	28	40

Table 1. Analysis of Duration of Surgery Between Both Groups

Mean duration was 15.80 ± 1.56 minutes in fibrin group compared to 36.17 ± 2.44 minutes in suture group showed statistically significant difference between the 2 groups with p value <0.001.

Analysis of Postoperative Discomfort- Postoperative discomfort assessed by analysis of pain, foreign body sensation and watering.

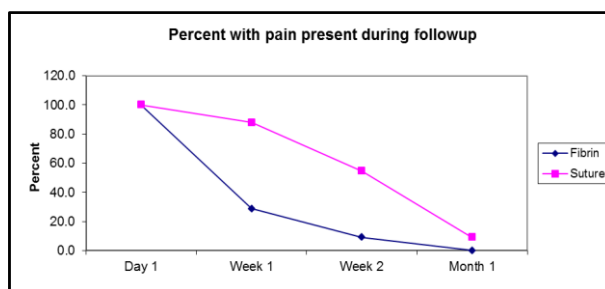


Figure 7. Analysis of Pain between Fibrin and Suture Group during 1 Month Period of Follow-up

Intensity of the pain was significantly low at 1st week and 2nd week postoperatively in patients treated with fibrin group.

Intensity of the foreign body sensation was significantly low at 1st week and 2nd week postoperatively in patients treated with fibrin group. After 2nd week, there was sudden decrease in FB sensation in suture group following suture removal.

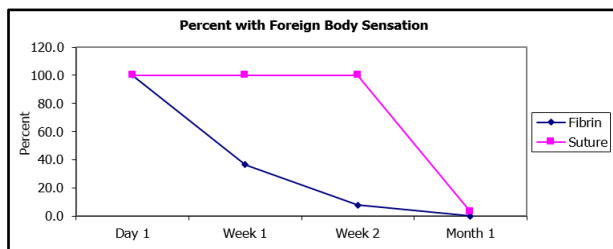


Figure 8. Analysis of Foreign Body Sensation between Fibrin and Suture Group During 1 Month Period of Follow-up

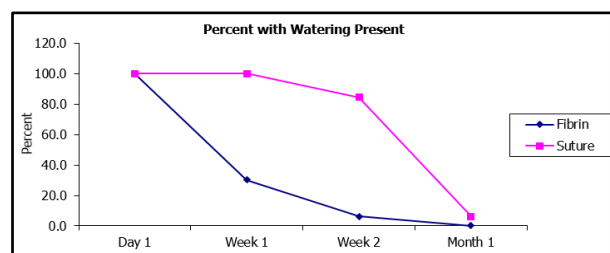


Figure 9. Analysis of Watering between Fibrin and Suture Group during 1 Month Period of Follow-up

Intensity of the watering was significantly low at 1st week and 2nd week postoperatively in patients treated with fibrin group. After 2nd week, there was sudden decrease in watering in suture group following suture removal.

Analysis of Postoperative Inflammation

Postoperative inflammation assessed by graft oedema and surrounding Conjunctival Congestion (CC) and Subconjunctival Haemorrhage (SCH).

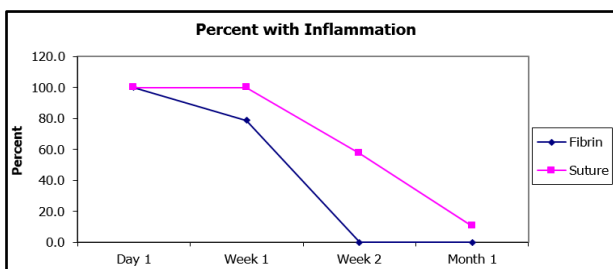


Figure 10. Analysis of Postoperative Inflammation between Fibrin and Suture Group during 1 Month Period of Follow-up

Signs of inflammation was significantly low at 1st week and 2nd week postoperatively in patients treated with fibrin group (p value <0.001).

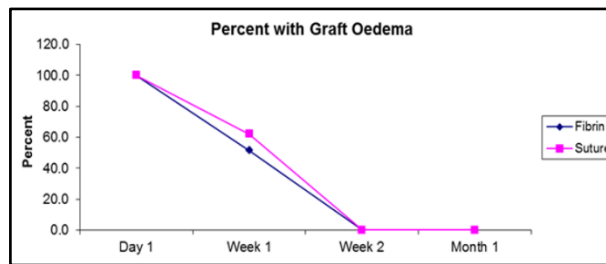


Figure 11. Analysis of Graft Oedema between Fibrin and Suture Group During 1 Month Period of Follow-up

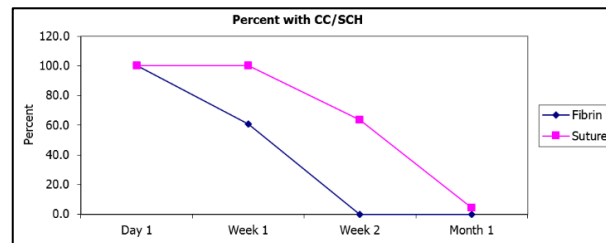


Figure 12. Analysis of Congestion and SCH between Fibrin and Suture Group During 1 Month Period of Follow up

On 1st postoperative day, all had graft oedema and conjunctival congestion with SCH. Both graft oedema and conjunctival congestion were significantly less among the fibrin group (p value <0.001).

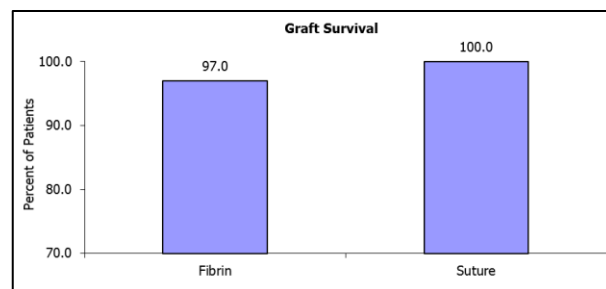


Figure 13. Analysis of Survival of Graft between 2 Groups

Two cases had graft failure in fibrin group, but none had failure in suture group.

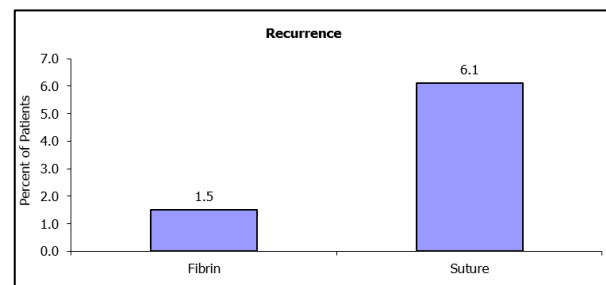


Figure 14. Analysis of Recurrence of Pterygium between 2 Groups

One eye (1.5%) showed graft recurrence in fibrin group at 4th month of follow up.

Four eyes (6.1%) had graft recurrence in suture group. Two eyes were shown recurrence at 4th month. The other 2 eyes had recurrence at 5th month and 6th month,

respectively. This showed no statistically significant difference between the two groups.

Analysis of Recurrence

Age Groups (Years)	Group		Total
	Fibrin	Suture	
18-30	0	0	0
31-40	1	2	3
41-50	0	1	1
51-60	0	0	0
61-70	0	0	0
71-80	0	0	0

Table 2. Age Distribution

Recurrence were common in the age group 31-40 years in both groups.

One recurrence was in the 41-50 years age group seen in the suture group.

Grade	Group		Total
	Fibrin	Suture	
Atrophic	0	0	0
Intermediate	0	1	1
Fleshy	1	3	4

Table 3. Grade of Pterygium

Recurrences were commonly seen with fleshy type of pterygium in both groups.

None of these associations showed statistical significance between the two groups.

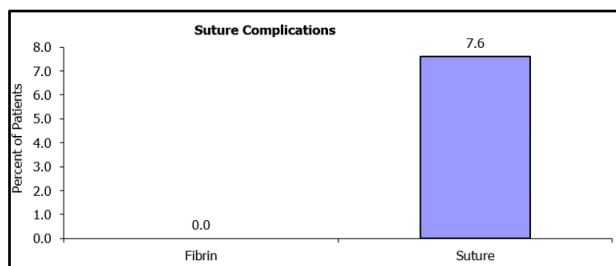


Figure 15. Analysis of Suture Complications

Two cases had suture granuloma and three cases had suture dehiscence. None of the cases had suture abscess or button holing.

No fibrin glue-related complications were seen in eyes using fibrin adhesive. Complications like giant papillary conjunctivitis, symblepharon, scleritis or peripheral ulcerative keratitis were not seen in either group.

DISCUSSION

In our study, 132 eyes of 132 patients, who underwent pterygium surgery during the study period were analysed. All the patients completed 9 months of follow up.

In our study, pterygium was more common in the age group, 41-50 years (34.1%). A decline in prevalence rate of pterygium was found in patients over 60-70 years.⁷ Of the 132 cases (132 eyes), 78 (59.1%) were females and 54 (40.9%) were males.⁸ No significant difference was found between the two groups with regard to sex or age distribution.

Although, exposure to UV light is suggested as one of the predisposing factor of recurrence of pterygium in our study, we could not get a statistically significant association between the two. But, pterygium was more prevalent among the outdoor workers.⁹

81 eyes (61.4%) had 2-4 mm extension onto the corneal surface. 12% eyes showed >4 mm extension into the cornea. In both groups, pterygium on nasal side of bulbar conjunctiva was most common. 97 cases (73.5%) had nasal pterygium.

Mean duration of surgery was 15.80 ± 1.56 minutes (range 12-20 minutes) in fibrin group compared to 36.17 ± 2.44 minutes in suture group (range 28-40 minutes). The operation was significantly shorter in the fibrin group than it was in the suture group (p value <0.001).⁶

The intensity of the postoperative complaints including pain, foreign body sensation and watering were significantly lower in patients treated with fibrin glue than the suture group at 1 week and 2 weeks postoperatively (p value <0.001). After the suture removal on day 14, most patients became asymptomatic. Subjective symptoms were a lot milder and were relieved more rapidly in the FG group. Patient satisfaction was significantly higher in the FG group than the suture group on 1st and 2nd week after the surgery.^{6,10}

Analysing the postoperative inflammatory response, the degree of inflammation was significantly less in the FG group at both 1 week and 2 weeks postoperatively (p value <0.001).^{11,12}

Graft oedema was more in the suture group on 1st week of follow up, but oedema spontaneously subsided in both groups after 1 week. Conjunctival congestion and subconjunctival haemorrhage were also more in the suture group on 1st and 2nd week compared to FG group (p value <0.001).

One eye (1.5%) showed graft recurrence in fibrin group, at 4th month of follow up. Four eyes (6.1%) had graft recurrence in suture group. Two eyes were shown recurrence at 4th month. The other two eyes had recurrence at 5th month and 6th month, respectively. Fleshy type of pterygium had more recurrence in both groups. None of these associations showed statistical significance between the two groups.⁹

The recurrences were closely followed up. Two cases in the suture group had undergone reoperation.

Two cases had suture granuloma and three cases had suture dehiscence. None of the cases had suture abscess or button holing. Among them, two cases of suture dehiscence later developed the graft recurrence. No fibrin glue related complications were seen in eyes with fibrin adhesive. Complications like giant papillary conjunctivitis, symblepharon, scleritis or peripheral ulcerative keratitis were not seen in either group.

According to the results of study, some advantages are obtained by using FB instead of 10-0 nylon sutures. First, surgery time was much shorter in fibrin group. This means, within the same time more pterygium surgeries can be accomplished and thus FG will be quite suitable for regions with a high incidence of pterygium. Second, the postoperative subjective symptoms and signs of inflammation were much less with FG. Third, with the use of FG, there is no need of

suture removal that entails considerable extra effort in time and additional pain for patients. Finally, unlike the tedious suturing process, the FG is very easy to use by any surgeon, experienced or a beginner.

CONCLUSION

- The duration of surgery for primary pterygium excision with conjunctival autograft was significantly shorter in the fibrin group than in the suture group.
- Postoperative discomfort was analysed in terms of pain, foreign body sensation and watering. The postoperative discomfort was significantly low in the fibrin glue group compared to other group.
- Signs of postoperative inflammation subsided earlier in the glue group, while they lasted longer in the suture group.
- Rate of recurrence was observed to be statistically insignificant between the two groups.

In conclusion, the use of fibrin glue for the attachment of conjunctival autografts in pterygium surgery is safe and effective in reducing patient discomfort and early postoperative complications. In our study, recurrence was found to be more in the suture group, though not statistically significant. On the whole, use of fibrin glue in pterygium excision significantly shortens the duration of surgery and therefore is seen to be a more rapid and efficient technique reducing the risk of infection at the same time saving valuable time for the surgeon. From the patient's standpoint, greater comfort allows faster return to their normal lifestyle and productivity.

REFERENCES

- [1] Coroneo MT. Pterygium as an early indicator of ultraviolet insolation: a hypothesis. *Br J Ophthalmol* 1993;77(11):734-739.
- [2] Hirst LW. Distribution, risk factors, and epidemiology of pterygium. In: Taylor R, ed. *Pterygium*. The Netherlands: Kugler Publications 2000:15-28.
- [3] Kenyon KR, Wagoner MD, Hettinger ME. Conjunctival autograft transplantation for advanced and recurrent pterygium. *Ophthalmology* 1985;92(11):1461-1470.
- [4] Schlag G, Aschler PW, Steinkogler FJ. Fibrin sealing in surgical and nonsurgical fields. Vol. 5. Berlin: Springer-Verlag 1994.
- [5] Lo KT, Lim-Bon-Siong R. Dehydrated human-amniotic-membrane allograft versus conjunctival autograft after pterygium excision. *Philipp J Ophthalmol* 2005;30(4):166-171.
- [6] Karalezli A, Kucukerdonmez C, Akova YA, et al. Fibrin glue versus sutures for conjunctival autografting in pterygium surgery: a prospective comparative study. *British J Ophthalmology* 2008;92:1161-1161.
- [7] Sivasubramaniam P. Pterygium in Ceylon. *Br J Ophthalmol* 1971;55(1):55-59.
- [8] Koranyi G, Seregard S, Kopp ED. The cut-and-paste method for primary pterygium surgery: long-term follow up. *Acta Ophthalmol Scand* 2005;83(3):298-301.
- [9] Fernandes M, Sangwan VS, Bansal AK, et al. Outcome of pterygium surgery: analysis over 14 years. *Eye* 2005;19(11):1182-1190.
- [10] Uy HS, Reyes JM, Flores JD, et al. Comparison of fibrin glue and sutures for attaching conjunctival autografts after pterygium excision. *Ophthalmology* 2005; 112(4):667-671.
- [11] Ti SE, Tseng SC. Management of primary and recurrent pterygium using amniotic membrane transplantation. *Curr Opin Ophthalmol* 2002;13(4):204-212.
- [12] Srinivasan S, Dollin M, McAllum P, et al. Fibrin glue versus sutures for attaching the conjunctival autograft in pterygium surgery: a prospective observer masked clinical trial. *Br J Ophthalmol* 2009;93(2):215-218.