

EWING'S SARCOMA OF THE CALCANEUM - RARE PRESENTATION

Banda Swathi Reddy¹, M. Lavanya², Kuchukulla Venkatram Reddy³, (Brig.) R. Sathyanarayana Moorthy⁴, Gaddam Ramakrishna Reddy⁵

¹Junior Resident, Department of Radiology, SVS Medical College and Hospital, Mahaboob Nagar, Telangana.

²Junior Resident, Department of Radiology, SVS Medical College and Hospital, Mahaboob Nagar, Telangana.

³Professor and HOD, Department of Radiology, SVS Medical College and Hospital, Mahaboob Nagar, Telangana.

⁴Professor, Department of Radiology, SVS Medical College and Hospital, Mahaboob Nagar, Telangana.

⁵Professor, Department of Radiology, SVS Medical College and Hospital, Mahaboob Nagar, Telangana.

HOW TO CITE THIS ARTICLE: Reddy BS, Lavanya M, Reddy KV, et al. Ewing's sarcoma of the calcaneum - rare presentation. J. Evid. Based Med. Healthc. 2018; 5(29), 2196-2198. DOI: 10.18410/jebmh/2018/454

CASE PRESENTATION

A 11-year-old girl came with painful swelling in region of the heel of foot on the left side for 1 month. Local examination revealed non-mobile, firm swelling of heel with tenderness.

The AP & lateral radiograph of the calcaneum showed a well-defined, expansile, osteolytic area with intact cortex & with adjacent soft tissue swelling. No calcification was detected.

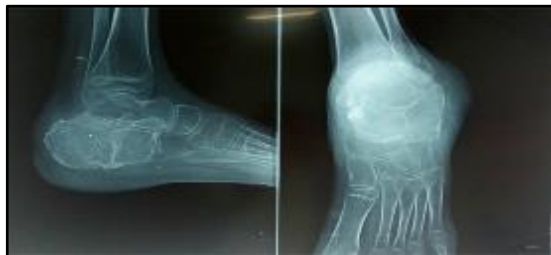

Figure 1. (A & B) Lateral and AP Radiograph of Left Ankle Joint

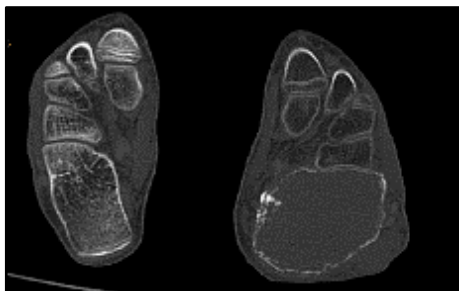


Figure 2

NCCT – Axial bone window images of both feet showing well defined heterogeneous soft tissue density mass lesion in left calcaneum showing bony expansion with few areas of

*Financial or Other, Competing Interest: None.
Submission 21-06-2018, Peer Review 23-06-2018,
Acceptance 09-07-2018, Published 16-07-2018.*

Corresponding Author:

Dr. B. Swathi Reddy,

Junior Resident,

*Department of Radiology,
SVS Medical College and Hospital,
Mahabubnagar, Telangana.*

E-mail: dr.swathi.banda@gmail.com

DOI: 10.18410/jebmh/2018/454



cortical destruction and adjacent muscle plane edema with subcutaneous fat plane obliteration noted.

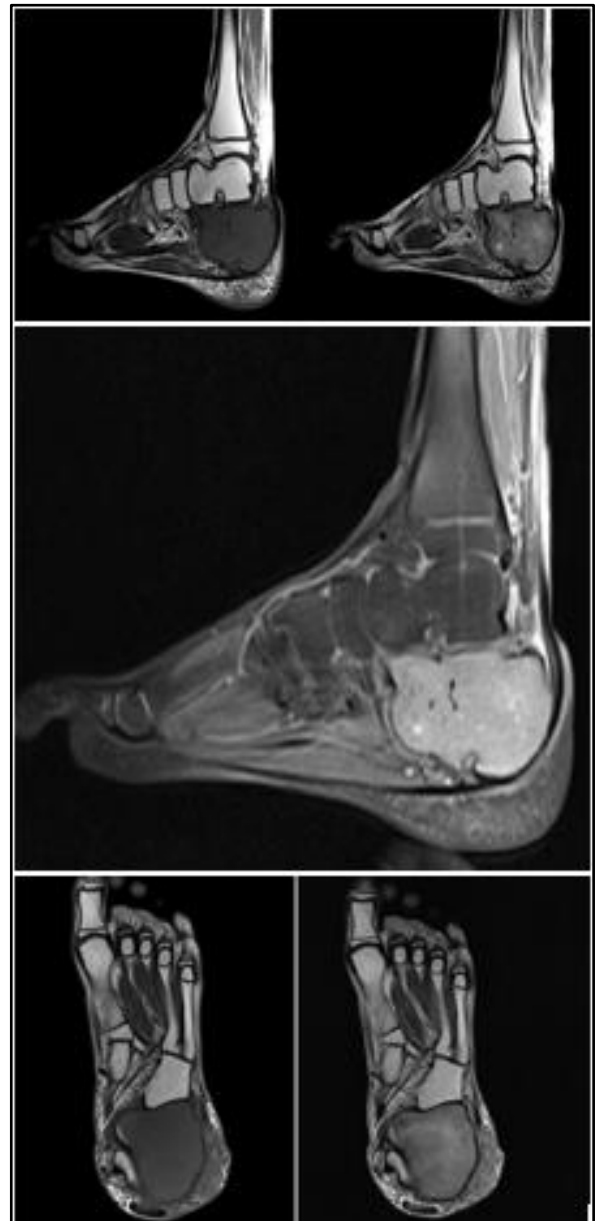


Figure 3

MRI

Mid sagittal images of left foot including ankle joint showing well defined heterogeneous intensity mass lesion within the calcaneum.

The lesion shows hypointense signal on T1 & heterogeneous signal on T2 & PD fat sat images. Altered signal intensity areas noted in surrounding muscle planes.

CLINICAL DIAGNOSIS

Ewing's sarcoma of calcaneum.

DIFFERENTIAL DIAGNOSIS

Aneurysmal Bone Cyst, Giant Cell Tumor.

PATHOLOGICAL DISCUSSION

Histopathology microscopy section showed a malignant round blue cell tumour. Tumor cells are predominantly round to oval with scanty vacuolated cytoplasm. Admixed with dark cells, pale cells also noted. Lymphovascular invasion noted. Mitotic figures seen. Peritheliomatous arrangement survival pattern is striking. Rosette formation also noted.

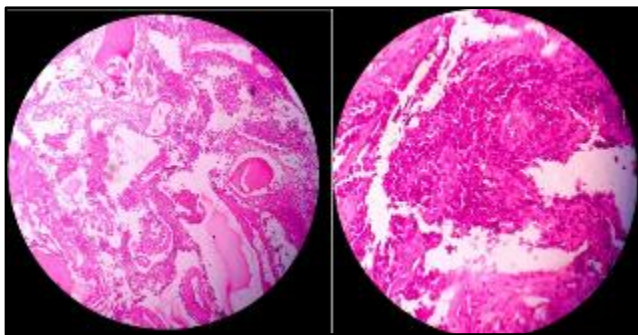


Figure 4

Final Impression: Ewing's Sarcoma/PNET (EWS/PNET)

DISCUSSION OF MANAGEMENT

James Ewing¹ described in 1921 a group of malignant pediatric bone tumours which he called diffuse endothelioma of bone, or endothelial myeloma. Ewing's sarcoma of bone represents the second most common primary malignant tumour of bone in children and adolescents. The most common primary bony sites include long bones, chest wall, pelvis and spine. However, it is responsible for only 3% to 5% cases in hands and feet.

Ewing's sarcoma found most commonly in 10 to 25 years age range peak at 15 years rare before age of 5 and after the age of 30 with a 2:1 male to female ratio, patients symptoms include localized pain² with swelling, slight to moderate fever, secondary anemia, leukocytosis & increased ESR are common in Ewing's sarcoma,³ Ewing's tumour to be only primary malignant tumour with symptoms simulating an infection. Ewing's sarcoma is a primary malignant bone lesion usually seen in diaphysis & less commonly seen in flat bones and rarely in small bones of hand and feet.

In long bones tumour is seen as poorly delineated diaphyseal lucency with moth eaten appearance surrounding periosteal reaction & soft tissue swelling.

The periosteal reaction can be spiculated, lamellated parallel with multiple layers of subperiosteal reactive new

bone produces an onion skin appearance.⁴ Cortical saucerization is an early and characteristic sign pathological fracture is noted in approximately 5% cases Ewing's sarcoma is composed of essentially small, round, undifferentiated tumour cells. The tumour cells are usually crowded together in sheets or segregated in lobules by fine fibrovascular septa. Ewing's sarcomas are usually vascular with frequent haemorrhagic areas and extensive necrosis.

Ewing's sarcoma is most common primary malignant bone tumor to metastasis to bone.⁵ The spine is a common site for metastasis multiple lesions in the one bone are described as skip lesions.⁶ secondary spread to lungs is also a common with lung parenchyma and pleura being favored location.

Ewing's sarcoma may involve small bones of hand and feet but calcaneum involvement is rare.

In Ewing's sarcoma imaging plays an important role in diagnosis. In Radiograph the lesion may be purely lytic with reactive new bone formation. The Ewing's sarcoma is often associated with lamellated or "Onion skin" appearance followed with "moth eaten" or mottled appearance and extension into soft tissue.

CT Scan is a good imaging modality to evaluate periosteal reaction, matrix lesion & joint extension.

Computerized tomography is useful for assessment of pulmonary involvement of metastasis and is therefore helpful and must be taken for tumour staging. In MRI the tumour has low signal intensity on T1 & hyperintense on T2 and on post contrast imaging is homogenous but vivid enhancement often contains large regions of decreased signal intensity tumour necrosis. Diffusion weighted MR may prove useful for evaluating the extent of tumour necrosis.

Bone scintigraphy shows increased uptake of radionuclide in foci of Ewing's sarcoma. Rarely, extraskeletal Ewing's sarcoma may develop in the soft tissues at anterior location. The most common sites of occurrence are the trunk, extremities and retroperitoneum, although it is a soft tissue primary tumour, it can cause changes in the cortex of adjacent bone. Extra skeletal Ewing's sarcoma is more common in adults and is associated with a high incidence of local recurrence and distant metastasis.

Radiation therapy in conjunction with effective chemotherapy in lesions detected early have increased survival rate.⁷ Amputation may still be used in lesions around the knee. The 5-year survival rate has been approximately 5% for Ewing's sarcoma. Early detection, adequate surgical resection, tumour size, metastasis and age are key prognostic indicators for determining the outcome of the disease process.⁸ In event of relapse, regardless of treatment used prognosis is fatal.⁹ Consolidation therapy to reduce chance of recurrence

FINAL DIAGNOSIS

Ewing's sarcoma of calcaneum.

REFERENCES

- [1] Ewing J. Diffuse endothelioma of bone. *Proc Pathol Soc* 1921;21:17-24.
- [2] Widhe B, Widhe T. Initial symptoms and clinical features in osteosarcoma and Ewing sarcoma. *J Bone Joint Surg Am* 2000;82(5):667-674.
- [3] Lichtenstein L, Jaffe HL. Ewing's sarcoma of bone. *Am J Pathol* 1947;23(1):43-77.
- [4] Wilner D. *Radiology of bone tumors and allied disorders*. Philadelphia: WB Saunders 1982.
- [5] Telles NC, Rabson AS, Pomeroy TC. Ewing's sarcoma: an autopsy study. *Cancer* 1978;41(6):2321-2329.
- [6] Sundaram M, Merenda G, McGuire MM. A skip lesion in association with Ewing sarcoma. Report of a case. *J Bone Joint Surg* 1989;71(5):764-768.
- [7] Hoffmann C, Ahrens S, Dunst J, et al. Pelvic Ewing sarcoma: a retrospective analysis of 241 cases. *Cancer* 1999;85(4):869-877.
- [8] Shankar AG, Ashley S, Craft AW, et al. Outcome after relapse in an unselected cohort of children and adolescents with Ewing sarcoma. *Med Pediatr Oncol* 2003;40(3):141-147.
- [9] Dwyer AJ, Glaubiger DL, Ecker JG, et al. The radiographic follow-up of patients with Ewing sarcoma: a demonstration of a general method. *Radiology* 1982;145(2):327-331.