

EVIDENCE BASED INCIDENCE OF TUBAL FACTOR IN SECONDARY INFERTILITY AS DETECTED BY HYSTEOSALPINGOGRAPHY IN WESTERN MAHARASHTRA

Anil Joshi¹, Rajani Joshi²

¹Professor & HOD, Department of Radiology, B. V. D. V. Medical College & Hospital, Sangli.

²Professor & HOD, Department of Anatomy, R. C. S. M. G. M. C, Kolhapur.

ABSTRACT

BACKGROUND

It is documented that 15% of all women experience primary or secondary infertility at one point in time in their reproductive life. Tubal causes of infertility account for 35 to 40% of causes of infertility. HSG is still a commonly used investigation in the evaluation of the female genital tract and the main indication for the HSG is infertility.

AIMS

- To find out incidence of tubal factor in secondary infertility in Western Maharashtra population.
- To establish reliability of Hysterosalpingography in evaluating tubal status.

MATERIALS AND METHOD

A retrospective study of 464 hysterosalpingographies of women having secondary infertility was done over period of two years. The patients having tubal defects were further studied and statistically analysed. Statistical analysis was performed with the SPSS computer software, version 17.0. Results were presented in tables and graphs.

RESULTS

- Hysterosalpingography has proved to be an ideal (or 'gold standard') test to detect tubal abnormalities in infertile women.
- The commonest structural cause of infertility in Western Maharashtra as per this study was bilateral tubal blockage and was commoner in patients with secondary infertility.

CONCLUSIONS

Evaluation of tubal patency and tubal integrity is a key component of the diagnostic work-up in infertile couples.

In conclusion, bilateral tubal occlusion remains the major tubal pathology in female infertility in Western Maharashtra. Tubal blockages with subsequent tubal factor infertility are still common among infertile couples. This may probably be due to chronic pelvic inflammatory disease or pelvic infection following sexually transmitted infections, mismanaged pregnancies and septic abortions, since the majority of the women presented with secondary infertility. Measures to prevent the occurrence of these infections should be paramount.

KEYWORDS

Hysterosalpingography, Secondary Infertility, Tubal Defect, Tubal Occlusion.

HOW TO CITE THIS ARTICLE: Joshi A, Joshi R. Evidence based incidence of tubal factor in secondary infertility as detected by hysterosalpingography in western Maharashtra. J. Evid. Based Med. Healthc. 2016; 3(43), 2125-2130.

DOI: 10.18410/jebmh/2016/472

INTRODUCTION: Primary infertility is defined as the inability of a couple to achieve pregnancy within a period not less than a year of adequate unprotected intercourse.¹ The secondary infertility refers to those who have conceived sometime in the past regardless of whether the pregnancy ended in abortion.

According to Farhi j. et al common causes of infertility include male factor (45%), hormonal imbalances (39 %) and tubal damage (18%).² Tubal diseases include tubal obstruction, narrowing, dilatation as well as conditions that

alter tubal function due to changes in the tubal mucosal lining or its muscular wall. Tubal disease with blockage can involve the proximal (cornual) part, the mid part or the distal part. Peritubal adhesions due to infection, inflammation, tuberculosis, endometriosis, previous surgeries and ectopic pregnancy are common factors in tubal subfertility and need to be assessed.

Imaging plays an important role in the diagnostic workup for infertility. Hysterosalpingography (HSG) is still the most commonly used imaging modality to evaluate tubal patency and tubal integrity.³ HSG is basically the radiographic evaluation of uterine cavity and fallopian tubes by administering radio-opaque contrast medium into them. It is a safe, relatively inexpensive, easily available, simple and rapid diagnostic test. By HSG, along with tubal patency and pathology, uterine pathologies like submucous fibroid, endometrial polyp, intrauterine synechiae, congenital

Financial or Other, Competing Interest: None.
Submission 17-05-2016, Peer Review 20-05-2016,
Acceptance 24-05-2016, Published 27-05-2016.

Corresponding Author:

Dr. Anil Joshi,

#1576, Ganesh Nagar, Opp. Civil Hospital,
Sangli, Maharashtra.

E-mail: draniljoshi@gmail.com

DOI: 10.18410/jebmh/2016/472

malformations of uterus and cervical stenosis can also be detected.

Our aim of this study was to find out incidence of tubal factor causing secondary infertility in Western Maharashtra population as detected by HSG. The study therefore concentrates only on tubal factor and exclude uterine causes and hormonal (ovarian) factor. Tubal factor infertility is female infertility caused by diseases, obstruction, damage, scarring, congenital malformations or other factors which impede the descent of a fertilised or unfertilised ovum into the uterus through the fallopian tubes and prevents a normal pregnancy and full-term birth.

MATERIALS AND METHOD: The present study was carried out with due consent from the hospital's ethical committee. Hysterosalpingography is a fluoroscopic study performed by instilling radiopaque dye into the uterine cavity via a cannula to determine contour of the uterine cavity and patency of the fallopian tubes. It is a less invasive, reliable and the most commonly used first line of investigation in the evaluation of the female genital tract in infertility.

Contraindications for the procedure are menstruation and pregnancy. Other contraindications include current pelvic infection, a recent dilatation and curettage, endometrial carcinoma, a history of kidney problem (as the dye used during HSG can cause kidney damage in people with poor kidney function) or sensitivity to contrast media, or patient has asthma or allergic tendency to any medicines. In the present study, all these contraindications were ruled out before performing HSG by taking detailed history of patient.

Between the April 2014 to April 2016, 860 patients were investigated for sterility and their HSG studies were performed at Bharati Vidyapeeth Deemed University's Hospital and at Dhwanikiran Diagnostic Centre, Sangli. In the present study, we have done retrospective study of 860 hysterosalpingograms. The couples having primary infertility were excluded. The semen analysis of all male partner's causing infertility was done and couples with male factor (i.e. pathological semen reports) were also excluded from the study. The HSG showing tubal occlusion or tubal anomalies were included in the present study.

At both the centres, following technique was used to perform hysterosalpingography.

All patients were given prior appointments for HSG examinations; as procedure was performed during 7th – 12th day of menstrual cycle (day 1 being first day of menstrual bleeding). The endometrium is thin during this proliferative phase, a fact that facilitates image interpretation and should also ensure that there is no pregnancy. This procedure was performed on OPD basis and no specific patient preparation is required for HSG. HSG does not require surgical skill and can be done in district hospital where x-ray facilities are available. It does not require anaesthesia.

The procedure is done before patient ovulates the next month to avoid using x-rays during early pregnancy. An informed consent was obtained from all patients where in patient was explained in detail about this procedure, a little pain factor during procedure, after effects and after care and

benefits of HSG over few negligible side effects. Thereafter patient's acceptance of this procedure was good.

Method: The patient was asked to take light lunch 2-3 hours before the procedure. Premedication given was injection atropine and ½ cc of contrast media as test dose about 20 minutes before procedure. Sometimes patients may have cramping pain during HSG. To avoid this, patients were given analgesic drug one hour prior to the procedure. The patient was instructed to empty her bladder before HSG.

The patient was placed in supine position on fluoroscopy table in the modified lithotomy position i.e. patient was placed at the foot end of table and asked to flex her knees on abdomen and hold them with her hands. The perineum was cleaned with antiseptic solution. The patient was clinically examined to determine position of uterus and to make sure that there was no pelvic infection.

The whole amount of the injected contrast agent was not more than 10 cc.

With the help of Vulsellum and vaginal wall retractor, cervix was identified and held with the help of a tenaculum (as we found it less traumatic than Vulsellum). Again, cervix and adjacent fornices were cleaned by antiseptic solutions. Approximately, 3-4 cc of contrast agent (nonionic Omnipaque 300) was introduced with the help of a cannula into the uterus and its passage was observed under the fluoroscopy. Acute anteversion or retroversion was corrected as far as possible by retracting cervix. Then, first film was obtained on visualisation of the uterine cavity. The second film was taken after tubal passage of contrast media and its peritoneal spillage into abdominal cavity or after completion of introduction of 10 cc of contrast agent. The films were processed on CR system and analysed with the help of different modalities on computer software including magnification and window setting. Documentation was made and the findings were analysed.

Post-procedural management: - The patient was kept strictly in supine position for 30-40 min. and her pulse and blood pressure were monitored for every 5-10 min. up to ½ hour to ensure that she does not have allergic reaction due to contrast. As a routine, patient was given nonsteroidal anti-inflammatory and analgesic tablet, two more doses to be repeated every 4 hours. Also, patient was advised 5 days antibiotics. We asked patient to report immediately if she feels giddy, develops skin rashes or asthmatic attacks.

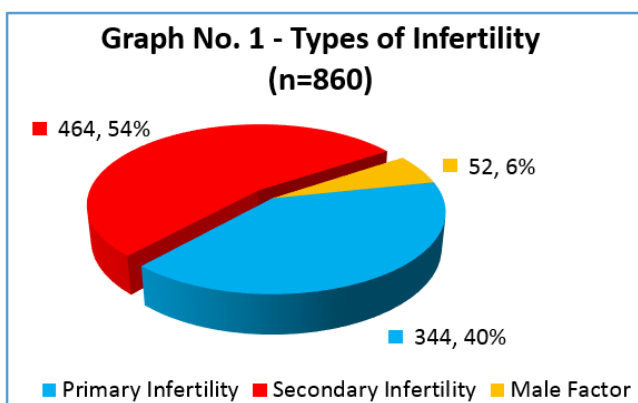
Complications of HSG: - The most common complications are bleeding & infection. The patient was made aware that she may experience light per vaginal spotting after the procedure, usually lasting less than 24 hours. The risk of infection was minimised by us due to exclusive use of sterile instruments. The patients were instructed to watch for the development of fever or foul – smelling vaginal discharge over 2-4 days following HSG and if so, report immediately.

The extremely rare complication is a reaction to the contrast media. Such a reaction is very uncommon with the non-ionic contrast agent which we are using presently. The perforation of uterus or fallopian tubes is another extremely infrequent complication which has never occurred at our centres.

OBSERVATIONS AND RESULTS: A retrospective study of 860 cases of infertility between April 2014 to April 2016 was done. Out of that, 344 cases having primary sterility and 52 cases having male factor infertility were excluded from the present study. The percentage of patients having secondary infertility was 54% which was more than patients having primary infertility (40 %). In present study, 6% of couples were having male factor infertility. This frequency of infertility is tabulated in table no. 1 and same is graphically shown in the graph no. 1.

History	Frequency	Percentage (%)
Primary Infertility	344	40 %
Secondary Infertility	464	54 %
Male Factor	52	6 %

Table 1: Distribution of Patient's History (Total No. of Patients n = 860)



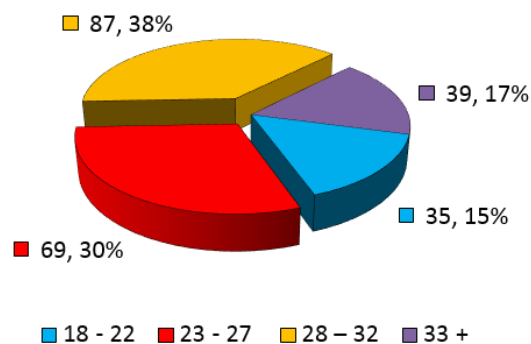
In all the 464 HSG investigations in this study, the procedure was tolerated well with no post-procedural complications noted, except mild pain and slight per-vaginal bleeding in a minority of patients.

The patients with secondary infertility were between age of 18 to 33+ years with maximum percentage of cases i.e. 68% belonged to age group 23 to 32 years; as shown in table no. 2 and graph no. 2.

Age group (years)	No. of pts. with secondary infertility	Percentage
18 - 22	35	15%
23 - 27	69	30%
28 - 32	87	38%
33 +	39	19%

Table 2: Age Distribution of the Patients with Secondary Infertility (n = 230)

Graph No. 2 - Age distribution of the patients with secondary infertility (n=230)



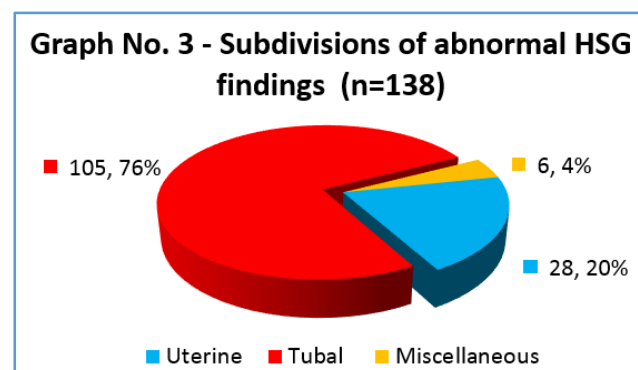
Total 138 patients HSG were showing abnormal findings, out of that, 27 patients (20 %) demonstrated uterine causes, such as congenital uterine abnormalities (unicornuate uterus, bicornuate uterus, hypoplastic uterus etc.), uterine polyps, uterine folds etc. which were excluded from this study. In 6 patients (4 %), other causes such as hormonal imbalances, cervical canal stenosis, and ectopic ovaries were observed which were not included in present study.

Total 105(76%) cases demonstrated tubal defects which were included in the present study.

This subdivisions of abnormal HSG findings were tabulated in table no. 3 and showed graphically in graph no. 3.

Factors	No. of pts. with secondary infertility	Percentage
Uterine	27	20%
Tubal	105	76%
Miscellaneous	6	4%

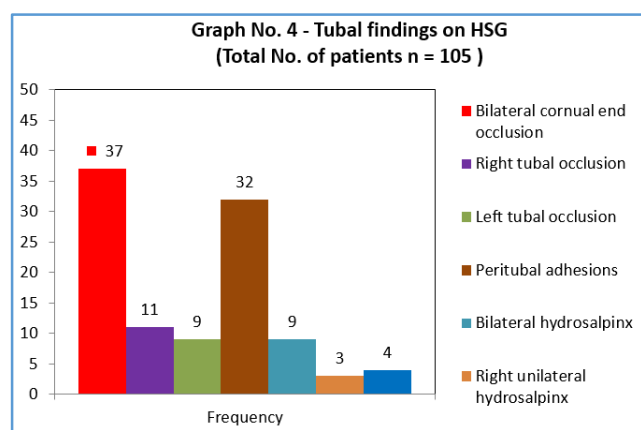
Table 3: Subdivisions of Abnormal HSG Findings (Total No. of patients n = 138)



The HSG showing tubal defects were interpreted by experienced radiologists and were categorised in following table no. 4. They were statistically analysed and were represented graphically in graph no. 4.

Tubal findings	Frequency	Percentage
Bilateral cornual end occlusion	37	35%
Right tubal occlusion	11	10%
Left tubal occlusion	9	9%
Peritubal adhesions	32	30%
Bilateral hydrosalpinx	9	9%
Right unilateral hydrosalpinx	3	3%
Left unilateral hydrosalpinx	4	4%

Table 4: Tubal Findings on HSG (Total No. of patients n = 105)



Accordingly, bilateral cornual end occlusion was most commonly observed tubal defect in 37 cases (35 %) while right tubal occlusion was seen in 11(10%) cases and left tubal occlusion was found in 9(9%) cases. The next common defect found was peritubal adhesions 12(36%) in 32 cases. The bilateral and unilateral hydrosalpinx was found in 16 % of cases.

Out of 464 hysterosalpingograms included in the present study, 326 were normal studies

* While 105 patients (i.e. 76 %) demonstrated tubal defects.

DISCUSSION: Infertility is an important clinico-social issue in Western Maharashtra. Hysterosalpingography is still the most commonly advised and performed first diagnostic test in cases of infertility. HSG is relatively easy to perform, low cost, well accepted well tolerated by the patients and can be done as an outpatient procedure. HSG is fast technique and fluoroscopic time can be reduced up to two minutes.⁴ Since the test films are available for interpretation opinion is always possible for comparison which excludes subjective error in interpretation. By enlarge HSG is considered as the best imaging modality and evaluating the fallopian tubes and their patency.⁵

There was higher percentage of secondary infertility compared to primary infertility in previous studies and this is in harmony with the present study.^{6,7,8,9}

In the present study, maximum number of infertile patients belonged to the age group of 23 to 32 years (68%); which was comparable with the study done by Malwadde et al and Dutta et al.^{10,11}

In the present study, tubal defects were seen in 76% of cases which is comparable with the study done by K Sood et al. He reported¹² tubal defects in 60.53% of secondary infertility cases. In a similar study done by T Radha Bhai Prabhu et al,¹³ tubal defect was reported in 34.6% of secondary subfertility cases, its value is less than present study.

Since Lash et al¹⁴ had previously (in 2008) established an association between secondary infertility and fallopian tube occlusion, these results of our study further stress the fact that infection may have been a major underlying cause of infertility among the population studied.

The post abortion sepsis and puerperal sepsis lead to tubal defects. This could be because of unavailability or inaccessibility of medical facilities so that many women deliver under poor sanitary conditions or have unsafe abortions and poorly managed spontaneous abortions. Tubal defect can be due to infection mainly due to tuberculosis and sexually transmitted diseases. Previous pelvic surgeries and uterine manipulations such as D & C or pitting an IUCD can damage the tubes. Salpingitis Isthmica Nodosa and cornual polyp are rare causes of tubal defect. Pelvic inflammatory disease (PID) is a major clinically unsuspected reason for tubal subinfertility. PID can damage the tube at multiple sites and also predispose to ectopic pregnancy.

Tubal block which typically prevents successful passage of an egg to the sperm, or fertilised egg to the uterus, and manifests on HSG as an abrupt cut-off of contrast material with non-pacification of the more distal fallopian tube, was found to be main structural cause of infertility in women per HSG findings in Western Maharashtra. The hysterosalpingography has both therapeutic and diagnostic value. Following HSG, certain minor/mild uterine adhesions and partial tubal occlusions are lysed as well as improves patency of fallopian tubes because of flushing of tubes by contrast media¹⁵ during examination. As a result, infertile women have conceived months after HSG without any other gynaecological intervention. Interestingly, an increase in pregnancy rate has been observed in the months after HSG.

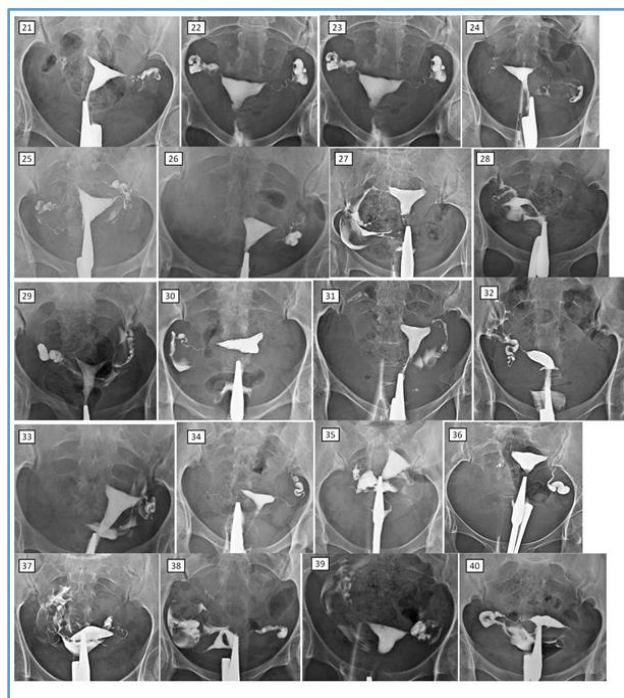
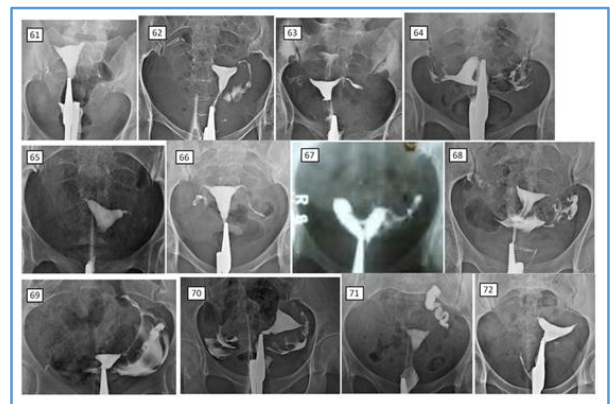
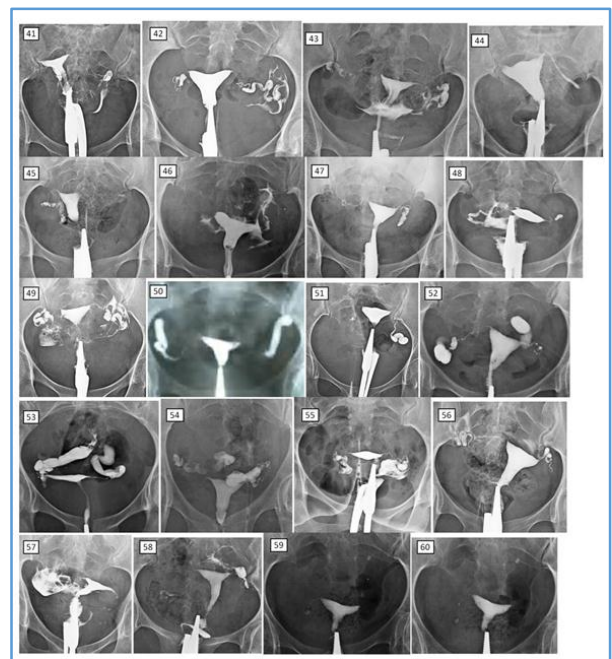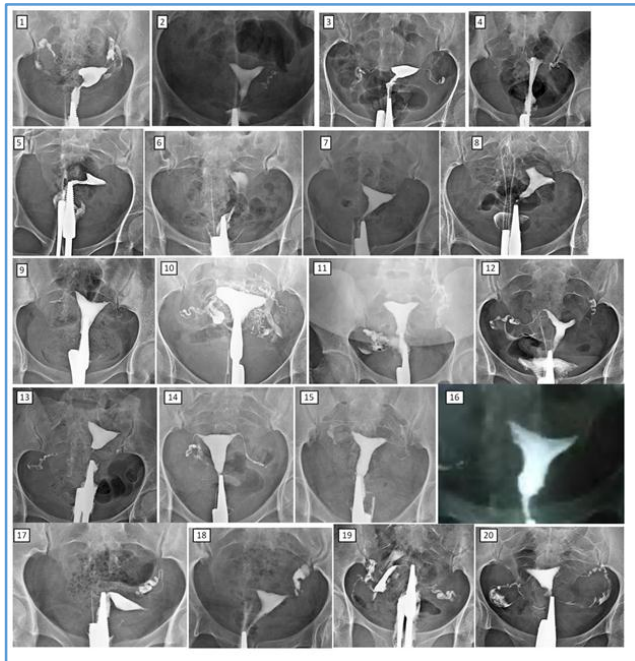
Characteristics of normal HSG – Patency with free spill, preserved distal tubal folds, normal proximal, mid, distal tubal dimensions and appearance, no fimbrial end clumping, no detected peritubal disease, normal tubal pressures with free flow, lack of sharp pain on forceful flushing.

Characteristics of sever tubal disease – Patent or blocked tubes, loss of distal tubal folds, altered proximal, mid, distal tubal dimensions and appearance with dilatation/narrowing/scarring/tubal rigidity, fimbrial end dilatation/narrowing with clumping present, peritubal disease may or may not be seen, usually elevated tubal pressures, but can be normal.

CONCLUSIONS: Hysterosalpingography is a very effective technique to assess the tubal status. HSG still plays a significant role in the detection of tubal causes of female infertility. As per this study, the bilateral tubal blockage was the commonest structural cause of infertility in Western Maharashtra and was common in patients with secondary

infertility, in the age group of 23 to 32 years. As majority of the women presented with secondary infertility, the tubal blockage in them may probably be due to chronic pelvic inflammatory disease or pelvic infections, mismanaged pregnancies and septic abortions. Primary prevention of reproductive tract infections is therefore very vital in reducing incidence of infertility.

IMAGES:



All different patients. Description of findings:

1. Rt. peritubal adhesions/bilateral terminal hydrosalpinx.
2. Rt. cornual end block/Lt. fimbrial end block.
3. Bilateral terminal end block.
4. Rt. cornual end block/Lt. terminal end block
5. Bilateral cornual end block
6. Bilateral cornual end block – scarred endometrium -? chronic inflammation
7. Bilateral cornual end block –
8. Bilateral cornual end block with multiple small subserosal fibroids.
9. Bilateral mid segment block
10. Bilateral cornual end block with venous uptake/intravasation.
11. Rt. peritubal adhesions, Lt. cornual end block.
12. Rt. tube normal/lit. showing terminal block
13. Rt. terminal & Lt. mid segment block
14. Rt. fimbrial end block/lit. mid segment block.
15. Bilateral terminal end block.
16. Rt. terminal/lit. cornual block/irregular endometrium s/o chronic inflammation
17. Rt. cornual, Lt. fimbrial block.
18. Rt. midsegment block/lit. terminal hydrosalpinx,

19. Bilateral peritubal adhesions.
20. Bilateral entire length subtotal scarring.
21. Bilateral fimbrial end block
22. Bilateral hydrosalpinx
23. Bilateral hydrosalpinx – delayed film showing cervical canal stenosis.
24. Bilateral fimbrial end block.
25. Bilateral fimbrial end scarring with partial block.
26. Rt. mid segment block/lit. terminal hydrosalpinx.
27. Rt. side fimbrial scarring/lit. mid segment block.
28. Rt. tube normal/lit. cornual end block.
29. Bilateral terminal scarring, with peritubal; adhesions.
30. Rt. terminal hydrosalpinx/lit. cornual block.
31. Rt. cornual end block/lit. partial scarring.
32. Rt. tube normal/lit. cornual block.
33. Rt. cornual end block/lit. peritubal adhesions.
34. Rt. distal end block/lit. fimbrial end block.
35. Bilateral terminal hydrosalpinx.
36. Rt. mid segment block/lit. terminal hydrosalpinx.
37. Rt. tube normal/lit. terminal hydrosalpinx.
38. Bilateral terminal hydrosalpinx. Rt. patent/lit. is blocked.
39. Lt. peritubal adhesions. Rt. tube is normal.
40. Rt. terminal hydrosalpinx/lit. cornual block.
41. Rt. cornual end block/lit. terminal hydrosalpinx.
42. Rt. terminal block/lit. tube is normal.
43. Bilateral peritubal adhesions – rt. block/lit. normal.
44. Rt. cornual end block/lit. mid segment block.
45. Rt. fimbrial end block/lit. cornual end block.
46. Rt. cornual end block/lit. tube is normal.
47. Bilateral distal end block – lit. hydrosalpinx.
48. Rt. tube normal/lit. distal block.
49. Bilateral terminal; hydrosalpinx/peritubal adhesions.
50. Bilateral terminal hydrosalpinx
51. Rt. mid segment block/lit. terminal hydrosalpinx.
52. Bilateral terminal hydrosalpinx.
53. Bilateral terminal hydrosalpinx.
54. Bilateral terminal hydrosalpinx,
55. Bilateral terminal hydrosalpinx, rt. block/lit. partially patent.
56. Bilateral terminal hydrosalpinx, both partially patent.
57. Rt. tube normal/lit. cornual end block.
58. Rt. fimbrial end block/lit. terminal hydrosalpinx.
59. Bilateral mid segment block – post t. l.
60. Bilateral mid segment block – post t. l.
61. Rt. cornual end block/lit. mid segment.
62. Bilateral terminal block
63. Bilateral distal end block.
64. Rt. cornual block/lit. normal
65. Bilateral cornual end block.
66. Bilateral mid segment block
67. Bicornuate uterus with rt. cornual end block/lit. patent
68. Rt. fimbrial end block/lit. peritubal adhesions.
69. Rt. cornual end block/lit. terminal hydrosalpinx - patent.
70. Bilateral peritubal adhesions.
71. Rt. cornual block/lit. terminal hydrosalpinx.
72. Bilateral cornual end block.

REFERENCES

1. Williams C, Giannopoulos T, Sherriff EA. Investigation of infertility with emphasis on laboratory testing and with reference to radiological imaging. *J Clin Pathol* 2003;56:261-267.
2. Farhi J, Ben-Haroush A. Distribution of causes of infertility in patients attending primary fertility clinics in Israel. *Isr Med Assoc J* 2011;13(1):51-55.
3. Lim CP, Hasata Z, Bhattacharya S, et al. Should hysterosalpingogram be a first-line investigation to diagnose female tubal subfertility in the modern subfertility workup? *Hum Reprod* 2011;26(5):967-971.
4. Sanfilippo JS, Yussman MA, Smith O. Hysterosalpingography in the evaluation of infertility: a six-year review. *Fertil Steril* 1978;30(6):636-643.
5. Akinola RA, Akinola OI, Fabamwo AO. Infertility in women: Hysterosalpingographic assessment of the fallopian tubes in Lagos, Nigeria. *Educ Res Rev* 2009;4(3):86-89.
6. Agwuna KK, Anyawu GE. Anatomical defects at HSG in Patients with infertility. *Journal of Experimental and Clinical Anatomy* 2006;5(2):7-12.
7. Asaley CM, Adetiloye VA, Oyinola TO. Review of HSG reports done for fertility. *Nigerian Journal of Health Sciences* 2004;4:36-39.
8. Dhaliwal LK, Gupta KR, Aggarwal N. Is HSG an important tool in modern gynaecological practice. *International Journal of Fertile Women* 1999;44(4):212-215.
9. Mgbor SO. Patten of hysterosalpingography (HSG) findings in gynaecology patients in Enugu. *Nigeria Journal* 47:14-16.
10. Malwadde EK, Byanyima RK. Structural findings at hysterosalpingography in patients with infertility at two private clinics in Kampala, Uganda. *African Health Sciences* 2004;4(3):178-181.
11. Dutta S, Guha R. A clinico-anatomical study on the common etiological factors pertaining to primary infertility in females using some common investigative procedures. *J Anat Soc India* 2007;56(2):14-17.
12. Sood K, Malan R. Analysis of 300 diagnostic laparoscopy. *Indian Journal of Obs & Gynae* 1987;37:156-160.
13. Radha Bhai Prabhu T, Raman Shivraman. Diagnostic Laparoscopy: a review of 800 cases. *Indian Journal of Obs & Gynae* 1988;38(2):205-207.
14. Lash MM, Yaghamee A, Strohsnitter W, et al. Association between secondary infertility and fallopian tube obstruction on hysterosalpingography. *J Reprod Med* 2008;53(9):677-680.
15. Johnson N, Vandekerckhove P, Watson A, et al. Tubal flushing for subfertility. *Cochrane Database Syst Rev* 2002;(3):CD003718.