

## EVALUATION OF HEPATOBILIARY DISEASES USING MAGNETIC RESONANCE CHOLANGIOPANCREATOGRAPHY FEATURES

Reena Mathur<sup>1</sup>, Avinash Gupta<sup>2</sup>, Kalpana Manra<sup>3</sup>, Prama Dubey<sup>4</sup>, Devraj Yadav<sup>5</sup>, Shashi Meena<sup>6</sup>

<sup>1</sup>Senior Professor and HOD, Department of Radio-diagnosis, Jawahar Lal Nehru Medical College and Hospital, Ajmer, Rajasthan.

<sup>2</sup>Professor, Department of Radiodiagnosis, Jawahar Lal Nehru Medical College and Hospital, Ajmer, Rajasthan.

<sup>3</sup>Resident Doctor, Department of Radiodiagnosis, Jawahar Lal Nehru Medical College and Hospital, Ajmer, Rajasthan.

<sup>4</sup>Resident Doctor, Department of Radiodiagnosis, Jawahar Lal Nehru Medical College and Hospital, Ajmer, Rajasthan.

<sup>5</sup>Resident Doctor, Department of Radiodiagnosis, Jawahar Lal Nehru Medical College and Hospital, Ajmer, Rajasthan.

<sup>6</sup>Resident Doctor, Department of Radiodiagnosis, Jawahar Lal Nehru Medical College and Hospital, Ajmer, Rajasthan.

### ABSTRACT

#### BACKGROUND

Hepatobiliary system diseases are a common pathology encountered in clinical practice. Ultrasound, Computed Tomography (CT), and Endoscopic Retrograde Cholangiopancreatography (ERCP) and Magnetic Resonance Cholangiopancreatography (MRCP) are the commonly used imaging modalities to evaluate the same. MRCP provides high resolution projection images of the biliary tree and pancreatic duct without being invasive. We wanted to evaluate MRCP appearance of various hepatobiliary lesions and identify the aetiology of benign and malignant strictures.

#### METHODS

This is a descriptive study. The study group consisted of 108 patients diagnosed or suspected of having hepatobiliary lesions referred for MRI.

#### RESULTS

Malignant stricture of the bile duct was the most common pathology in this study comprising 35 patients followed by benign strictures comprising 27 patients. A total of 30 patients of choledochal cyst was seen, the most common being type 1 Choledochal cyst. 18 patients of choledocholithiasis were seen. A total of 27 patients of benign stricture were seen. Iatrogenic injury was the most common cause of the bile duct stricture followed by stricture associated with chronic pancreatitis in 2 patients. There were 35 patients of malignant stricture in this study. Most common cause of malignant stricture was cholangiocarcinoma. MRCP examination in patients of hepaticojejunostomy with operative site stricture showed stricture at the site of anastomoses. In these patients ERCP was not possible due to unfavourable anatomy. MRCP shows ductal dilatation proximal to stricture in patients of hilar cholangiocarcinoma which was not possible on ERCP in these two patients due to tight stricture. MRCP examined bile duct in physiological state without the problem of the overestimation of the size of the bile ducts.

#### CONCLUSIONS

MRCP does not involve ionising radiation, contrast media and is totally non-invasive. Malignant stricture comprises commonest disease, followed by benign stricture of bile duct and choledochal cysts. MRCP is of advantage when distal CBD calculi are obscured by gas on USG. Iatrogenic injury is the most common cause of the benign bile duct stricture.

**HOW TO CITE THIS ARTICLE:** Mathur R, Gupta A, Manra K, et al. Evaluation of hepatobiliary diseases using magnetic resonance cholangiopancreatography features. J. Evid. Based Med. Healthc. 2019; 6(14), 1113-1121. DOI: 10.18410/jebmh/2019/233

#### BACKGROUND

Hepatobiliary system diseases are a common pathology encountered in clinical practice. Ultrasound is the first method of choice or screening procedure of choice when such disease is suspected. Today sonography remains the modality of choice for the detection of gallstones,

*Financial or Other, Competing Interest: None.*

*Submission 11-03-2019, Peer Review 14-03-2019,*

*Acceptance 28-03-2019, Published 02-04-2019.*

*Corresponding Author:*

*Dr. Avinash Gupta,*

*Professor, Department of Radiodiagnosis,*

*Jawahar Lal Nehru Medical College and Hospital,*

*Ajmer, Rajasthan.*

*E-mail: dravinash23porwal@gmail.com*

*DOI: 10.18410/jebmh/2019/233*



assessment of acute right upper quadrant pain and for the initial evaluation of the patients with jaundice. Computed tomography (CT) can be used to image the hepatobiliary system, with perhaps the exception of the gallbladder, which is better imaged with ultrasound. Endoscopic Retrograde Cholangio Pancreatography is an invasive imaging modality which provides high resolution images of the pancreatic duct and biliary tree and has the added advantage of the ability to perform interventional procedures. In view of the limitations of sonography/CT scan, the invasiveness and complications of ERCP, there is need for an imaging modality which is non-invasive and provides high resolution projection images of the biliary tree and pancreatic duct. For these reasons MRCP was developed and is now assuming the position of the modality of choice in evaluation of the biliary tree after initial USG.

**Normal MRCP Appearance of Hepatobiliary**

**Apparatus**

The cystic duct joins the common hepatic duct to form common bile duct. This union occurs at varying levels, from high in the porta hepatis to near ampulla of Vater.

On MRCP bile duct is classified as proximal (intrahepatic and hilar), mid (supra-pancreatic) or distal duct (pancreatic and ampullary).<sup>1</sup>

Hepatic duct dilatation is diagnosed if prominent second order hepatic ducts are seen extending to the periphery of the liver. Extrahepatic bile duct is considered to be normal up to 7 mm in diameter, in patients with intact gallbladders. The CBD may measure up to 10 mm without obstruction in post cholecystectomy patients and some older adults. The wall of the CHD and CBD can normally be demonstrated and measures less than 1.5 mm.<sup>2</sup>

The CBD enters the pancreas and typically lies along the posterior and lateral aspect of the pancreatic head. The distal CBD and main pancreatic duct pass separately through the wall of the duodenum and unite to form a short-dilated tube-the ampulla of Vater. The sphincter of Oddi is the circular muscle complex around the CBD, pancreatic duct and ampulla of Vater.

On axial MRI images, the gall bladder is a rounded structure with a maximum diameter of less than 4 to 5 cms in distended state. The gall bladder wall thickness ranges from 1 to 3.5 mm.<sup>3</sup>

**Hepatobiliary Diseases in Which MRCP is Useful**

MRCP is useful in following diseases of hepatobiliary apparatus:

**1. Gall Bladder Pathology**

- Congenital Anomalies
- Gallstones
- Acute cholecystitis
- Acalculous cholecystitis
- Chronic cholecystitis
- Xanthogranulomatous cholecystitis
- Benign tumours like papilloma and adenoma.
- Malignant tumours like carcinoma of gall bladder and metastasis.

**2. Biliary tree pathology**

- Choledochal cyst
- Choledocholithiasis
- Benign Stricture
- Bile duct fistula
- Malignant stricture

**METHODS**

The study group consisted of 108 patients diagnosed or suspicious of having hepatobiliary lesions referred for MRI.

**Inclusion Criteria**

Patients of all age groups, presented with complaints of upper abdominal pain, symptoms of obstructive jaundice and signs of hepatobiliary pathology on initial imaging studies such as sonography or CT scan.

**Exclusion Criteria**

Patients with implanted medical devices containing ferro-magnetic objects like cardiac pacemakers, internal defibrillator devices, orthopaedic implants, bone growth stimulators, implanted spinal cord stimulators, intracranial aneurysm clips, ocular implants, ocular magnetic foreign bodies, magnetic dental implants, magnetic sphincters, ferromagnetic IVC filters, coils and stents. Patients in whom only pancreatic duct was affected without involvement of biliary tree were not included in this study.

**MRI Procedures**

MRI examinations were performed by using closed type 1.5 Tesla MR scanner with the study subject in the supine position.

The following sequences were taken in Philips Achieva: A localizer sequence was taken first. (3 axial, 3 sagittal and 3 coronal)

- 1) Axial T2 TSE
- 2) Axial T1 TFE
- 3) Coronal T2 FAT/SAT sense
- 4) SSh\_MRCPRad
- 5) MRCP\_3D\_HR.

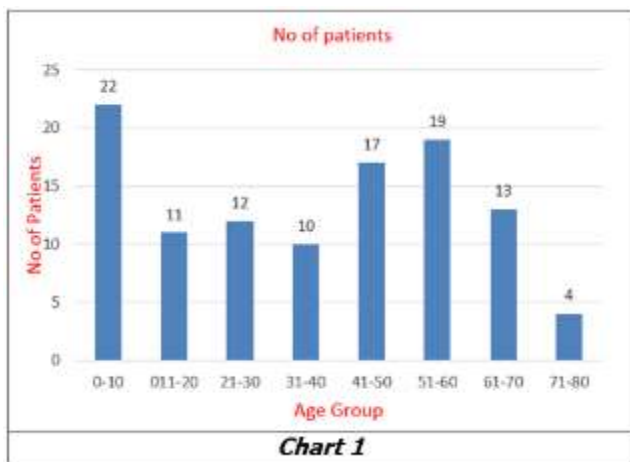
USG was done in 17 patients. CT Abdomen was done in 3 patients. ERCP was done in 7 patients. Histopathological findings were available in 5 patients.

**RESULTS**

The present study included 108 MRCP patients having lesions affecting hepatobiliary system.

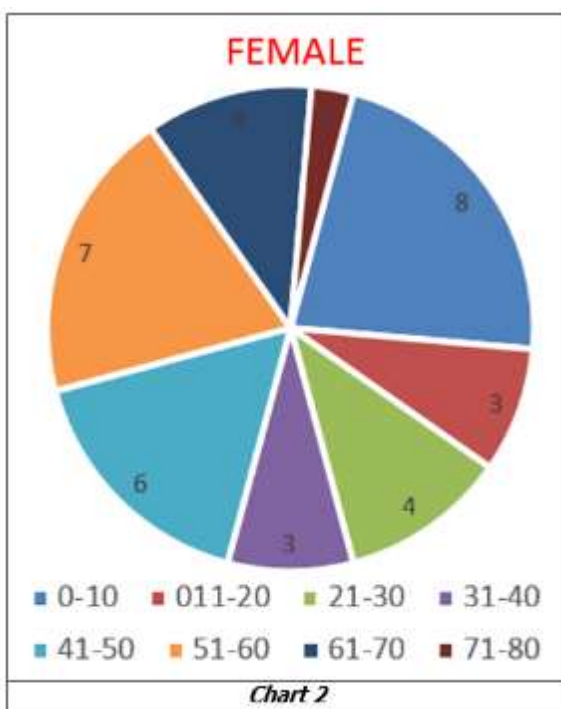
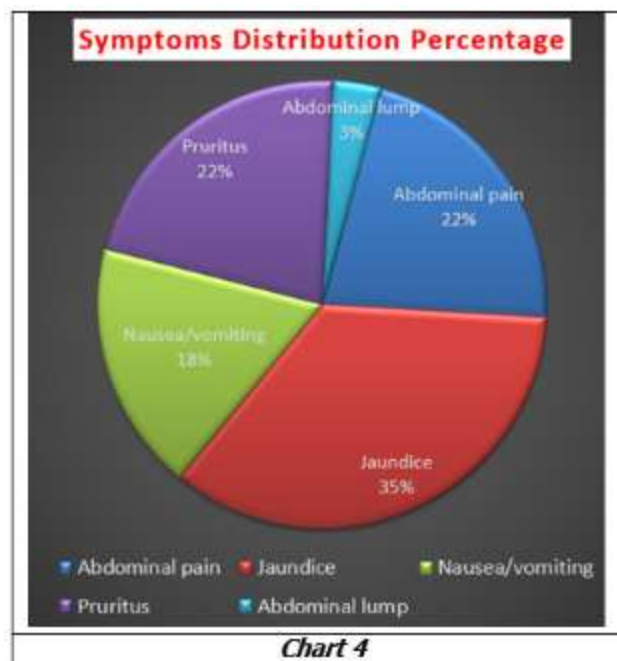
| Age (in Years) | No. of Patients | Percentage | Male | Female |
|----------------|-----------------|------------|------|--------|
| 0-10           | 22              | 20         | 14   | 8      |
| 011-20         | 11              | 10         | 8    | 3      |
| 21-30          | 12              | 11         | 8    | 4      |
| 31-40          | 10              | 9          | 7    | 3      |
| 41-50          | 17              | 16         | 11   | 6      |
| 51-60          | 19              | 18         | 12   | 7      |
| 61-70          | 13              | 12         | 9    | 4      |
| 71-80          | 4               | 4          | 3    | 1      |
| Total          | 108             | 100%       | 72   | 36     |

**Table 1. Age Distribution**



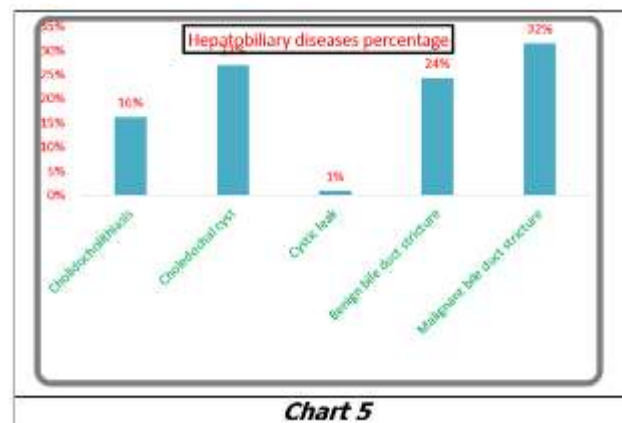
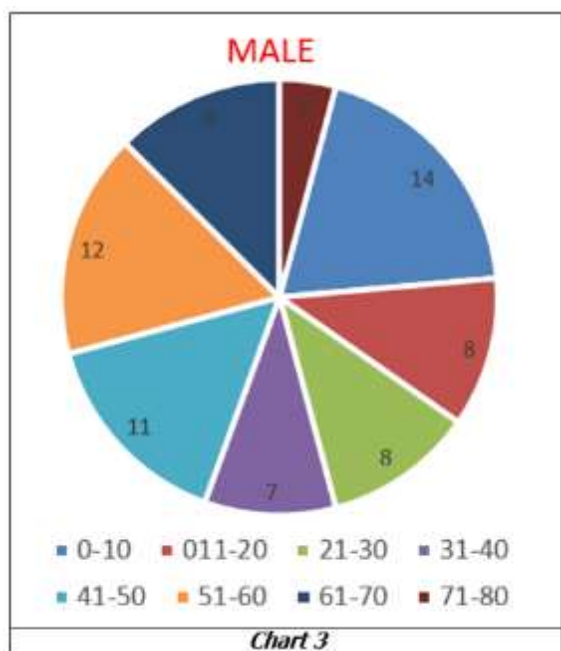
| Symptoms        | Number of Patients | Percentage |
|-----------------|--------------------|------------|
| Abdominal Pain  | 64                 | 22%        |
| Jaundice        | 103                | 35%        |
| Nausea/Vomiting | 53                 | 18%        |
| Pruritus        | 64                 | 22%        |
| Abdominal Lump  | 10                 | 3%         |

**Table 2. Symptoms Distribution**



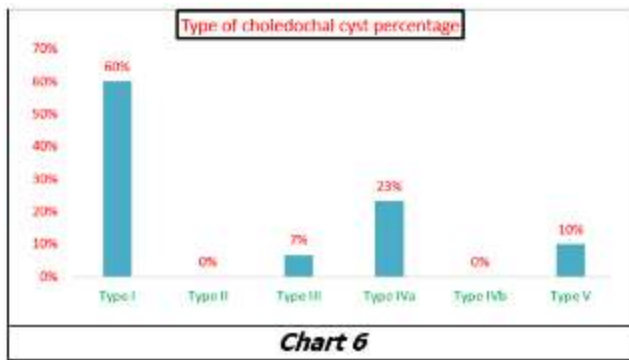
| Hepatobiliary Diseases        | Number of Patients | Percent -age |
|-------------------------------|--------------------|--------------|
| Cholelithiasis                | 18                 | 16%          |
| Cholelith Cyst                | 30                 | 27%          |
| Cystic Leak                   | 1                  | 1%           |
| Benign Bile Duct Stricture    | 27                 | 24%          |
| Malignant Bile Duct Stricture | 35                 | 32%          |
| Total                         | 111                | 100%         |

**Table 3. Spectrum of Hepatobiliary Diseases**



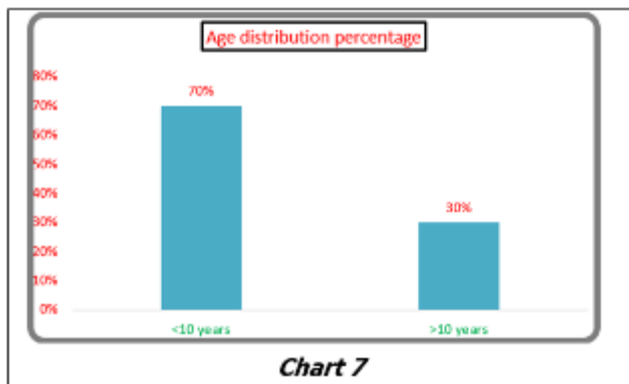
| Type of Choledochal Cyst | Number of Patients | Percent -age |
|--------------------------|--------------------|--------------|
| Type I                   | 18                 | 60%          |
| Type II                  | 0                  | 0%           |
| Type III                 | 2                  | 7%           |
| Type IVa                 | 7                  | 23%          |
| Type IVb                 | 0                  | 0%           |
| Type V                   | 3                  | 10%          |
| Total                    | 30                 | 100%         |

**Table 4. Type of Choledochal Cyst**



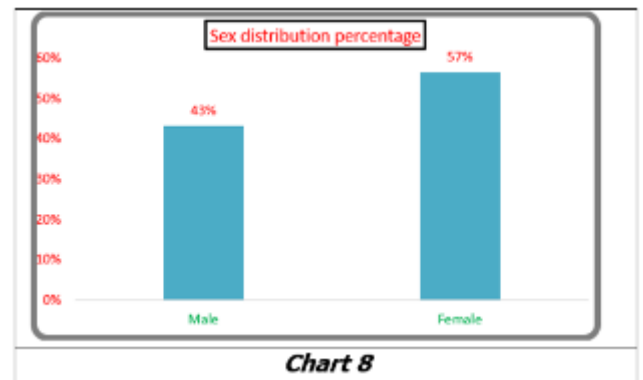
| Age Distribution | Number of Patients | Percentage |
|------------------|--------------------|------------|
| <10 Years        | 21                 | 70%        |
| >10 Years        | 9                  | 30%        |
| Total            | 30                 | 100%       |

**Table 5. Age Distribution in Patients of Choledochal Cyst**



| Sex Distribution | Number of Patients | Percentage |
|------------------|--------------------|------------|
| Male             | 13                 | 43%        |
| Female           | 17                 | 57%        |
| Total            | 30                 | 100%       |

**Table 6. Sex Distribution in Patients of Choledochal Cyst**



| Complications              | Number of Patients | Percent-age |
|----------------------------|--------------------|-------------|
| Gall Bladder Stone         | 2                  | 20%         |
| Common Bile Duct Stone     | 6                  | 60%         |
| Common Bile Duct Stricture | 2                  | 20%         |
| Total                      | 10                 | 100%        |

**Table 7. Complications of Choledochal Cyst**

| Sex Distribution | Number of Patients | Percentage |
|------------------|--------------------|------------|
| Male             | 14                 | 78%        |
| Female           | 4                  | 22%        |
| Total            | 18                 | 100%       |

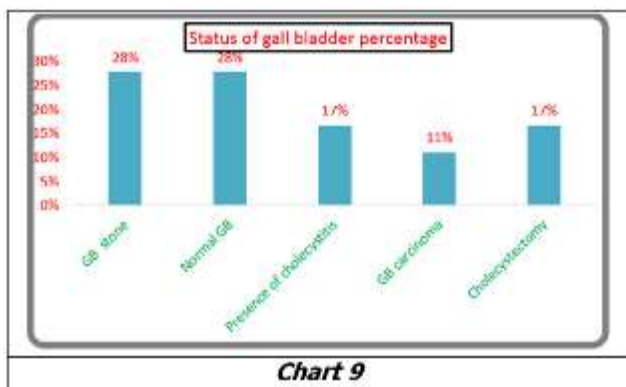
**Table 8. Sex Distribution in Patients of Choledocholithiasis**

| Location           | Number of Patients | Percent -age |
|--------------------|--------------------|--------------|
| Right Hepatic Duct | 1                  | 5%           |
| Left Hepatic Duct  | 1                  | 5%           |
| CHD                | 3                  | 14%          |
| CBD                | 16                 | 76%          |
| Total              | 21                 | 100%         |

**Table 9. Location of Calculi Within Biliary Apparatus in 13 Patients of Choledocholithiasis**

| Status of Gall Bladder    | Number of Patients | Percent -age |
|---------------------------|--------------------|--------------|
| GB Stone                  | 5                  | 28%          |
| Normal GB                 | 5                  | 28%          |
| Presence of Cholecystitis | 3                  | 17%          |
| GB Carcinoma              | 2                  | 11%          |
| Cholecystectomy           | 3                  | 17%          |
| Total                     | 18                 | 100%         |

**Table 10. Status of Gall Bladder in Patients of Choledocholithiasis**



| Aetiology                      | Number of Patients | Percent -age |
|--------------------------------|--------------------|--------------|
| Iatrogenic Bile Duct Injury    | 11                 | 41%          |
| Mirizzi's Syndrome             | 2                  | 7%           |
| AIDS Cholangiopathy            | 1                  | 4%           |
| Primary Sclerosing Cholangitis | 3                  | 11%          |
| Chronic Pancreatitis           | 2                  | 7%           |
| Secondary to Choledochal Cyst  | 2                  | 7%           |
| Indeterminate Cause            | 6                  | 22%          |
| Total                          | 27                 | 100%         |

**Table 11. Aetiology in Patients with Benign Stricture**

| Site of Bile Duct Involvement         | Number of Patients | Percent -age |
|---------------------------------------|--------------------|--------------|
| Right Hepatic Duct                    | 0                  | 0%           |
| Left Hepatic Duct                     | 3                  | 12%          |
| CHD with Confluence of RHD and LHD    | 2                  | 8%           |
| CHD without Confluence of RHD and LHD | 9                  | 35%          |
| Proximal CBD                          | 0                  | 0%           |
| Mid CBD                               | 0                  | 0%           |
| Distal CBD                            | 12                 | 46%          |
| Total                                 | 26                 | 100%         |

**Table 12. Site of Bile Duct Involvement in Benign Stricture**

| Cause                              | Number of Patients | Percent -age |
|------------------------------------|--------------------|--------------|
| Post Cholecystectomy Stricture     | 7                  | 64%          |
| Post Hepatic Jejunostomy Stricture | 2                  | 18%          |
| Post Liver Resection Stricture     | 2                  | 18%          |
| Total                              | 11                 | 100%         |

**Table 13. Causes of Iatrogenic Bile Duct Injury**

| Bismuth Classification of Iatrogenic Bile Duct Stricture | Number of Patients | Percentage |
|--|--------------------|------------|
| Type I   | 2                  | 18%        |
| Type II  | 2                  | 18%        |

|          |    |      |
|----------|----|------|
| Type III | 5  | 45%  |
| Type IV  | 2  | 18%  |
| Type V   | 0  | 0%   |
| Total    | 11 | 100% |

**Table 14. Bismuth Classification of Iatrogenic Bile Duct Stricture**

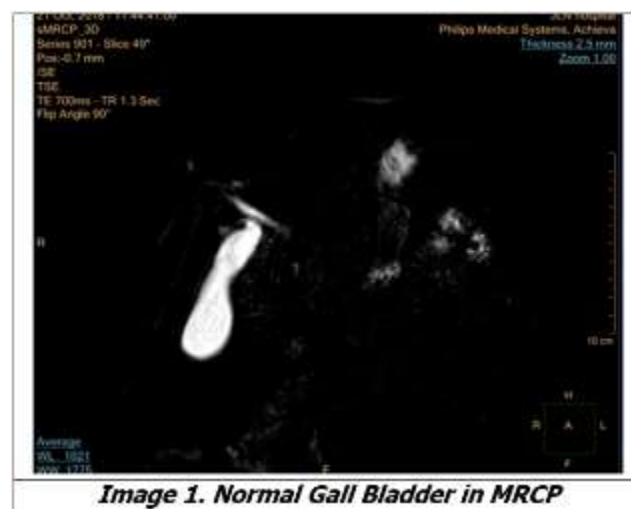| Aetiology                                | Number of Patients | Percent -age |
|--|--------------------|--------------|
| Cholangiocarcinoma                       | 24                 | 69%          |
| Gall Bladder Mass Infiltrating Bile Duct | 3                  | 9%           |
| Pancreatic Mass Infiltrating CBD         | 3                  | 9%           |
| Liver Mass Infiltrating CHD              | 1                  | 3%           |
| Periampullary Mass                       | 4                  | 11%          |
| Total                                    | 35                 | 100%         |

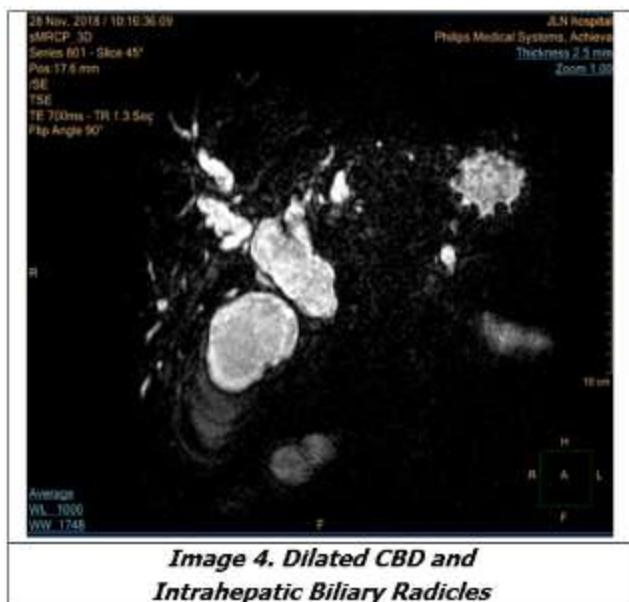
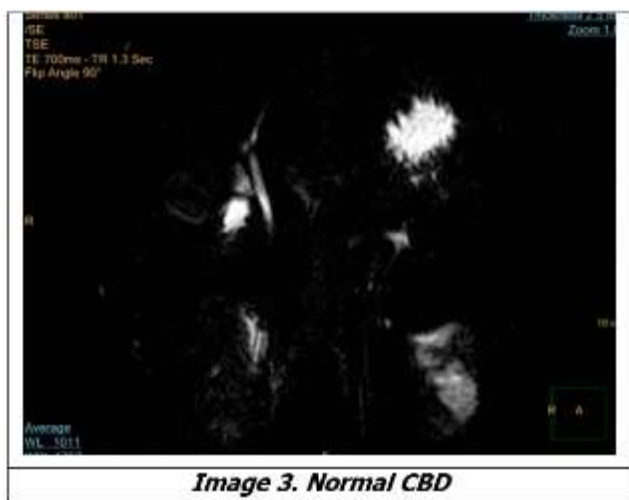
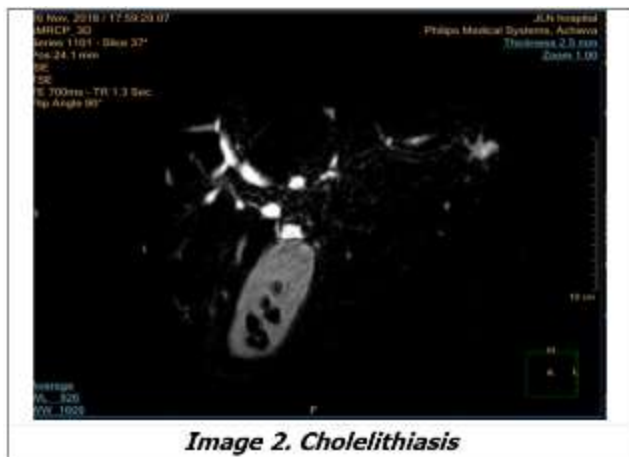**Table 15. Aetiology in Patients with Malignant Stricture**

| Bismuth Classification | Number of Patients | Percent -age |
|------------------------|--------------------|--------------|
| Type I                 | 2                  | 18.1         |
| Type II                | 7                  | 63.3         |
| Type III               | 2                  | 18.1         |
| Type IV                | 0                  | 00           |
| Total                  | 11                 |              |

**Table 16. Bismuth Classification of Hilar Cholangiocarcinoma**

**Representative Images**





## DISCUSSION

### Age and Sex Distribution

In this study most of the patients were between 0-10 years of age group comprising 22 patients (20%) followed by 50-60 years of age group which included 19 patients (18%); 72 were male and 36 were female with male to female ratio of the 2:1.

### Symptoms Distribution

In this study jaundice was the most common symptom present in 103 patients followed by abdominal pain and pruritus which was present in the 64 patients.

### Distribution of Hepatobiliary Apparatus Lesions

Malignant stricture of the bile duct was the most common pathology in this study comprising 35 patients followed by benign strictures comprising 27 patients.

In a study by Adamek H et al<sup>4</sup> malignant stricture of the bile duct was the most common pathology followed by benign stricture of the bile duct.

### Choledochal Cyst

This study included total 30 patients of Choledochal cyst, 18 patients with type 1 Choledochal cyst, 7 patients with type 4A Choledochal cyst, 2 patients with type 3 and 3 patients of type 5 Choledochal cyst (Caroli's disease).

In Irie H et al<sup>5</sup> study most Choledochal cyst were of type 1 followed by type 4 Choledochal cysts.

### Choledocholithiasis

There were total 18 patients of choledocholithiasis in this study. Out of the 18 patients choledocholithiasis was secondary to choledochal cyst in 6 patients. Associated Cholelithiasis was present in 2 patients. History of cholecystectomy was present in 3 Patient. Two patients had associated carcinoma of gall bladder. 3 patients had findings of cholecystitis on T2W images.

Common bile duct was dilated in 10 patients. Two patients had non dilated biliary radicals. 16 patients had calculi within CBD, 2 patients had calculi within CHD and 2 patients had calculi within right and left hepatic ducts. Most of the patients had calculi situated within distal CBD. Multiple calculi were found in all cases.

### Benign Stricture

This study includes total 27 patients of benign stricture. Iatrogenic injury was the most common cause of the bile duct stricture (11) followed by distal CBD stricture associated with chronic pancreatitis in 2 patients.

Smooth, symmetrical and long segment tapered narrowing is the pattern seen most commonly in the patients of the benign stricture.

Distal CBD was the most common site of involvement present in 12 patients followed by CHD involvement present in 9 cases. Confluence of the right and left hepatic duct was involved in 2 cases.

1 case of cholangiocarcinoma was false positively diagnosed as having benign stricture on MRCP. Patient had short segment stricture without shouldering and irregularity in CHD; however, on biopsy report it turned out to be cholangiocarcinoma. Thus, false positive diagnosis of benign stricture was made on MRCP in one patient.

### Iatrogenic Stricture

Out of total 27 patients of benign strictures, iatrogenic biliary stricture was present in 11 patients.

Among iatrogenic strictures cholecystectomy was the most important cause comprising of 7 cases, hepaticojejunostomy was responsible and right lobe hepatectomy comprises two cases each.

In Alfonso R et al<sup>6</sup> study cholecystectomy was the most common cause of the bile duct injury.

### **Primary Sclerosing Cholangitis**

Benign stricture in three patients was due to primary sclerosing cholangitis. Patients had stricture with multifocal areas of the narrowing, intermittent dilatation and tortuosity involving the common hepatic duct, proximal and mid part of common bile duct.

Dusunceli et al<sup>7</sup> concluded in his study that irregularities, multifocal strictures and dilatations in different levels of the biliary channels were seen in all patients of sclerosing cholangitis.

### **Malignant Stricture**

There were total 35 patients of malignant stricture in this study. Most common cause of malignant stricture was cholangiocarcinoma (24 patients). 4 patients of the malignant stricture were due to periampullary mass, 3 due to pancreatic mass infiltrating common bile duct, 3 due to gall bladder mass infiltrating common bile duct, and one due to liver mass infiltrating common hepatic duct. Among 24 cases of the cholangiocarcinoma, hilar cholangiocarcinoma was the most common type (11 patients). Abrupt narrowing was the most common pattern seen in most of the Patients of malignant bile duct stricture on MRCP.

### **Hilar Cholangiocarcinoma**

Among the total 11 cases of hilar cholangiocarcinoma 7 were of Bismuth type 2 which involves only primary confluence, 2 had Bismuth type 3 in which there was involvement of the secondary confluence on right side. MRCP was able to identify proximal and distal extent of the disease in all patients. T2W images also identified liver metastasis in one patient.

Manfredi R et al<sup>8</sup> in his study on hilar cholangiocarcinoma concluded that accuracy of MRCP in assessing the level and the features of bile duct obstruction was comparable to that of direct Cholangiography such as ERCP. However, compared with ERCP, MRCP more accurately determined the supra hilar tumour extension.

### **Pancreatic Mass Infiltrating Common Bile Duct**

2 patients had pancreatic head mass with distal common bile duct infiltration resulting in abrupt cut off of distal common bile duct. Dilated and tortuous main pancreatic duct was present in both of the patients producing 'double duct sign' which is characterized by dilatation of both the common bile duct and main pancreatic duct. Mass lesion was identified in both of the patient involving head of the pancreas which appear hyperintense on T2 weighted images.

Kim MJ et al<sup>9</sup> noted 'double-duct sign' in 13 patients among total 21 patients of pancreatic head mass.

### **Gallbladder Mass Infiltrating Bile Duct**

There were 3 cases of gall bladder mass with resultant infiltration of the bile duct. The patients had mass replacing gall bladder fossa with infiltration of adjacent liver parenchyma. The mass appeared to be hypointense on T1 and hyperintense on T2 weighted images. When we find stricture at primary confluence or upper CHD, small GB mass should be searched for.

### **Periampullary Carcinoma**

All 4 patients of Periampullary carcinoma had 'double duct sign and abrupt cut off the distal CBD. Dilatation of side branches of MPD was not seen in any of the patients.

Kim MJ et al<sup>9</sup> noted 'double-duct sign' in 15 patients among total 29 patients while only the bile duct was dilated in the remaining 14 patients.

### **Distal CBD Cholangiocarcinoma**

There were total 8 patients of the distal CBD cholangiocarcinoma. Intraluminal mass was demonstrated in 2 of 8 cases of distal CBD cholangiocarcinoma and remaining were of the periductal infiltrating type of cholangiocarcinoma. CBD was dilated and MPD was normal in all patients.

Kim MJ et al<sup>9</sup> noted in his study of patients with distal bile duct cancer, 89% had ductal wall thickening with luminal obliteration. 11% had intraductal polypoidal mass without complete obliteration of the lumen. 96% patients had CBD dilatation.

### **Mass Lesion in Right Lobe of Liver Infiltrating Confluence of RHD and LHD**

One patient in this study had mass lesion involving segment V and segment VIII of right lobe of liver. The mass appears to be hypointense on T1W images and hyperintense on T2W images.

### **Bile Leak from Cystic Duct Remnant**

This study included single case of the bile leak from the cystic duct following cholecystectomy. On MRCP sub hepatic collection below the right lobe of the liver was visualised with cystic duct remnant was seen communicating with the above-mentioned collection.

Khalid et al<sup>10</sup> mentioned in his study of that presence of free fluid on the right side of the abdomen, with or without fluid collection adjacent to the injured bile duct, should suggest the diagnosis of bile leak.

### **Advantages of MRCP Over ERCP in This Study**

There were 2 patients of hepaticojejunostomy with operative site stricture in this study. MRCP examination in these patients shows stricture at the site of anastomoses. In these patients ERCP was not possible due to unfavourable anatomy.

In 2 patients of hilar cholangiocarcinoma MRCP shows ductal dilatation proximal to stricture which was not possible on ERCP in these two patients due to tight stricture.

MRCP examined bile duct in physiological state without the problem of the overestimation of the size of the bile ducts.

MRCP does not involve ionising radiation, contrast media and is totally non-invasive.

One of the patients in this study who had undergone ERCP had post ERCP pancreatitis. MRCP as it is totally non-invasive, it is not associated with this complication.

#### **Advantages of ERCP over MRCP**

5 patients of choledocholithiasis in this study had undergone ERCP. In addition to localisation of calculi and determination of bile duct dilatation with ERCP, it was possible to remove calculi. Thus, ERCP provided therapeutic capacity along with its high diagnostic efficacy.

In two patients of periampullary carcinoma ERCP demonstrated infiltration of the duodenal wall which was not visible on MRCP. ERCP also provided tissue sample for diagnosis. Thus, ERCP provides scope for biopsy which is not possible on MRCP.

ERCP can be performed when MRCP is contraindicated. ERCP has better spatial resolution than MRCP.

#### **Advantages of MRCP Over USG in This Study**

2 Patients in this study had calculi in distal common bile duct which was not visualised on USG due to obscuration by gas. One patient of type 1 choledochal cyst had also undergone USG. USG examination failed to identify communication of the cyst with bile duct due to the large size of the cyst. However, the communication was readily visualised on MRCP.

In three patients of gallbladder malignancy, although USG identified gall bladder mass and dilated IHBR, it failed to show infiltration of adjacent liver parenchyma, hilar confluence and common hepatic duct.

In patients with iatrogenic bile duct injury USG was not able to identify exact site of the stricture as compared to MRCP.

#### **Summary**

The objectives of this study were to evaluate hepatobiliary diseases using magnetic resonance cholangiopancreatography features. The MRI Study was undertaken in 108 patients of Jawahar Lal Nehru Medical College and Hospital, Ajmer on patients diagnosed or suspicious of having hepatobiliary lesions referred for MRI. All the MRI scans in this study were performed using 1.5 T MRI scanner (Phillips Medical Systems).

The study comprised 36 females and 72 males. Jaundice was the most common symptom present in 103 patients followed by abdominal pain and pruritus.

Malignant stricture of the bile duct was the most common pathology in this study comprising 35 patients followed by benign strictures comprising 27 patients. This study included total 30 patients of Choledochal cyst, the most common being type 1 Choledochal cyst. There were total 18 patients of choledocholithiasis in this study.

This study includes total 27 patients of benign stricture. Iatrogenic injury was the most common cause of the bile duct stricture in patients of benign biliary Stricture consisting of 11 Patients followed by distal CBD stricture associated with the chronic pancreatitis in 2 patients. Strictures were classified using Bismuth classification. Bismuth type 3 was the most common type in iatrogenic bile duct injury comprising 5 patients.

#### **Advantages of ERCP over MRCP in This Study**

5 patients of choledocholithiasis in this study had undergone ERCP. In addition to localisation of calculi and determination of bile duct dilatation with ERCP, it was possible to remove calculi. Thus, ERCP provided therapeutic capacity along with its high diagnostic efficacy. In two patients of periampullary carcinoma ERCP demonstrated infiltration of the duodenal wall which was not visible on MRCP. ERCP also provided tissue sample for diagnosis. Thus, ERCP provides scope for biopsy which is not possible on MRCP. In two patients of benign distal CBD stricture ERCP provided tissue sample or biopsy and stenting was done in these patients to relieve obstruction, which is not possible with MRCP.

ERCP can be performed when MRCP is contraindicated. ERCP has better spatial resolution than MRCP.

#### **Advantages of MRCP Over USG in This Study**

2 Patients in this study had calculi in distal common bile duct which was not visualized on USG due to obscuration by gas. One patient of type 1 choledochal cyst had also undergone USG. USG examination failed to identify communication of the cyst with bile duct due to the large size of the cyst. However, the communication was readily visualized on MRCP. In three patients of gallbladder malignancy, although USG identified gall bladder mass and dilated IHBR, it failed to show infiltration of adjacent liver parenchyma, hilar confluence and common hepatic duct. In patients with iatrogenic bile duct injury USG was not able to identify exact site of the stricture as compared to MRCP.

#### **CONCLUSION**

In this study of hepatobiliary diseases, on MRCP, malignant stricture was found to be the commonest disease, followed by benign stricture of bile duct and choledochal cysts. MRCP is a non-invasive technique that can diagnose these conditions, underlying predisposing structural abnormality if present, and helps in surgical planning. MRCP is less time consuming than ERCP and can visualise the status of the biliary apparatus proximal to the complete stricture, which is not feasible on ERCP.

However, MRCP cannot be used in patients with MR incompatible pacemakers. It cannot perform biopsy, stenting and removal of CBD calculi which are possible with ERCP. MRCP is a non-invasive tool for diagnosis and can be used for preoperative planning for diseases affecting biliary tree.



**REFERENCES**

- [1] Varghese JC, Farrell M, Courtney G, et al. A prospective comparison of magnetic resonance cholangiopancreatography with endoscopic retrograde cholangiopancreatography in the evaluation of patients with suspected biliary tract disease. *Clin Radiol* 1999;54(8):513-520.
- [2] Schulte SJ, Baron RL, Teefey SA, et al. CT of the extrahepatic bile ducts: wall thickness and contrast enhancement in normal and abnormal ducts. *AJR Am J Roentgenol* 1990;154(1):79-85.
- [3] Smathers RL, Lee JK, Heiken JP. Differentiation of complicated cholecystitis from gallbladder carcinoma by computed tomography. *AJR Am J Roentgenol* 1984;143(2):255-259.
- [4] Adamek HE, Albert J, Weitz M, et al. A prospective evaluation of magnetic resonance cholangiopancreatography in patients with suspected bile duct obstruction. *Gut* 1998;43(5):680-683.
- [5] Irie H, Honda H, Jimi M, et al. Value of MR cholangiopancreatography in evaluating choledochal cysts. *AJR Am J Roentgenol* 1998;171(5):1381-1385.
- [6] Ragozzino A, De Ritis R, Mosca A, et al. Value of MR cholangiography in patients with iatrogenic bile duct injury after cholecystectomy. *AJR Am J Roentgenol* 2004;183(6):1567-1572.
- [7] Dusunceli E, Erden A, Erden I, et al. Primary sclerosing cholangitis: MR cholangiopancreatography and T2-weighted MR imaging findings. *Diagn Interv Radiol* 2005;11(4):213-218.
- [8] Manfredi R, Masselli G, Maresca G, et al. MR imaging and MRCP of hilar cholangiocarcinoma. *Abdom Imaging* 2003;28(3):319-325.
- [9] Kim JH, Kim MJ, Chung JJ, et al. Differential diagnosis of periampullary carcinomas at MR imaging. *Radio Graphic* 2000;22(6):1335-1352.
- [10] Khalid TR, Casillas VJ, Montalvo BM, et al. Using MR cholangiopancreatography to evaluate iatrogenic bile duct injury. *AJR Am J Roentgenol* 2001;177(6):1347-1352.