

ENDOSCOPIC SEPTOPLASTY - OUR EXPERIENCE

Bhennur Durga Prasad¹, Poliseti Ravi Babu², Lanke Soumya³, K. S. B. S Krishna Sasanka⁴

¹Assistant Professor, Department of ENT, Santhiram Medical College & General Hospital, Nandyal, Andhra Pradesh, India.

²Professor, Department of ENT, Santhiram Medical College & General Hospital, Nandyal, Andhra Pradesh, India.

³Senior Resident, Department of ENT, Santhiram Medical College & General Hospital, Nandyal, Andhra Pradesh, India.

⁴Junior Resident, Department of ENT, Santhiram Medical College & General Hospital, Nandyal, Andhra Pradesh, India.

ABSTRACT

INTRODUCTION

Endoscopic septoplasty has almost replaced traditional headlight septoplasty. It is a minimally invasive technique and offers excellent visualisation with minimal dissection. A prospective study was carried out of all the cases that underwent endoscopic septoplasty at Santhiram Medical College and General Hospital, Nandyal, Andhra Pradesh from February 2010 to April 2015. Out of 148 cases of endoscopic septoplasty 35% were having gross spur, 43% were broad based deviations and 12% with more than one type of deviation. Endoscopic septoplasty reduces postoperative complication and oedema arising out of unnecessary flap elevation and dissection in traditional septoplasty. Endoscope helps in better correction of complex deformities like posterior bony deviations. It has become an important teaching tool for the students.

KEYWORDS

Endoscopic Septoplasty, Endoscopic sinus surgery (ESS), Deviated nasal septum, Spur, Septoplasty, Mucoperichondrial flap, Adhesions.

HOW TO CITE THIS ARTICLE: Bhennur Durga Prasad, Poliseti Ravi Babu, Lanke Soumya, K. S. B. S Krishna Sasanka. "Endoscopic Septoplasty - Our Experience". Journal of Evidence based Medicine and Healthcare; Volume 2, Issue 51, November 26, 2015; Page: 8631-8633, DOI: 10.18410/jebmh/2015/1194

INTRODUCTION: Surgery on a deviated nasal septum has changed a lot starting from radical septal resection to mucosal preservation and subsequent preservation of possible septal framework,^[1] as the latter gives rise to lesser complications, allows concomitant rhinoplasty or a revision surgery later. Moreover conservative surgery can be safely performed in children.^[2]

The concept of using an endoscope is important in cases requiring limited septoplasty i.e. those with isolated spurs or ridges and require their removal before Endoscopic sinus surgery (ESS). Endoscope helps to facilitate adequate visualisation and obviates the need of traditional head light approach.

Lanza, et al and Stammberger initially described the application of endoscopic techniques to the correction of septal deformity in as early as in 1991. Lanza, et al described a detailed endoscopic approach to the treatment of isolated spurs.^[3,4] When compared with standard headlight technique endoscopic septoplasty provides important advantages like adequate visualisation and room for Functional endoscopic sinus surgery (FESS) instrumentation. Endoscopic septoplasty is a good method to teach or demonstrate this surgery when compared to headlight Septoplasty where only the operating surgeon has direct vision of the surgical field.

Moreover this limits the unnecessary raising of flaps, and improves magnification and visualisation of surgical field.

We present our experience with endoscopic septoplasty in a series of 148 patients, their surgical indication, technique and results. All the cases were operated by the first author.

MATERIALS AND METHODS: A prospective study of 148 patients was carried out in the ENT Department, Santhiram Medical college and General hospital, Nandyal, Andhra Pradesh, from February 2010 to April 2015. In this study, 148 patients in the age group of 18-50 years of both sex were included. Our exclusion criteria were patients suffering from medical problems such as diabetes, cardiac cases, hypertension and blood dyscrasias, nasal polyposis, history of previous septal and nasal turbinate surgery.

Before operation both the nasal cavities were packed with ribbon gauge soaked in 4% Xylocaine and 1:100000 2% Xylocaine with adrenaline was infiltrated (Figure 1). The author typically uses Freer or Killian's incision on left side irrespective of the side of deviation.

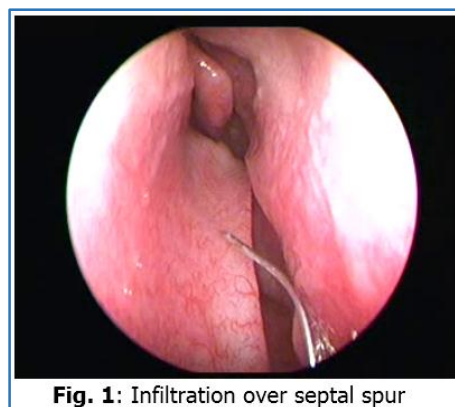

Fig. 1: Infiltration over septal spur

Submission 20-11-2015, Peer Review 21-11-2015

Acceptance 23-11-2015, Published 26-11-2015.

Corresponding Author:

Dr. Bhennur Durga Prasad, Assistant Professor,
Department of ENT, Santhiram Medical College &
General Hospital, Nandyal-518501.

Andhra Pradesh, India.

E-mail: meetdrdurga@gmail.com

DOI: 10.18410/jebmh/2015/1194

In selective cases where spurs were sharp open book method was used.^[5] Under direct visualisation using a 0° endoscope, mucoperichondrial flaps are elevated with suction elevator to expose the deviated portion of the septum (Figure 2).

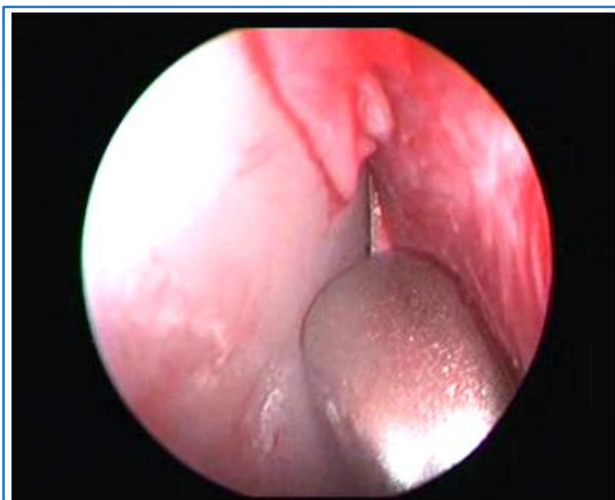

Fig. 2: Mucoperichondrial flap elevation

The septal cartilage is incised a few millimeters away from mucosal incision and the contra lateral mucosal flap is elevated.

Deviated portions of bone from vomer and the perpendicular plate of ethmoid are removed if required (Figure 3). Maxillary crest is chiselled if required.

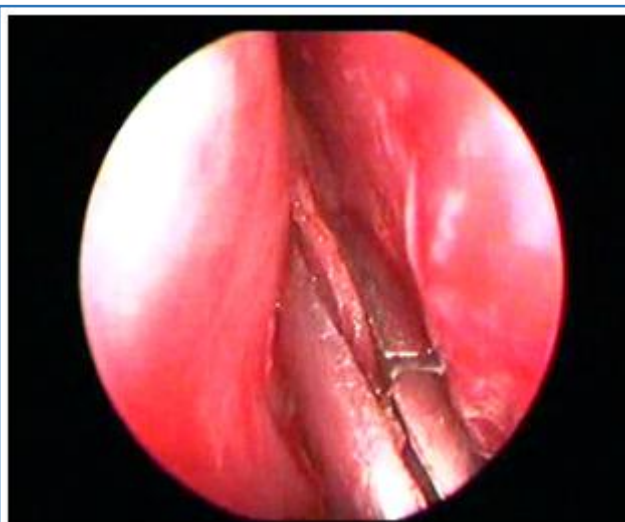

Fig. 3: Deviated portion excised

RESULTS: We reviewed 148 cases of endoscopic septoplasty. 52 (35%) of the cases were having spur. 63 (43%) were broad based deviations and 33 (12%) were having more than one type of septal deviation.

Complication included adhesions in three cases which were subsequently released and successfully treated later. Asymptomatic small septal perforation in the anterior part of septum in one case has been observed.

DISCUSSION: Septoplasty is done to relieve obstruction and provide symptomatic relief to the patient. Septoplasty becomes necessary in FESS for gaining access to the operative site.

The conventional septoplasty is done with headlight illumination and nasal speculum. With conventional approach visualisation is impaired which can lead to mucosal trauma resulting in unnecessary bleeding and post-operative complications like adhesions.

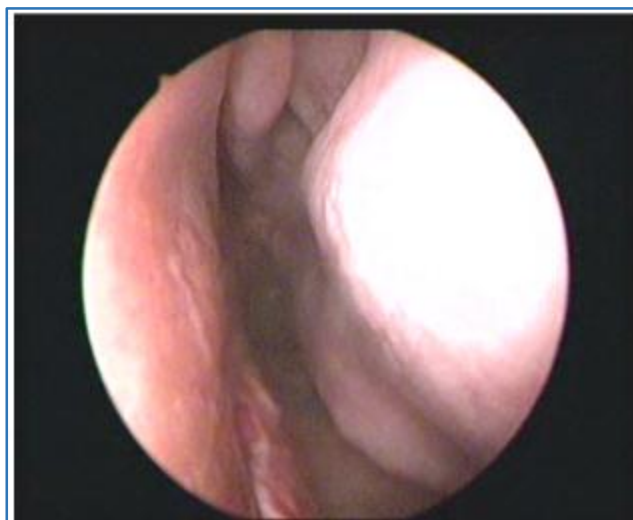


Fig. 4: Postoperative result

Endoscope is very helpful in posterior deviations as it significantly improves the visualisation and dissection of posterior deviations (Figure 4). The incision can be placed just in front of deviation avoiding unnecessary flap elevation and oedema.

Endoscope can be passed easily under the mucosal flap and minimal lifting of flap is required to gain excellent visualisation. Endoscopic septoplasty does not require special instruments as these are same for ESS.

Endoscopic septoplasty is a valuable teaching tool. Learning septoplasty by conventional head light manner is difficult due to limited visualisation. The use of video monitors to demonstrate steps and techniques of mucosal flap elevation offers significant learning opportunities to surgical assistants, trainees and operating-room staff compared to the conventional technique.^[5,6,7]

REFERENCES:

1. Maran AG. Septoplasty, J Laryngol Otol 1974; 88: 393-402.
2. Gupta M, Motwani G. Comparative study of Endoscopic aided Septoplasty and traditional septoplasty in posterior Nasal septal deviations. Indian Journal of Otolaryngol Head neck Surg 2005, 57, 309-11.
3. Lanza DC, Kennedy DW, Zeinreich SJ. Nasal Endoscopy and its surgical application. Essential Otolaryngology; head and neck surgery. 5th ed. New York: Medical Examination; 1991. pp. 373-87.

4. Stammberger H. Functional Endoscopic sinus surgery; the Messerklinger technique. Philadelphia, PA: BC Decker; 1991.
5. Prepageran N, Lingam OR, Endoscopic septoplasty-The Open Book method-Indian J-Otolaryngol Head and Neck Surg. 2010;-62(3); 310-2.
6. Gupta N; Endoscopic septoplasty, Indian J Otolaryngol and Head and Neck Surg 2005; 57, (3): 240-3.
7. Hwang PH. Mc Laughlin RB, Lanza DC, Endoscopic septoplasty; Indications, technique and results. Otolaryngol Head neck Surg. 1999; 120(5): 678-82.